

Isolated cavitory lung disease in a renal allograft recipient: A rare manifestation of cryptococcus

J. S. Sandhu, V. Makkar, P. M. Sohal, A. Singh¹, H. Kaur², J. Sandhu²

Departments of Nephrology, ¹Pulmonary Medicine and ²Pathology, Dayanand Medical College and Hospital, Ludhiana, Punjab, India

ABSTRACT

Although lungs are the portal of entry for cryptococcus, pulmonary disease is relatively uncommon. Cavitory pulmonary disease is even less common. We report a rare case of cryptococcosis with an isolated cavitory lung lesion in a renal allograft recipient.

Key words: Bronchoalveolar lavage, cavitory lung, pulmonary cryptococcus

Introduction

Cryptococcus neoformans is ubiquitous yeast that is commonly found in soil, especially, in association with pigeon droppings.^[1] Infection usually occurs via inhalation of soil aerosols. The clinical manifestations of cryptococcal disease depend on the host. In compromised immune state as in renal transplantation, the most common presentation is disseminated disease, often associated with meningitis. Pulmonary disease is the predominant presentation among immunocompetent hosts.^[2]

Case Report

A 38-year-old male, carpenter by occupation received renal allograft in 2004 for end stage renal disease due to chronic glomerulonephritis. The renal donor was his mother. He was not given induction therapy. He received triple drug immunosuppression that included prednisolone, mycophenolate mofetil, and tacrolimus in therapeutic doses. Mycophenolate mofetil was replaced

with azathioprine after 3 months due to financial constraints. He maintained good graft function.

After 8 years of renal transplantation, he presented with non-pleuritic chest pain on the right side and breathlessness of 2 days duration. There was no history of fever, cough, or hemoptysis.

The examination was essentially, unremarkable except for an area of bronchial breathing over his right mammary region. His hemogram showed hemoglobin of 10.5 g/dL, and normal total and differential leukocyte and platelet counts. Urine examination was normal. The blood urea and serum creatinine were 50 mg/dL and 1.5 mg/dL respectively. The liver function tests were within normal limits. His HBsAg, anti-hepatitis-C virus, anti-human immune deficiency virus, cytomegalovirus IgM antibodies tests were negative. Chest X-ray revealed right mid-zone cavitory lesion with a fluid level [Figure 1]. High resolution computerized tomography showed area of cavitation with nodular density and fibrotic bands suggesting infective pathology.

Bronchoscopy revealed multiple small papillomatous nodules in the tracheobronchial tree. Bronchoalveolar lavage (BAL) was negative for microbial gram stain and culture, nocardia, acid fast bacilli, pneumocystis jiroveci, and malignant cells. Endobronchial biopsy showed pseudostratified ciliated columnar epithelium with squamous metaplasia. Spores of cryptococcus were seen in focal areas in the epithelium. Periodic acid-Schiff stain highlighted the fungus spores [Figure 2]. Although, clinically, there were no signs and symptoms of meningitis, cerebrospinal fluid analysis was done and it was negative for cryptococcal meningitis. He was treated with fluconazole 200 mg twice a day for 6 months and

Address for correspondence:

Dr. J. S. Sandhu, Department of Nephrology, Dayanand Medical College and Hospital, Ludhiana - 141 001, Punjab, India.
E-mail: jsandhu217@gmail.com

Access this article online	
Quick Response Code:	Website: www.indianjnephrol.org
	DOI: 10.4103/0971-4065.116333

the dose of tacrolimus was decreased keeping the blood tacrolimus levels in the therapeutic range and showed clinical and radiological improvement [Figure 3]. Before starting fluconazole, he was receiving tacrolimus 2 mg twice a day that had to be decreased to 0.5 mg twice a day.

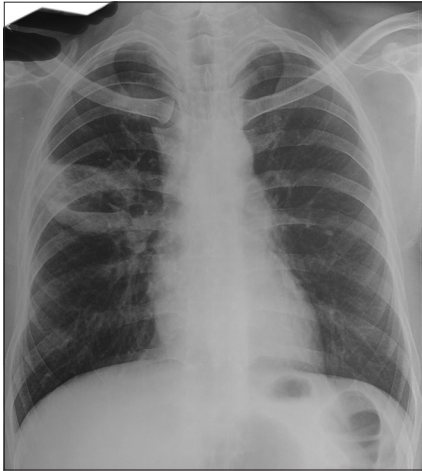

Figure 1: X-ray chest showing right mid zone cavitory lesion

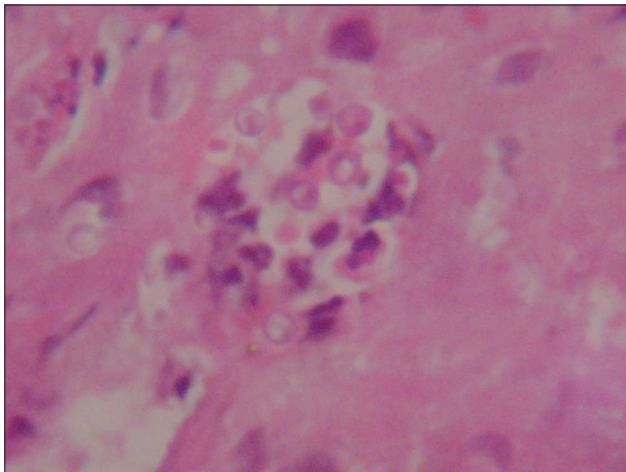


Figure 2: Endobronchial biopsy-spores of cryptococcus in focal areas

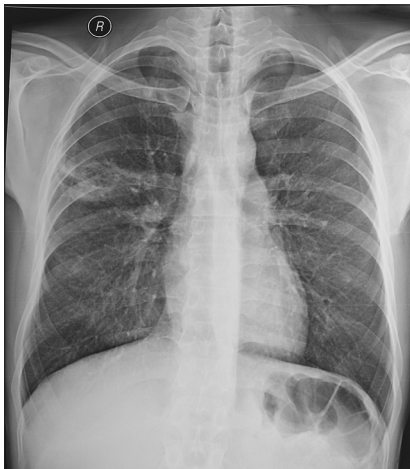

Figure 3: X-ray showing clearing of right cavitory lesion on treatment

Discussion

The clinical manifestations of cryptococcal infection range from asymptomatic colonisation of the respiratory tract to wide-spread dissemination depending on the host immune status. As dissemination occurs, the central nervous system is commonly involved.^[2]

Isolated lung involvement is uncommon in renal allograft recipients and the presentation as cavitary lung lesions is even more uncommon. However, these immune suppressed renal transplant individuals with clinically isolated pulmonary involvement need exclusion of dissemination, especially meningitis by brain imaging studies and CSF examination.^[3]

Bronchoscopic diagnosis may be valuable in cases of isolated lung infection. BAL has been reported to be more sensitive than bronchial brushing in detection of pulmonary disease.^[4] Renal allograft recipients with a lung lesion need more aggressive investigative approach including early bronchoscopy and BAL analysis as has been highlighted in our case. This could even include open lung biopsy in some cases. This helps in avoiding unnecessary exposure to empirical antibiotic therapy.

Cryptococcosis has been documented in an average of 2.8% of solid-organ transplant recipients. The median time for disease onset is 21 months after transplantation.^[3] Patients receiving a calcineurin-inhibitor-based regimen were less likely to have disseminated disease and more likely to have cryptococcus limited to the lungs.^[5,6]

There are no randomized, prospective trials of antifungal treatment of solid organ transplant recipients. Infectious Diseases Society of America in 2010 update^[7] has made explicit recommendations for the management of cryptococcal disease. For meningoencephalitis or disseminated cryptococcus in organ transplant recipients, amphotericin B deoxycholate (0.7-1.0 mg/kg/day intravenously) plus flucytosine (100 mg/kg/day in four divided doses) for 2 weeks is recommended for induction therapy. Lipid formulations of amphotericin B including liposomal (3-4 mg/kg/day) or amphotericin B lipid complex (5 mg/kg/day) could be substituted for amphotericin B and are favored in organ transplant recipients receiving calcineurin inhibitors. This should be followed by a consolidation phase with oral fluconazole (400-800 mg/day) for 8 weeks and finally maintenance phase using fluconazole 200-400 mg/day for 6-12 months.

For mild to moderate pulmonary disease, fluconazole 400 mg (6 mg/kg) per day for 6-12 months is recommended.

Since, fluconazole increases the levels of calcineurin inhibitors, immunosuppressive management should include sequential or step-wise reduction of calcineurin inhibitor, with consideration of lowering the corticosteroid dose first.^[8] Rapid reductions of immunosuppressive can have untoward side effects such as development of graft rejection and/or immune reconstitution inflammatory syndrome.^[9,10]

Routine antifungal prophylaxis for cryptococcosis is not recommended in renal allograft recipients since there are no evidence-based studies to support this and there is no precision in identifying specific high-risk group.^[8]

In conclusion, a rare presentation of cryptococcal infection in a renal allograft recipient is reported and the significance of early bronchoscopy and BAL is highlighted.

References

- Mitchell TG, Perfect JR. Cryptococcosis in the era of AIDS – 100 years after the discovery of *Cryptococcus neoformans*. *Clin Microbiol Rev* 1995;8:515-48.
- Shirley RM, Baddley JW. Cryptococcal lung disease. *Curr Opin Pulm Med* 2009;15:254-60.
- Vilchez RA, Fung J, Kusne S. Cryptococcosis in organ transplant recipients: An overview. *Am J Transplant* 2002;2:575-80.
- Brizendine KD, Baddley JW, Pappas PG. Pulmonary cryptococcosis. *Semin Respir Crit Care Med* 2011;32:727-34.
- Subramanian S, Mathai D. Clinical manifestations and management of cryptococcal infection. *J Postgrad Med* 2005;51:S21-6.
- Singh N, Alexander BD, Lortholary O, Dromer F, Gupta KL, John GT, *et al.* *Cryptococcus neoformans* in organ transplant recipients: Impact of calcineurin-inhibitor agents on mortality. *J Infect Dis* 2007;195:756-64.
- Perfect JR, Dismukes WE, Dromer F, Goldman DL, Graybill JR, Hamill RJ, *et al.* Clinical practice guidelines for the management of cryptococcal disease: 2010 update by the infectious diseases society of America. *Clin Infect Dis* 2010;50:291-322.
- Singh N, Dromer F, Perfect JR, Lortholary O. Cryptococcosis in solid organ transplant recipients: Current state of the science. *Clin Infect Dis* 2008;47:1321-7.
- Lanternier F, Chandesris MO, Poirée S, Bougnoux ME, Mechai F, Mamzer-Bruneel MF, *et al.* Cellulitis revealing a cryptococcosis-related immune reconstitution inflammatory syndrome in a renal allograft recipient. *Am J Transplant* 2007;7:2826-8.
- Singh N, Lortholary O, Alexander BD, Gupta KL, John GT, Pursell K, *et al.* Allograft loss in renal transplant recipients with *Cryptococcus neoformans* associated immune reconstitution syndrome. *Transplantation* 2005;80:1131-3.

How to cite this article: Sandhu JS, Makkar V, Sohal PM, Singh A, Kaur H, Sandhu J. Isolated cavitary lung disease in a renal allograft recipient: A rare manifestation of cryptococcus. *Indian J Nephrol* 2013;23:381-3.

Source of Support: Nil, **Conflict of Interest:** None declared.