



## Delayed Malposition of a Split-Tip Tunneled Cuffed Hemodialysis Catheter

A 66-year-old male with diabetes, hypertension, and chronic kidney disease was initiated on hemodialysis (HD) via a right internal jugular vein (IJV) tunneled cuffed hemodialysis catheter (TCHC) in 2018. In August 2021, he presented with suboptimal blood flows during his prior two dialysis sessions and with partial extrusion of the TCHC. The TCHC cuff, as well as some part of the stem, was out.

A chest X-ray revealed malposition of the catheter, with one tip going down in the superior vena cava [SVC] and the other going up probably in the right IJV [Figure 1a]. A previous chest CT scan done 3 months ago for pneumonia was reviewed. It showed a normally placed right-sided TCHC with both its tips in right atria [Figure 1b].

Fluoroscopy revealed one tip had folded onto itself, retrograde to the blood flow, going into the right IJV and the other tip was in SVC [Figure 1c and 1d]. Dye injected through the venous port was seen exiting freely from the tip in SVC without any filling defect [Figure 2a]. Dye injected via the arterial port exited from the misplaced tip in right IJV with filling defects [Figure 2b].

This TCHC was gently pulled out under fluoroscopic vision without much resistance. Despite continuous negative

pressure aspiration during TCC removal, a remnant of thrombus was seen left behind in the right IJV [Figure 2c]. A new 23-cm right IJV TCHC was inserted. The procedure was uneventful, and good flows were documented in both lumens. Dialysis was performed without any complications and the patient was discharged on the same day.

Delayed mechanical complications of TCC insertion are fibrin sheath formation, catheter occlusion, catheter impingement or fragmentation, damage to the port chamber, and malposition.<sup>1</sup> Symmetrical tip and step-tip catheters have a lesser risk of malposition than split tip catheters.<sup>1</sup>

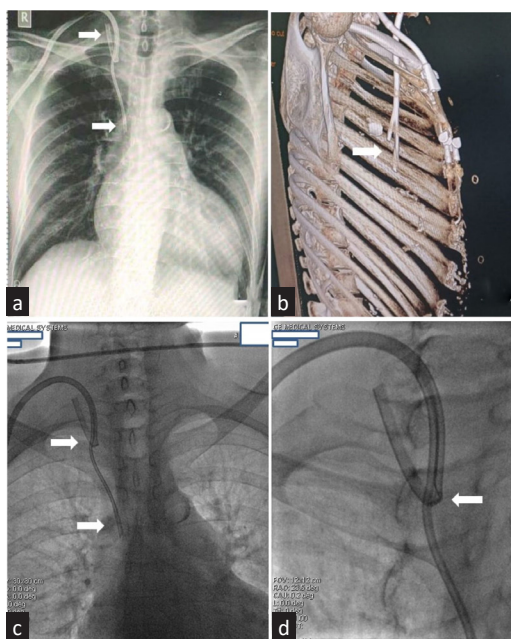
It has been stipulated that the arterial lumen is more prone to malposition during insertion due to lack of guidewire guidance.<sup>2</sup> In our case, there is a delayed malposition, which leads to the possibility of occlusion of the arterial lumen by a thrombus, leading to the malposition.

### Declaration of patient consent

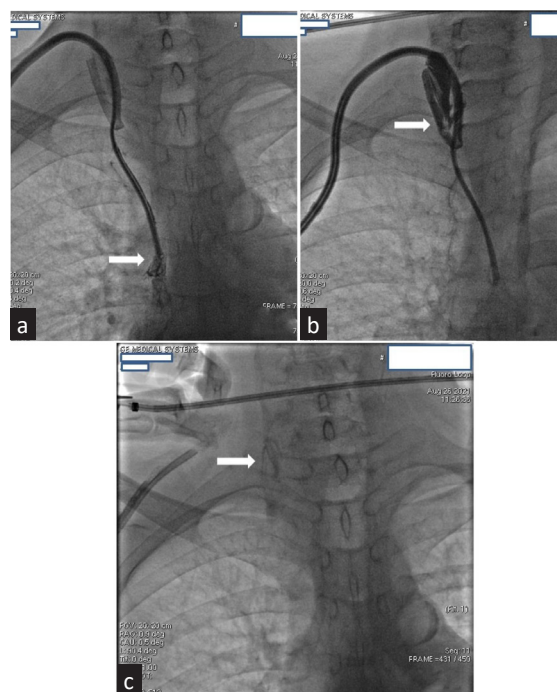
The authors certify that they have obtained all appropriate patient consent.

### Conflicts of interest

There are no conflicts of interest.



**Figure 1:** (a) Shows a chest x-ray with a malpositioned catheter, with one tip in the superior vena cava (SVC) and the other tip in the right IJV (white arrows). (b) Shows a CT reconstructed lateral image of the chest with a normally placed right-sided TCHC with both its tips in right atria (white arrow). (c) Shows a malpositioned TCHC with one tip in the right IJV and the other tip in SVC (white arrows). (d) White arrow shows a TCHC with one tip folded onto itself (white arrow). TCHC: Tunneled cuffed hemodialysis catheter, IJV: Internal jugular vein.



**Figure 2:** (a) Shows dye injected through the venous port of the TCHC exits from the tip in SVC without any filling defect (white arrow). (b) Shows dye injected via the arterial port exits from the misplaced tip in right IJV with filling defects (white arrow). (c) White arrow shows a remnant thrombus in the right IJV. TCHC: Tunneled cuffed hemodialysis catheter, IJV: Internal jugular vein, SVC: Superior vena cava.

## Zaheer Amin Virani<sup>1</sup>, Saumya Vishnoi<sup>1</sup>, Krishnapriya Vadlapatla<sup>1</sup>, Vignesh Ravi Yeleshwaram<sup>1</sup>

<sup>1</sup>Institute of Renal Sciences, Gleneagles Global Hospital, Mumbai, Maharashtra, India

### Corresponding author:

Zaheer Amin Virani, Institute of Renal Sciences, Gleneagles Global Hospital, Mumbai, Maharashtra, India. E-mail: zarockin@yahoo.com

## References

1. Machat S, Eisenhuber E, Pfarl G, Stübler J, Koelblinger C, Zacherl J, et al. Complications of central venous port systems: A pictorial review. *Insights Imaging* 2019;10:86.
2. Wang K, Wang P, Liang X, Lu X, Liu Z. Epidemiology of haemodialysis catheter complications: A survey of 865 dialysis

patients from 14 haemodialysis centres in Henan province in China. *BMJ Open* 2015;5:e007136

This is an open access journal, and articles are distributed under the terms of the Creative Commons Attribution-NonCommercial-ShareAlike 4.0 License, which allows others to remix, transform, and build upon the work non-commercially, as long as appropriate credit is given and the new creations are licensed under the identical terms.

**How to cite this article:** Virani ZA, Vishnoi S, Vadlapatla K, Yeleshwaram VR. Delayed Malposition of a Split-Tip Tunneled Cuffed Hemodialysis Catheter. *Indian J Nephrol.* 2024;34:670-1. doi: 10.25259/IJN\_52\_2024

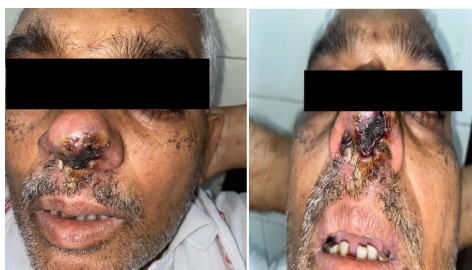**Received:** 02-02-2024; **Accepted:** 13-02-2024;  
**Online First:** 17-06-2024; **Published:** 28-10-2024

**DOI:** 10.25259/IJN\_52\_2024



## Acute Kidney Injury Secondary to Leukemic Infiltration of the Kidneys in M3 Acute Myeloid Leukemia

A 60-year-old male presented with painless necrotic lesion over the tip of nose [Figure 1]. There was grade 1 pedal edema and submandibular lymphadenopathy. At admission, the serum creatinine was 5.96 mg/dl. He was found to have raised blood sugar, raising suspicions of mucormycosis. Fungal potassium hydroxide (KOH) mount of scrapings from the lesion was negative and had acute inflammatory exudate without granulomas. There were no active urine sediments or hypertension. Autoimmune vasculitis and myeloma workup were negative. Bedside ultrasonography showed bilateral bulky kidneys without hydronephrosis or renal mass. A complete blood count revealed a total leucocyte count of  $40.6 \times 10^3/\mu\text{L}$ . Workup for infiltrative disorders was sent, and a kidney biopsy was done given unexplained acute kidney injury (AKI). Peripheral blood smear had 18% blast and blast-like cells raising a possibility of acute leukemia.



**Figure 1:** Necrotic lesion measuring  $1.5 \times 1$  cm on nasal tip over columella extending to left nasal ala, septum, and bilateral vestibule. Overlying skin was erythematous and showed crusting. It was nontender and had no pus discharge or bleeding. Fungal potassium hydroxide (KOH) mount was negative for mucormycosis and was suggestive of acute inflammatory exudate without any granuloma formation.

In the setting of hematological malignancy with AKI, different mechanisms, including tumor lysis syndrome, uric acid nephropathy, obstruction, hypoperfusion, acute tubular necrosis, sepsis, renal vein thrombosis, and direct renal infiltration, were thought of.

Flow cytometry was suggestive of acute promyelocytic leukemia M3 as per French–American–British (FAB) Class. The patient worsened within 48 hours of admission and succumbed to leukostasis. Kidney biopsy showed renal cortex with heavy infiltration of atypical cells within the interstitium and peritubular capillaries [Figure 2a]. These cells showed positive immunoperoxidase staining with myeloperoxidase (MPO) [Figure 2b]. The cause of AKI was thus attributed to renal infiltration from leukemia.

Direct renal infiltration of malignant cells causes AKI in only 1% of leukemia cases.<sup>1</sup> Our patient describes a rare presentation of APML with renal infiltration that mimicked sepsis-induced AKI initially. The kidney is the most common extra-hematopoietic and extrareticular organ to be infiltrated by atypical cells.<sup>2</sup> Propensity to infiltrate increases with the staging and grading of malignancy. Thirty-three percent patients of AML had infiltration in an autopsy series of 1200 patients.<sup>3</sup> Metastatic malignancies can cause cutaneous lesions on the nose as in the index case that resemble a clown's nose described earlier in case of acute leukemia.<sup>4</sup> Because the differential of AKI is broad, kidney biopsy is needed for early diagnosis and special stains can ascertain subtypes of leukemia. Like in our case, atypical cells have strong positivity for MPO.

### Declaration of patient consent

The authors certify that they have obtained all appropriate patient consent.

### Conflicts of interest

There are no conflicts of interest.