

## Gemcitabine-Induced Renal Thrombotic Microangiopathy

Dear Editor,

A 49-year-old gentleman was admitted with complaints of shortness of breath and anasarca for 5 days duration. The patient was diagnosed with advanced pancreatic cancer with liver metastasis 4 month back and was started on gemcitabine in a dose of 1400 mg (on days 1, 8, and 15 of a 28-day cycle) with paclitaxel in a dose of 180 mg (on days 1, 8, and 15 of a 28-day cycle). He had received a cumulative dose of 21,000 mg of gemcitabine over a period of 4 months, with the last cycle administered 1 week before admission. Before starting chemotherapy and 2 weeks before admission, the patient had stable kidney function with a serum creatinine of 0.7 mg/dl. On examination, the patient had a blood pressure of 160/90 mmHg with bilateral pitting pedal edema and pallor. Laboratory evaluation revealed anemia with hemoglobin 8 g/dl, total leukocyte counts  $7 \times 10^9/l$ , platelet count  $235 \times 10^9/l$ , lactate dehydrogenase 350 IU/l, serum albumin 3.5 g/dl, and serum creatinine 4.2 mg/dl. Peripheral blood film did not show any schistocytes. Serum haptoglobin and serum C3 and C4 levels were normal. Urinalysis revealed albumin of 2+ dipstick with no active sediments/casts with a 24-h urine protein excretion of 600 mg/day. A positron emission tomography (PET) imaging at the fourth month showed a favourable response to chemotherapy with almost 50% resolution/decrease in size of liver lesions [Figure 1a]. Echocardiography revealed normal ejection fraction of 45%–50%. A kidney biopsy was performed, which showed features of severe acute tubular injury with vacuolation along with global thickening of glomerular basement membranes. Arterioles showed endothelial swelling with luminal occlusion. All these features favoured a diagnosis of glomerular and vascular thrombotic microangiopathy (TMA) [Figure 1b and c] Immunofluorescence was negative for immunoglobulins

and complements. Due to financial constraints, *ADAMTS13* and genetic testing for complement mutations could not be performed. Gemcitabine-induced renal limited TMA was considered and the drug was discontinued. The patient was managed with diuretics and antihypertensives. His serum creatinine gradually increased to 6.5 mg/dl two months post-discharge, and he was initiated on hemodialysis.

With the rising numbers of malignancies worldwide, increasing number of patients are treated with gemcitabine. Gemcitabine-induced TMA (GiTMA) is likely due to drug-related direct endothelial damage with activation of clotting system.<sup>[1]</sup> Risk factors include gemcitabine cumulative dose more than 20,000 mg/m<sup>2</sup>, prolonged duration of therapy, and advanced cancer. GiTMA usually presents with dyspnea due to noncardiogenic pulmonary edema, new-onset hypertension, and renal dysfunction with significant proteinuria.<sup>[2]</sup> New-onset hypertension and exacerbation of known hypertension are the key signs of GiTMA that can appear long before hemolysis, thrombocytopenia, and AKI. Severe endothelial cell dysfunction during the acute phase of glomerular TMA can lead to podocyte loss resulting in nephrotic range proteinuria. Treatment includes cessation of gemcitabine, antihypertensives, and dialysis support, if needed. Plasmapheresis has a limited role in GiTMA.<sup>[3,4]</sup> A large French retrospective cohort of 120 patients of GiTMA showed that patients who were treated with plasma exchange (PE) displayed comparable rates of remission with more adverse events than patients who did not receive PE.<sup>[5]</sup> Eculizumab (anti-complement component 5 monoclonal antibody) has also been tried in the management of GiTMA and it showed significant improvement in renal function. Red blood cell (RBC) and platelet transfusions exacerbate TMA and should be avoided. GiTMA has a poor prognosis with almost half of

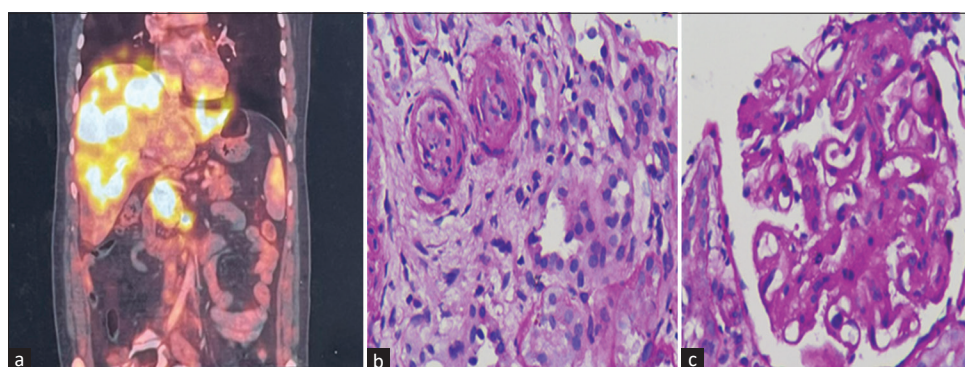


Figure 1: (a) PET image showing hypermetabolic soft tissue density mass lesion in the pancreas and multiple hyperdense lesions in both lobes of liver, suggestive of metastatic disease. (b) Renal biopsy depicting two arterioles with marked luminal narrowing and the presence of fragmented RBCs and neutrophils in their wall, indicating endothelial injury (200x, periodic acid Schiff). (c) Glomerulus in the same biopsy showing microangiopathic changes in the form of thickened capillary wall with double contouring (400x, periodic acid Schiff). PET = positron emission tomography, RBCs = red blood cells

the patients progressing to end-stage kidney disease, with a high mortality rate (40%–90%).<sup>[4]</sup> In future, blockade of the terminal complement cascade has the potential to significantly advance the treatment of drug-induced TMA. The periodic screening for hypertension, edema, urine examination and serum creatinine in patients treated with gemcitabine could allow earlier detection of GiTMA.

### Declaration of patient consent

The authors certify that they have obtained all appropriate patient consent forms. In the form, the patient(s) has/have given his/her/their consent for his/her/their images and other clinical information to be reported in the journal.

### Financial support and sponsorship

Nil.

### Conflicts of interest

There are no conflicts of interest.

**Ankur Chaudhary, Jasmine Sethi, Sahil Garg,  
Aravind Sekar<sup>1</sup>, Harbir Singh Kohli**

*Departments of Nephrology and <sup>1</sup>Histopathology, Post Graduate Institute of Medical Education and Research, Chandigarh, India*

#### Address for correspondence:

*Dr. Jasmine Sethi,  
Nephrology, Post Graduate Institute of Medical Education and Research  
Chandigarh, Chandigarh, India.  
E-mail: jasmine227021@gmail.com*

### References

1. Daviet F, Rouby F, Poullin P. Thrombotic microangiopathy associated with gemcitabine use: Presentation and outcome in a national French retrospective cohort. *Br J Clin Pharmacol* 2019;85:403-12.
2. Katagiri D, Hinoshita F. Gemcitabine-induced thrombotic microangiopathy with nephrotic syndrome. *CEN Case Rep* 2018;7:217-20.
3. Krishnappa V, Gupta M, Shah H. The use of eculizumab in gemcitabine induced thrombotic microangiopathy. *BMC Nephrol* 2018;19:9.
4. Efe O, Goyal L, Galway A, Zhu AX, Niles JL. Treatment of gemcitabine-induced thrombotic microangiopathy followed by gemcitabine rechallenge with eculizumab. *Kidney Int Rep* 2021;6:1464-8.
5. Daviet F, Rouby F, Poullin P, Moussi-Frances J, Sallee M. Thrombotic microangiopathy associated with gemcitabine use: Presentation and outcome in a national French retrospective cohort. *Br J Clin Pharmacol* 2019;85:403-12.

This is an open access journal, and articles are distributed under the terms of the Creative Commons Attribution-NonCommercial-ShareAlike 4.0 License, which allows others to remix, tweak, and build upon the work non-commercially, as long as appropriate credit is given and the new creations are licensed under the identical terms.

Access this article online	
<b>Quick Response Code:</b> 	<b>Website:</b> <a href="https://journals.lww.com/ijon">https://journals.lww.com/ijon</a>
	<b>DOI:</b> 10.4103/ijon.ijn_321_22

**How to cite this article:** Chaudhary A, Sethi J, Garg S, Sekar A, Kohli HS. Gemcitabine-induced renal thrombotic microangiopathy. *Indian J Nephrol* 2023;33:319-20.

**Received:** 27-09-2022, **Accepted:** 19-10-2022, **Published:** 08-03-2023

© 2023 Indian Journal of Nephrology | Published by Wolters Kluwer - Medknow