Continuous Glucose Monitoring in a Renal Transplant Setting

Dear Editor,

A 31-year-old female with type 2 diabetes mellitus underwent kidney transplant surgery. Immediately post-operation, a continuous glucose sensor (Abbott, freestyle libre) was placed over the right deltoid region. The reader, a small mobile-phone-like device provided with the sensor was used to measure blood glucose levels. Glucose values were obtained by placing the reader over the sensor. We measured glucose levels hourly for the initial two days, and continuous insulin infusion (Human Actrapid) was administered for glycemic control. Subsequently, glucose levels were monitored every 4 hours, and as per requirement, a long- acting insulin preparation, Solo-star was administered at night. Human actrapid was also given thrice daily before meals as bolus dose, as per requirement. Her postoperative period was uneventful, and she was discharged with a serum creatinine of 0.8 mg/dL. Post-discharge continuous glucose monitoring (CGM) was not required, as her glycemic control had improved.

CGM is a great innovation, especially for those with erratic and fluctuating insulin requirements.[1] It uses its subcutaneous sensors to estimate interstitial fluid glucose levels (usually every 5 minutes) throughout the day and wirelessly transmits the measured real-time data to the reader. This avoids the hassle of finger pricks. Two types are available: intermittently scanned CGM and real-time CGM (rt-CGM). We used the rt-CGM apparatus, which provided data including the time-in-target range, glycemic variability, and glucose management indicator [Figure 1]. The cost of CGM was the same as that of finger-test glucose monitoring.

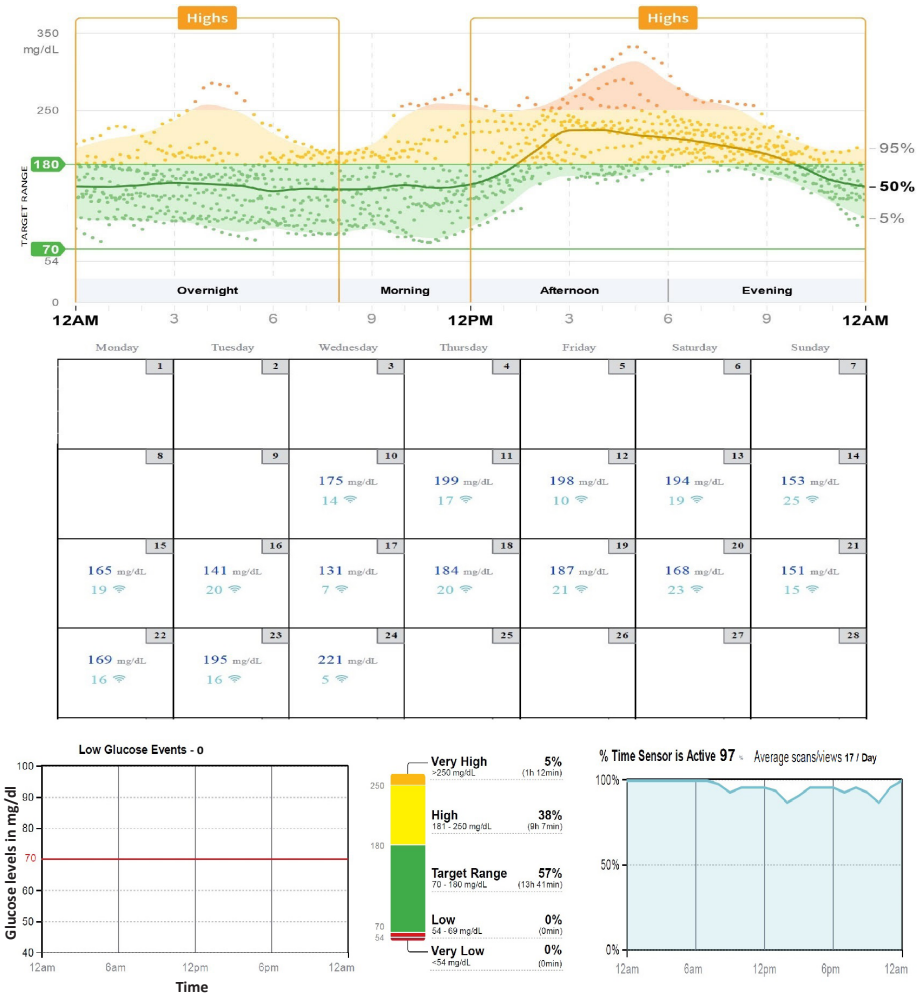

Figure 1: Glycemic metrics of the patient. The colour codes indicate the degree of glucose control. Green indicates good control and red indicates suboptimal control. Mean glucose levels. The symbol indicates that the device was active and measurement was done for specified number of times. Blue color indicates the time period when sensor was active.

Clinical practice recommendations on glycemic control in renal transplant settings are currently unavailable.[2,3] Jandovitz *et al.* conducted a randomized control trial comparing finger-test glucose monitoring with CGM for 40 diabetic patients with ESRD undergoing renal transplantation. Clinical outcomes were better in the CGM group.[4]

Conflicts of interest: There are no conflicts of interest.

Asokan Arunkumar[1], Varadharajan Jayaprakash[1], Tanuj Moses Lamech[1], J S Kumar[2]

Departments of [1]Nephrology and [2]General Medicine, SRM Medical College and Research Centre, SRMIST, Kattankulathur, Tamil Nadu, India

Corresponding author: *Varadharajan Jayaprakash, Department of Nephrology, SRM Medical College and Research Centre, SRMIST, Kattankulathur, Tamil Nadu, India. E-mail: jayaprakash2k@gmail.com*

References

1. Zhang XM, Shen QQ. Application and management of continuous glucose monitoring in diabetic kidney disease. World J Diabetes 2024;15:591-7.
2. Kidney Disease: Improving Global Outcomes (KDIGO) Diabetes Work Group. KDIGO 2022 Clinical practice guideline for diabetes management in chronic kidney disease. Kidney Int 2022;102:S1-S127.
3. Chadban SJ, Ahn C, Axelrod DA, Foster BJ, Kasiske BL, Kher V, *et al*. KDIGO Clinical practice guideline on the evaluation and management of candidates for kidney transplantation. Transplantation 2020;104:S11-S103.
4. Jandovitz N, George SJ, Abate M, Kressel AM, Bolognese AC, Lau L, *et al*. A randomized trial of continuous glucose monitoring to improve post-transplant glycemic control. Clin Transplant 2023;37:e15139.

This is an open access journal, and articles are distributed under the terms of the Creative Commons Attribution-NonCommercial-ShareAlike 4.0 License, which allows others to remix, transform, and build upon the work non-commercially, as long as appropriate credit is given and the new creations are licensed under the identical terms.

How to cite this article: Arunkumar A, Jayaprakash V, Lamech TM, Kumar JS. Continuous Glucose Monitoring in a Renal Transplant Setting. Indian J Nephrol. doi: 10.25259/IJN_732_2024

Received: 25-11-2024; **Accepted:** 09-01-2025; **Online First:** 06-03-2025; **Published:** ***

DOI: 10.25259/IJN_732_2024