

Declaration of patient consent

The authors certify that they have obtained all appropriate patient consent.

Conflicts of interest

There are no conflicts of interest.

**Satish Kumar¹, Santosh Kumar Singh²,
Rahil Arora², Ahmed Waheed Kashif³**

¹Department of Internal Medicine, Military Hospital, Yol Cantt, Yol, Departments of ²Internal Medicine and ³Pathology, Armed Forces Medical College, Wanowrie, Pune, India.

Corresponding author:

Rahil Arora, Department of Internal Medicine, Armed Forces Medical College, Wanowrie, Pune, India. E-mail: rahilarora1992@gmail.com

Reference

1. Couser WG. Primary membranous nephropathy. Clin J Am Soc Nephrol 2017;12:983–97.

This is an open access journal, and articles are distributed under the terms of the Creative Commons Attribution-NonCommercial-ShareAlike 4.0 License, which allows others to remix, tweak, and build upon the work non-commercially, as long as appropriate credit is given and the new creations are licensed under the identical terms.

How to cite this article: Kumar S, Singh SK, Arora R, Kashif AW. Membranous Nephropathy in a Treatment Naive Patient of Rheumatoid Arthritis. Indian J Nephrol. 2024;34:543-4. doi: 10.25259/IJN_40_2024

Received: 24-01-2024; Accepted: 02-03-2024;
Online First: 04-06-2024; Published: 30-08-2024
DOI: 10.25259/IJN_40_2024



Collagenofibrotic Glomerulopathy—An Unexpected Finding in a Young Female

Dear Editor,

Collagenofibrotic glomerulopathy (CG) is a rare kidney disease, seldom suspected clinically. A 31-year-old lady was referred for the evaluation of hypertension and proteinuria, which she had developed in the third trimester of her second pregnancy and persisted for eight months postdelivery. Her first pregnancy was uneventful. Appropriate patient consent was taken.

On evaluation, she had proteinuria without haematuria or pyuria. The urine protein creatinine ratio was 2.52, serum creatinine was 0.57 mg/dl, and her kidneys looked normal on ultrasound examination. Serological examination for HIV, HBV, and HCV were negative. Evaluation for connective tissue disorders was not contributory. Hence, a kidney

biopsy was performed with a spring-loaded gun under real-time ultrasound guidance for a definitive diagnosis.

On light microscopy, all the sampled glomeruli were viable, enlarged with diffuse mesangial widening which stained weakly positive by PAS, pale blue on Masson stain, and was negative with Jones silver methenamine stain. No immune deposits on immunofluorescence. The first impression was that of non-light chain amyloid, yet Congo red was negative [Figure 1]. Electron microscopy revealed haphazardly arranged curvilinear frayed bundles of banded collagen showing distinct periodicity and a diameter of 29.15 nm present in the subendothelial region and the mesangium, suggesting collagen fibrils and Type III collagen was confirmed

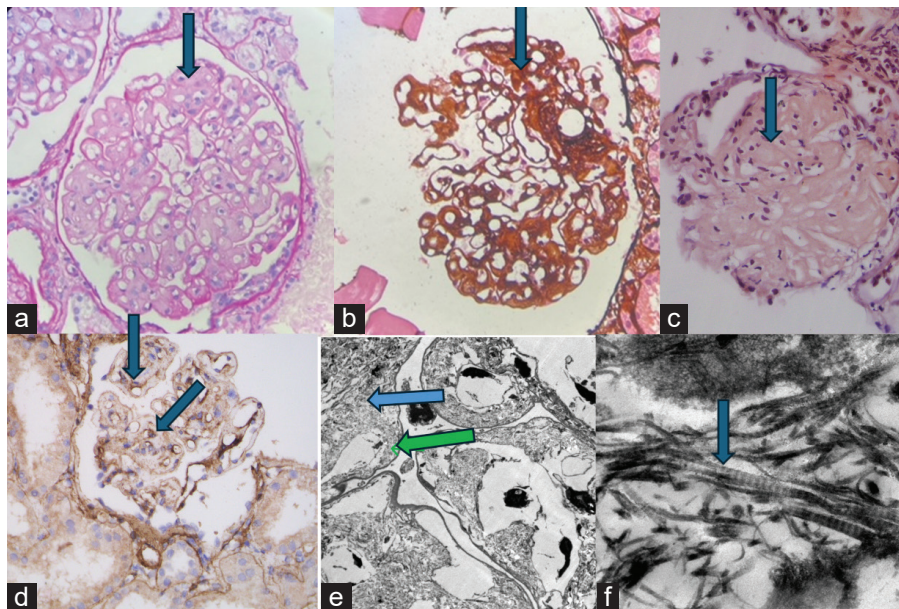


Figure 1: (a) PAS negative widened mesangium (400x, blue arrow), (b) Silver negative widened mesangium (400x, blue arrow), (c) Congo red negative widened mesangium (400x, blue arrow), (d) Type III collagen IHC, blue arrows marking peripheral and mesangial location of IHC stain. (e) Electronmicroscopy, blue arrow pointing mesangial location, green arrow pointing subendothelial location of fibrils. Original magnification 600x. (f) Electronmicroscopy, Curvilinear banded fibrils, 29.15 nm, original magnification 10000x, blue arrow.

by immunohistochemistry. The patient was prescribed an angiotensin receptor blocker and is being followed up.

Organized deposit disease must be considered in the differential diagnosis for any patient presenting with significant proteinuria, irrespective of age, gender, or systemic disease. Clinical history of comorbid conditions, light microscopy, immunofluorescence, and electronmicroscopy together play an important role in the diagnosis of this entity.

Conflicts of interest

There are no conflicts of interest.

Naga Sarika Vennavalli¹, Sashi Kiran Annavarajula², Shaila Raju Khubchandani³, Dhiraj Vilas Wasnik²

Departments of ¹Histopathology, ²Nephrology, Yashoda Hospitals, Hyderabad, Telangana, ³Department of Histopathology & Electron Microscopy, Sir H. N. Reliance Foundation Hospital and Research Centre, Girgaon, Mumbai, India

Corresponding author:

Naga Sarika Vennavalli, Department of Histopathology, Yashoda Hospitals, Hyderabad, Telangana, India. E-mail: sarivennavalli@gmail.com

This is an open access journal, and articles are distributed under the terms of the Creative Commons Attribution-NonCommercial-ShareAlike 4.0 License, which allows others to remix, tweak, and build upon the work non-commercially, as long as appropriate credit is given and the new creations are licensed under the identical terms.

How to cite this article: Vennavalli NS, Annavarajula SK, Khubchandani SR, Wasnik DV. Collagenofibrotic Glomerulopathy—An Unexpected Finding in a Young Female. Indian J Nephrol. 2024;34:544-5. doi: 10.25259/IJN_164_2024

Received: 07-04-2024; **Accepted:** 09-04-2024;
Online First: 08-07-2024; **Published:** 30-08-2024
DOI: 10.25259/IJN_164_2024



Hub and Spoke Model for Kidney Care – From Prevention to Treatment

Dear Editor,

India adds 200,000 new end-stage kidney disease (ESKD) patients to the existing pool annually. The country has seen a revolution in dialysis with 1452 dialysis centers in 748 out of 806 districts with 9902 machines under the Pradhan Mantri National Dialysis Program (PMNDP) model.¹ There are approximately 2500 nephrologists, with the majority practicing in urban areas. To address the shortage of nephrologists in rural peripheral districts, the state of Telangana has started a hub and

spoke model of dialysis where the hub center, usually a teaching hospital in the city, monitors the spoke dialysis centers in the surrounding districts within a radius of 200–250 km [Table 1]. A local medical officer trained at a hub center is responsible for managing each spoke center under the guidance of the hub nephrologist.² This has markedly improved the quality of dialysis. Telemonitoring facilities have been initiated between the hub and spoke centers in some states, which is commendable.

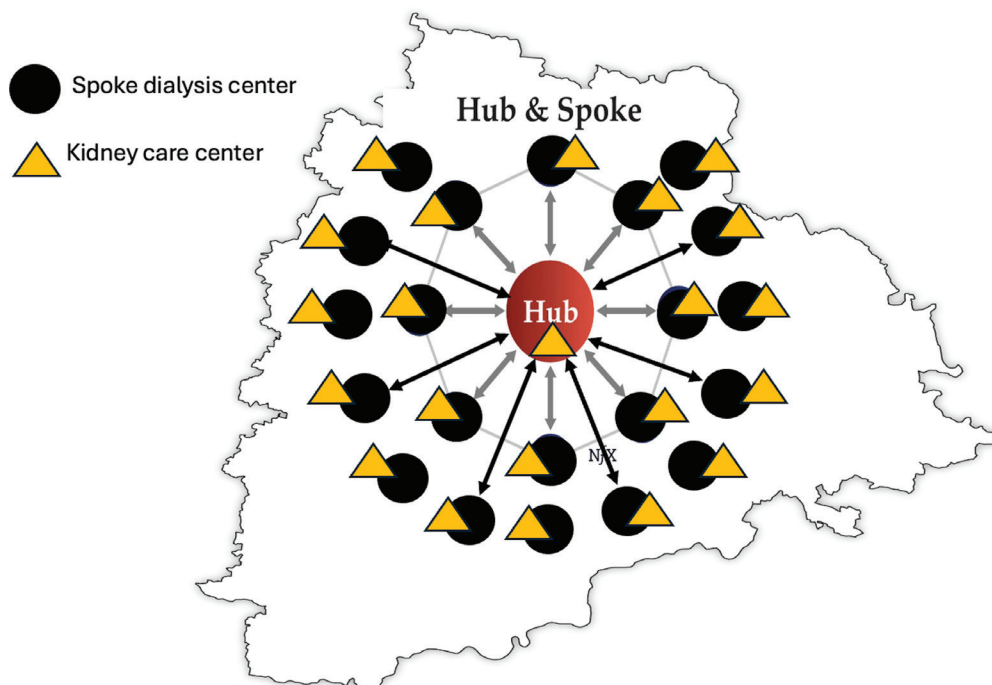


Figure 1: Hub and spoke model of kidney disease prevention and kidney replacement therapy (KRT).