



Metachromatic Leukodystrophy and Infantile Onset Nephrotic Syndrome: A Rare Confluence

Dear Editor,

More than 58 monogenic variants have been associated with steroid-resistant nephrotic syndrome (SRNS).¹ This is a novel case of SRNS linked to *PKHD1* and *ARSA* variations.

A 2-year-old male presented with persistent generalized swelling for 3 months and regression of developmental milestones at one year of age. The child was born to non-consanguineous parents and had severe acute malnutrition along with nephrotic-range proteinuria. Six weeks of daily steroids showed no remission. Sanger sequencing confirmed heterozygous variants on exons 66 and 2 of *PKHD1* and *ARSA* genes, respectively [Figure 1]. It is difficult to attribute causality between our findings and the clinical presentation. No abnormalities were found in auditory, ophthalmologic, or family screening. The child was prescribed tacrolimus and ACE inhibitor and is in

complete remission with height and weight gain after 4 months.

Metachromatic leukodystrophy (MLD) caused by *ARSA* mutations, is a lysosomal storage disorder characterized by sulfatide accumulation. Although rare, sulfatide deposition in glomerular podocytes can disrupt filtration and protein homeostasis.² Podocytes, highly sensitive to lysosomal dysfunction, may exhibit structural and functional impairments in SRNS. Data on renal involvement in MLD remains limited with previous reports including two MLD cases with renal tubular acidosis (proximal in 1978, distal in 2024).^{3,4}

This case expands MLD's phenotypic spectrum, linking it to SRNS and highlighting the role of advanced genetic diagnostics in rare etiologies. It underscores the need for further research into the pathophysiological mechanisms linking MLD and renal dysfunction.

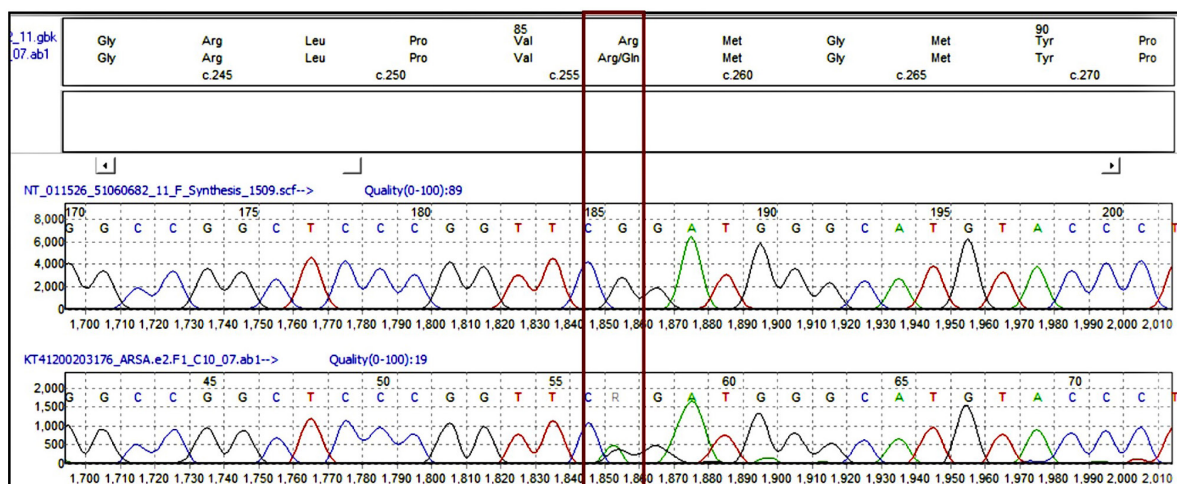


Figure 1: Sanger sequencing data (electropherogram) showing nucleotide change at chr22: c.257G>A, (p.Arg86Gln) in the *ARSA* gene. Red, green, black, and blue color peaks show thymine, adenine, guanine, and cytosine bases, respectively. The red box highlights the specific nucleotide change at chromosome 22: c.257G>A, which results in the amino acid substitution p.Arg86Gln in the *ARSA* gene.

Acknowledgement: We thank all staff involved in the care of this patient.

Conflicts of interest: There are no conflicts of interest.

Nitish Kumar¹, Rajesh Kumar¹, Prem Ranjan Kumar¹

¹Department of Pediatrics, Rani Hospital, Ranchi, Jharkhand, India

Corresponding author: Nitish Kumar, Department of Pediatrics, Rani Hospital, Ranchi, Jharkhand, India. E-mail: doctornitishkumar@gmail.com

References

- Solanki AK, Widmeier E, Arif E, Sharma S, Daga A, Srivastava P, et al. Mutations in *KIRREL1*, a slit diaphragm component, cause steroid-resistant nephrotic syndrome. *Kidney Int* 2019;96:883-9.
- Merscher S, Fornoni A. Podocyte pathology and nephropathy-sphingolipids in glomerular diseases. *Front Endocrinol* 2014;5:127.
- Rodriguez-Soriano J, Rivera JM, Vallo A, Prats-Viñas JM, Castillo G. Proximal renal tubular acidosis in metachromatic leukodystrophy. *Helv Paediatr Acta* 1978;33:45-52.

4. Kumar N, Panda S, Shanker A. A rare clinical confluence: Metachromatic leukodystrophy and distal renal tubular acidosis. *Indian J Nephrol* 2025;35:115.

This is an open access journal, and articles are distributed under the terms of the Creative Commons Attribution-NonCommercial-ShareAlike 4.0 License, which allows others to remix, transform, and build upon the work non-commercially, as long as appropriate credit is given and the new creations are licensed under the identical terms.

How to cite this article: Kumar N, Kumar R, Kumar PR. Metachromatic Leukodystrophy and Infantile Onset Nephrotic Syndrome: A Rare Confluence. *Indian J Nephrol*. doi: 10.25259/IJN_52_2025

Received: 25-01-2025; **Accepted:** 18-02-2025;

Online First: 24-04-2025; **Published:** ***

DOI: 10.25259/IJN_52_2025

