

Post-COVID Multisystem Inflammatory Syndrome–Adult (MIS-A) Presenting with Rhabdomyolysis and AKI

Abstract

Multisystem inflammatory syndrome is a rarely reported post-COVID (coronavirus disease) phenomenon in adults. Our understanding of the multisystem inflammatory syndrome–adult (MIS-A) is based on multiple case reports that have demonstrated heterogeneous clinical presentations and treatment options. Rhabdomyolysis is an unusual presentation of MIS-A. We report the case of a 61-year-old man who presented with rhabdomyolysis with acute kidney injury (AKI), acute inflammatory demyelinating polyneuropathy (AIDP), myocarditis, disseminated intravascular coagulation, and minimal respiratory symptoms. The patient was found to have post-COVID inflammatory syndrome and recovered with supportive treatment and intravenous immunoglobulin (2 g/kg over 5 days). COVID-19 (coronavirus disease 2019) antibody positivity played a significant role in making the diagnosis of MIS-A and in providing prompt treatment.

Keywords: Acute kidney injury, COVID-19, multisystem inflammatory syndrome–adult, rhabdomyolysis

Introduction

The severe acute respiratory syndrome coronavirus 2 (SARS-CoV-2) responsible for the ongoing coronavirus disease 2019 (COVID-19) pandemic has been the focus of research for more than a year. Novel and complex manifestations of the disease are being documented. COVID-19-associated multisystem inflammatory syndrome in children (MIS-C) is a well-established entity.^[1] Recently, a similar syndrome in adults has also been recognized, namely, multisystem inflammatory syndrome in adults (MIS-A).^[2] Acute kidney injury (AKI) and rhabdomyolysis are known complications of COVID-19 infection, with rhabdomyolysis occurring in 7% to 20% of patients with evidence of COVID-19 AKI.^[3,4] Rhabdomyolysis and AKI may present as a late complication of COVID-19 suggesting that the virus may have the potential to cause postviral myopathy.^[5] AKI has been reported in 2% to 8% of MIS-C,^[6] whereas its occurrence is not well-established in MIS-A. We report a case with post-COVID MIS-A presenting with rhabdomyolysis and AKI.

This is an open access journal, and articles are distributed under the terms of the Creative Commons Attribution-NonCommercial-ShareAlike 4.0 License, which allows others to remix, tweak, and build upon the work non-commercially, as long as appropriate credit is given and the new creations are licensed under the identical terms.

For reprints contact: WKHLRPMedknow_reprints@wolterskluwer.com

Case Report

A 61-year-old male presented to the emergency department with complaints of decreased urine output, nausea, and vomiting for 1 day. Twelve days prior, he had low-grade fever for 3 days, which subsided with paracetamol. A week after the fever subsided, he noticed a decreased sensation in both feet, weakness of both lower limbs, and clumsiness of both hands. He also complained of severe pain and swelling in both thighs. There was no history of cough, expectoration, or shortness of breath. He did not receive any medical attention during the episode of fever. There was a history of hypertension, hypothyroidism, coronary artery disease, and a percutaneous transluminal coronary angioplasty (PTCA) 5 months back. He was taking tablet amlodipine 5 mg once daily, levothyroxine 25 µg once daily, ticagrelor 90 mg twice daily, aspirin 75 mg once daily, and rosuvastatin 40 mg once a day. He was not yet vaccinated against COVID-19.

On examination, he was afebrile, his blood pressure was 112/72 mmHg, pulse rate was 92 per minute, and SpO₂ was 95% on room air. There was tenderness of both thighs and calves. On auscultation, the lungs were clear. Examination of the heart and

How to cite this article: Mazumder MA, Narula AS, Gulati S, Shehwar D, Mir IM. Post-COVID multisystem inflammatory syndrome–adult (MIS-A) presenting with rhabdomyolysis and AKI. *Indian J Nephrol* 2022;32:629-32.

Mastakim Ahmed Mazumder,
Ajit Singh Narula¹,
Sanjeev Gulati¹,
Durre Shehwar²,
Ishrat Majid Mir

Consultant Nephrology and Kidney Transplant, Kidney and Urology Institute, Fortis Escorts, Okhla, New Delhi, ¹Director Nephrology and Kidney Transplant, Kidney and Urology Institute, Fortis Escorts, Okhla, New Delhi, ²Department of Pathology, Jawaharlal Nehru Medical College and Hospital, Aligarh, Uttar Pradesh, India

Received: 30-06-2021
Revised: 16-08-2021
Accepted: 24-08-2021
Published: 01-12-2022

Address for correspondence:
Dr. Mastakim Ahmed Mazumder,
Consultant Nephrology and
Kidney Transplant, Kidney
and Urology Institute, Fortis
Escorts, Okhla, New Delhi,
India.
E-mail: nustakimmazumder@gmail.com

Access this article online

Website: www.indianj nephrol.org

DOI: 10.4103/ijn.ijn_284_21

Quick Response Code:



abdomen was normal. Neurological examination showed higher mental functions and cranial nerves to be normal. Power in the proximal and distal muscles of all four limbs was 3/5. Deep tendon jerks at the ankle and knees were sluggish, and plantar response was flexor. There was no sensory deficit.

Laboratory investigations revealed the following: Hemoglobin of 8 g/dL, white blood cell (WBC) count of 15,300/mm³, with 10% lymphocytes, platelet count 2.14L/cmm, blood urea nitrogen 67.23 mg/dL, serum creatinine 8.02 mg/dL, sodium 127 mmol/L, potassium 5.43 mmol/L, aspartate aminotransferase 862 U/L, alanine aminotransferase 490 U/L, troponin T 389 pg/mL, NT-proBNP (N-terminal pro-brain natriuretic peptide) 10,800 pg/mL, and procalcitonin 0.968 ng/mL. Blood cultures were negative, and urine cultures grew *Escherichia coli*, C-reactive protein was 55.8 mg/L, serum ferritin 1,100 ng/mL, lactate dehydrogenase 7,250 U/L, creatine kinase (CK) 55,920 U/L, CK-MB 34 U/L, and thyroid stimulating hormone 30.53 mIU/L. Arterial blood gas was suggestive of compensated metabolic acidosis. Urinalysis was notable for 2+ blood and 3+ protein. Catheterized urine sediment showed 6 to 8 red blood cells, 8 to 10 WBCs, and granular casts. Urine myoglobin was 1,100 ng/mL, chest X-ray revealed few ill-defined peripheral opacities bilaterally, and high-resolution computed tomography thorax was suggestive of bilateral subpleural opacities and bilateral mild pleural effusion. SARS-CoV-2 RT-PCR (reverse transcription polymerase chain reaction) on the initial nasopharyngeal swab was negative. SARS-CoV-2 immunoglobulin G (IgG) antibody was positive with a titer of 10.0 (reference >1.1 positive). Autoimmune profiles, including ANA and ANCA serology, were negative, and complement levels were normal. On ultrasound of kidneys, the right kidney was 11.3 cm × 4.2 cm, and the left kidney was 10.8 cm × 4.3 cm. Echocardiography showed regional wall motion abnormalities in the apical and mid-anterior segments, with an ejection fraction of 45%.

A nerve conduction velocity (NCV) test of both median, both (right and left) ulnar, both tibial, and both peroneal nerves was done. NCV test showed delayed F-waves and markedly reduced H-amplitude in all tested nerves. Bilateral median and ulnar nerves had normal SNAP (sensory nerve action potential) amplitude with increased distal latency (DL) and decreased SNCV (sensory nerve conduction velocity). Sural nerve bilaterally showed normal SNAP amplitude with normal DL and normal SNCV. NCV was suggestive of acute inflammatory demyelinating polyneuropathy (AIDP).

On Day 4 of admission, he developed a lower gastrointestinal (GI) bleed. Upper GI endoscopy and colonoscopy were normal. A selective superior

mesenteric arterial angiography showed bleeding from the two ileal branches. The coagulation profile showed a platelet count of 78,000/μL, a prothrombin time of 43s, INR (international normalized ratio) 4.14, aPTT (activated partial thromboplastin time) 49s, and D-dimer 5.57 μ/mL.

He was diagnosed to have post-COVID MIS-A: rhabdomyolysis with AKI, AIDP, myocarditis, and disseminated intravascular coagulation. He was managed with antibiotics, intermittent hemodialysis, blood and fresh frozen plasma, and intravenous immunoglobulin (2 g/kg over 5 days). For the ileal bleed, he underwent a super-selective arterial embolization of the bleeding vessels [Image 1]. Over the next 3 weeks, his renal functions improved, the power improved in all four limbs, the muscle tenderness subsided, creatine phosphokinase normalized, and the bleeding parameters were normal.

Discussion

The SARS-CoV-2 responsible for the ongoing pandemic of COVID-19 has been the focus of research for more than a year. Novel and complex manifestations of the disease are being documented. COVID-19-associated MIS-C is a well-established entity.^[1] Recently, a similar syndrome in adults has also been recognized, that is, MIS-A. MIS-A symptoms have been reported about 2 to 5 weeks after the initial COVID-19 symptoms when the nucleic acid may be negative but the antibody test remains positive. The interval between infection and development of MIS-A is unclear, adding to uncertainty regarding whether MIS-A represents a manifestation of acute infection or an entirely post-COVID phenomenon. The Centers for Disease Control and Prevention (CDC) proposed a case definition for MIS-A, which included individuals aged ≥21 years, positive SARS-CoV-2 testing (PCR, antigen, or antibody)

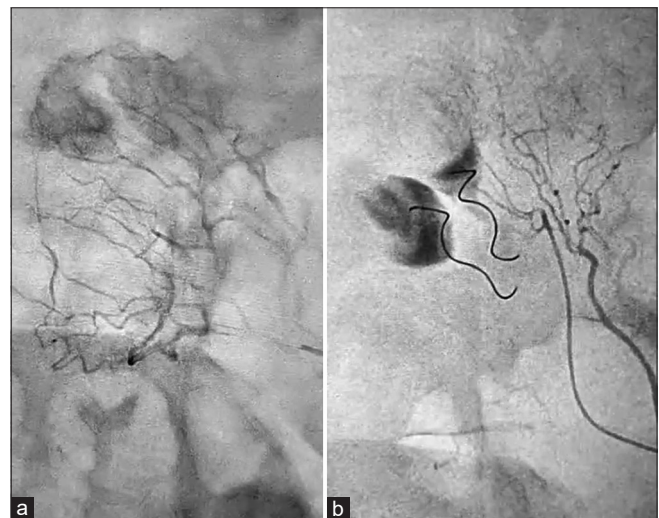


Image 1: (a) Before arterial embolization of ileal bleed. (b) After arterial embolization of ileal bleed

indicating recent infection, multiorgan dysfunction without severe respiratory illness, and markedly elevated acute inflammatory markers. The absence of severe respiratory illness excludes the possibility of organ dysfunction as a result of tissue hypoxia. Although there is heterogeneity in the case reports with regard to organ systems involved, the common clinical features included fever (75%), chest pain or palpitations (38%) with cardiac abnormalities (100%), gastrointestinal symptoms (81%), and dermatologic manifestations (31%).^[2] AKI where reported is usually due to profound GI symptoms leading to hypovolemia.^[7]

The pathophysiology of MIS in both children and adults is currently unknown. An exaggerated immune response with persistent fevers, elevated inflammatory markers, and elevated proinflammatory cytokines has been described in COVID-19.^[8] The resulting immune dysregulation can lead to multiple immune-mediated sequelae. Although clear evidence of immune pathophysiology has not been established, an antibody-related immune response may be responsible for MIS-A. It is thought of as a postinfectious syndrome rather than an infection in the acute stage of development.^[2,9] There is no standard treatment protocol available for MIS-A, but there are reports of beneficial outcomes with steroids, intravenous immunoglobulin (IVIG), and the interleukin (IL)-6 inhibitor tocilizumab.^[2,10]

The unusual feature in our case was the late onset of rhabdomyolysis as a cause of AKI. The etiology of rhabdomyolysis was not clear. Statin-induced rhabdomyolysis is rare in the absence of concomitant drugs such as fibrates or fusidic acid, and the onset of symptoms ranges from 1 to 60 days (mean 9 days).^[11] Ticagrelor has also been reported to precipitate statin-induced rhabdomyolysis.^[12] Hypothyroid state in patients on statin therapy can also increase the risk of rhabdomyolysis.^[13] We considered statin-induced rhabdomyolysis to be precipitated by either uncontrolled hypothyroidism or ticagrelor. In addition to increasing the dose of levothyroxine, we stopped both rosuvastatin and ticagrelor therapies. However, several case reports have also described rhabdomyolysis as an initial manifestation of COVID-19, and few reports have suggested rhabdomyolysis to be a post-COVID phenomenon.^[5,14] Our patient was a known hypothyroid on treatment and was asymptomatic for 5 months while on statin and ticagrelor therapy. Considering the other clinical features of multisystem involvement, there is a possibility that the rhabdomyolysis in our patient might be a sequela of COVID-19.

Our patient's presentation was with multiple-organ involvement with minimal respiratory findings. Although there was a history of fever, RT-PCR was negative and COVID antibodies were positive, indicating a postinfectious syndrome. Our patient responded well to IVIG and

supportive care and had a good recovery of neurological and renal functions.

Conclusion

MIS-A can present as a serious post-COVID phenomenon, and early diagnosis and initiation of treatment can lead to a positive outcome. The etiology of rhabdomyolysis in this patient cannot be determined, but COVID-19 sequela is a possibility that needs further research. IVIG remains an effective treatment option.

Declaration of patient consent

The authors certify that they have obtained all appropriate patient consent form. In the form, the patient has given his consent for his images and other clinical information to be reported in the journal. The patient understands that his name and initials will not be published and due efforts will be made to conceal his identity.

Financial support and sponsorship

Nil.

Conflicts of interest

There are no conflicts of interest.

References

1. Chiotos K, Bassiri H, Behrens EM, Blatz AM, Chang J, Diorio C, *et al.* Multisystem inflammatory syndrome in children during the coronavirus 2019 pandemic: A case series. *J Pediatr Infect Dis Soc* 2020;9:393-8.
2. Morris SB, Schwartz NG, Patel P, Abbo L, Beauchamps L, Balan S, *et al.* Case series of multisystem inflammatory syndrome in adults associated with SARS-CoV-2 infection-United Kingdom and United States, March-August 2020. *MMWR Morb Mortal Wkly Rep* 2020;69:1450-6.
3. Pei G, Zhang Z, Peng J, Liu L, Zhang C, Yu C, *et al.* Renal involvement and early prognosis in patients with COVID-19 pneumonia. *J Am Soc Nephrol* 2020;31:1157-65.
4. Mohamed MM, Lukitsch I, Torres-Ortiz AE, Walker JB, Varghese V, Hernandez-Arroyo CF, *et al.* Acute kidney injury associated with coronavirus disease 2019 in urban New Orleans. *Kidney360* 2020;1:614-22.
5. Byler J, Harrison R, Fell LL. Rhabdomyolysis following recovery from severe COVID-19: A case report. *Am J Case Rep* 2021;22:e931616.
6. Feldstein LR, Rose EB, Horwitz SM, Collins JP, Newhams MM, Son MB, *et al.* Multisystem inflammatory syndrome in US children and adolescents. *N Engl J Med* 2020;383:334-46.
7. Kofman AD, Sizemore EK, Detelich JF, Albrecht B, Piantadosi AL. A young adult with COVID-19 and multi system inflammatory syndrome in children (MIS-C)-like illness: A case report. *BMC Infect Dis* 2020;20:716.
8. Mehta P, McAuley DF, Brown M, Sanchez E, Tattersall RS, Manson JJ, *et al.* COVID-19: Consider cytokine storm syndromes and immunosuppression. *Lancet* 2020;395:1033-4.
9. Jiang L, Tang K, Levin M, Irfan O, Morris SK, Wilson K, *et al.* COVID-19 and multisystem inflammatory syndrome in children and adolescents. *Lancet Infect Dis* 2020;20:e276-88.

10. Shaigany S, Gnrke M, Guttman A, Chong H, Meehan S, Raabe V, *et al.* An adult with Kawasaki-like multisystem inflammatory syndrome associated with COVID-19. *Lancet* 2020;396:e8-10.
11. Mendes P, Robles PG, Mathur S. Statin-induced rhabdomyolysis: A comprehensive review of case reports. *Physiother Can* 2014;66:124-32.
12. Kariyanna PT, Haseeb S, Chowdhury YS, Jayarangaiah A, Maryniak A, Mo G, *et al.* Ticagrelor and statin interaction induces rhabdomyolysis and acute renal failure: Case reports and scoping review. *Am J Med Case Rep* 2019;7:337-41.
13. Jbara Y, Bricker D. Rhabdomyolysis in the setting of induced hypothyroidism and statin therapy: A case report. *Eur Thyroid J* 2015;4:62-4.
14. Rivas-García S, Bernal J, Bachiller-Corral J. Rhabdomyolysis as the main manifestation of coronavirus disease 2019. *Rheumatology* 2020;59:2174-6.