



## NELL-1 Associated Membranous Nephropathy - A Case Series from India

### Abstract

Neural epidermal growth factor-like 1 (NELL-1) is responsible for a substantial proportion of cases of PLA2R-negative primary membranous nephropathy (MN). To investigate the occurrence, association, and treatment responses, we carried out this ambispective study. In the study, nine (10%) of all patients with MN at our center were found to be NELL-1 positive. On follow up, all patients received immunosuppression (steroids, cyclophosphamide or rituximab). Five patients were in complete remission, while one patient had partial remission, two patients had a progressive decline in kidney function, and one patient was lost to follow-up early. No link was found with malignancies, traditional Indian medicines or infection.

**Keywords:** NELL-1, Membranous nephropathy, nephrotic syndrome, MN, glomerulonephritis

### Introduction

Neural epidermal growth factor-like 1 (NELL-1) is the antigen responsible for approximately 16% of cases of PLA2R-negative primary membranous nephropathy (MN).<sup>1</sup> Research on the role of this antibody concerning its correlation with other diseases, particularly cancers, its reaction to immunosuppressive therapy, and its impact on kidney health is still in the early stages. To investigate the occurrence, characteristics, associations, and treatment responses, we examined prospective data up to September 2022 and retrospective data from January 2018 to March 2021 on all histologically confirmed MN. We employed immunohistochemistry to apply specific antibodies to detect the NELL-1 antigen in renal tissue.

### Case Series

Over a period of 5 years, of the 90 patients with MN seen at our center, nine (10%) patients were detected with NELL-1 MN. Out of nine patients, six were males and three were females. The median age was 39 years [Table 1]. The baseline median urine protein creatinine ratio (UPCR) was 4.71 g/g (range: 1.02-10.71), median serum albumin was 2.95 g/dL, and creatinine levels varied between 0.61 and 9.39 mg/dL,

with the median value recorded at 1.26 mg/dL. Out of nine patients, one had MN secondary to lupus nephritis. None of our patients had been identified with any malignancy or had taken indigenous medicines. One patient was dual positive for PLA2R and NELL-1 antigen. On histopathology, all patients had thickening of glomerular capillary basement membrane with argyrophilic epimembranous spikes in five of the nine cases. No segmental sclerosis was seen in any of the cases. IgG was the most consistent immunoglobulin on immunofluorescence [Table 2]. IgG deposit was diffuse and granular in all cases along the glomerular capillary basement membrane [Figure 1]. NELL-1 staining pattern was also diffuse, and granular deposits were noted along the glomerular capillary basement membrane [Figure 2]. The follow-up period was 1-42 months (median: 13 months). At the end of the study, five patients were in complete remission (UPCR <300 mg/g), while one patient had partial remission (UPCR >300 mg but >50% reduction from the baseline), two patients had a progressive decline in kidney function (>50% increase in the creatinine from the baseline), and one patient was lost to follow-up early.

**Table 1: Baseline characteristics of patients with NELL-1-positive membranous nephropathy**

Age	Baseline (UPCR g/g)	Baseline albumin (g/dL)	Baseline creatinine (mg/dL)	Treatment	Follow up duration (months)	Follow up UPCR (g/g)	Albumin (g/dL)	Creatinine (mg/dL)	Outcome
52	2.1	1.71	1.26	MMF + Steroids	17	1.1	2.44	2.2	KD
59	5.6	2.66	0.95	Rituximab	42	0.06	4.56	0.84	CR
53	10.71	1.71	1.27	Cyclophosphamide + Steroids	36	7.05	2.44	1.97	KD
26	2.1	3.6	1.46	Rituximab	13	0.58	3.67	1.53	PR
53	1.02	1.89	1.33	Steroids	1	1.029	1.37	2.92	Loss to follow-up
33	6.7	3.2	9.39	Steroids	4	0.06	4.2	0.68	CR
34	4.71	3.5	0.61	Rituximab	13	0.24	4.0	0.50	CR
35	3.2	3.2	0.78	Rituximab	9	0.07	4.49	0.9	CR
39	7.39	2.95	0.74	Rituximab	15	0.21	3.5	1.32	CR

MMF: Mycophenolate Mofetil, UPCR: urine protein creatinine ratio, KD: Progressive kidney decline, CR: complete remission, PR: partial remission. NELL-1: Neural epidermal growth factor-like 1

**Table 2: Kidney biopsy findings in patients with NELL-1 positive**

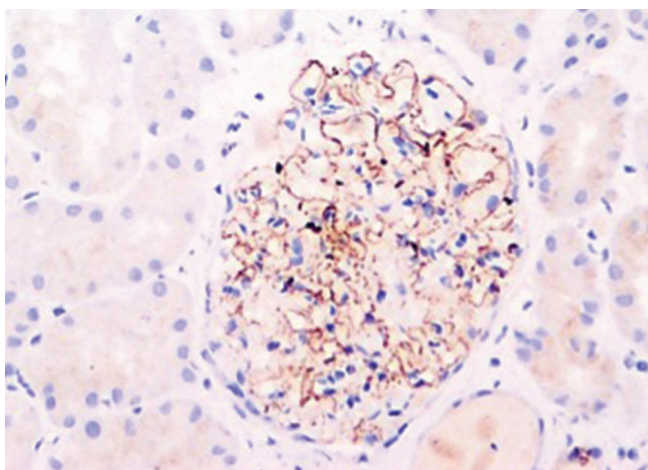
Light microscopy	IgG	IgM	IgA	C1Q
Membranous nephropathy with acute interstitial nephritis, Lupus nephritis (ISN/RPS class V).	3+	1+	-	3+
Membranous nephropathy	2+	-	-	-
Membranous nephropathy	3+	-	-	-
Membranous nephropathy	-	-	-	-
Early Membranous nephropathy with acute interstitial nephritis.	3+	1+	-	1+
Membranous nephropathy with acute interstitial nephritis.	3+	2+	-	-
Membranous nephropathy	3+	-	-	-
Membranous nephropathy	3+	-	-	-
Membranous nephropathy	3+	-	-	-

IgG: Immunoglobulin G, IgM: Immunoglobulin M, IgA: Immunoglobulin A, C1Q: Complement component 1q, ISN/RPS: Indian Society of Nephrology/Renal Pathology Society, NELL: Neural epidermal growth factor

## Discussion

NELL-1 encodes a protein kinase C-binding protein, which is expressed in the kidney tubules and rarely in the glomeruli.<sup>2</sup> It can also be expressed in malignancy-associated secondary MN patients.

In Sethi *et al.* study, 29 NELL-1-associated MN cases had a mean age of 63 years, while Caza T *et al.* larger study had 91 cases with a mean age of 66.8 years and a male predominance.<sup>3,3</sup> Our study differs, with a younger mean age of 42.66 years, potentially accounting for the lower malignancy rates. The significance of the link between NELL-1 and various diseases needs further study. Sethi *et al.* reported associations with cancers and autoimmune conditions, but our patient with NELL-1 and lupus nephritis had no such history, suggesting unique profiles in our cohort.<sup>4</sup>



**Figure 1:** NELL-1 antigen demonstration by immunohistochemistry (Original magnification x200). NELL-1: Neural epidermal growth factor-like 1

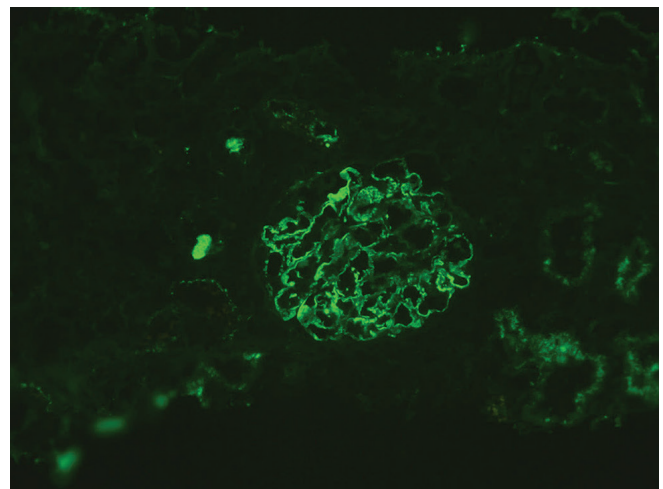
Concurrent AIN with MN is rare, with only one case among 594 patients in Chen T *et al.*'s study.<sup>5</sup> However, we found three NELL-1 MN cases with AIN, none related to known triggers. Prior research has not delineated an increased incidence of AIN in MN. Consequently, further investigations are imperative to ascertain whether the observed correlation is incidental or indicative of a causative linkage.

In our study, five out of nine patients were treated with rituximab. Four of these patients achieved complete remission, while one saw partial improvement. In contrast, a patient on cyclophosphamide and steroids did not improve. Patients with AIN treated only with steroids had varied outcomes: one reached complete remission, while another was lost to follow-up. Supporting these findings, a Chinese study with 15 NELL-1 MN patients observed 92% remission with immunosuppressive therapy (steroids + cyclophosphamide or cyclosporine) over  $25 \pm 21$  months.<sup>6</sup> In addition, a Japanese study found similar success in remission with immunosuppression (steroids or steroids + cyclophosphamide).<sup>7</sup> This collective evidence suggests that immunosuppression is generally effective against NELL-1-associated MN.

One patient of MN was dual positive for PLA2R and NELL-1 antigen. Till now, only a single case has been reported in the literature.<sup>8</sup> The significance of dual positivity on presentation or course is yet to be determined.

## Conclusion

Notably, we found no links with malignancies, traditional Indian medicines, or infections. It remains uncertain whether these findings are serendipitous or attributable to distinct environmental and genetic factors inherent to the Indian population. To clarify the correlation of NELL-1-associated MN with these elements within the Indian



**Figure 2:** NELL-1 staining on immunofluorescence (Original magnification x200). NELL-1: Neural epidermal growth factor-like 1

demographic, an expansion to larger patient cohorts is necessary.

#### Declaration of patient consent

The authors certify that they have obtained all appropriate patient consent.

#### Conflicts of interest

There are no conflicts of interest.

**Yogita Sharma<sup>1</sup>, Akash Jain<sup>1</sup>, Pallav Gupta<sup>2</sup>,  
Vaibhav Tiwari<sup>1</sup>, Anurag Gupta<sup>1</sup>, Vinant Bhargava<sup>1</sup>,  
Manish Malik<sup>1</sup>, Ashwani Gupta<sup>1</sup>, Anil Kumar Bhalla<sup>1</sup>,  
Devinder Singh Rana<sup>1</sup>**

*Departments of Nephrology, and <sup>2</sup>Pathology, Sir Ganga Ram Hospital,  
New Delhi, India*

#### Corresponding author:

*Vaibhav Tiwari, Department of Nephrology, Sir Ganga Ram Hospital,  
New Delhi, India. E-mail: drvt87@gmail.com*

#### References

1. Sethi S, Debiec H, Madden B, Charlesworth MC, Morelle J, Gross L, et al. Neural epidermal growth factor-like 1 protein (NELL-1) associated membranous nephropathy. *Kidney Int* 2020;97:163–74.
2. Watanabe TK, Katagiri T, Suzuki M, Shimizu F, Fujiwara T, Kanemoto N, et al. Cloning and characterization of two novel human cDNAs (NELL1 and NELL2) encoding proteins with six EGF-like repeats. *Genomics* 1996;38:273–6.
3. Caza T, Hassen S, Dvanajscak Z, Kuperman M, Edmondson R, Herzog C, et al. NELL1 is a target antigen in malignancy-associated membranous nephropathy. *Kidney Int* 2020;99:P967-76.
4. Sethi S. The many faces of NELL1 MN. *Clin Kidney J* 2023;16:442–6.
5. Chen T, Zhou Y, Chen X, Chen B, Pan J. Acute kidney injury in idiopathic membranous nephropathy with nephrotic syndrome. *Ren Fail* 2021;43:1004–11.
6. Wang G, Sun L, Dong H, Wang Y, Xu X, Zhao Z, et al. Neural epidermal growth factor-like 1 protein-positive membranous nephropathy in Chinese patients. *Clin J Am Soc Nephrol* 2021;16:727–35.
7. Iwakura T, Ema C, Isobe S, Fujikura T, Ohashi N, Kato A, et al. Prevalence of neural epidermal growth factor-like 1- and exostosin 1/exostosin 2-associated membranous nephropathy: A single-center retrospective study in Japan. *Sci Rep* 2022;12:2967.
8. Wang G, Sun L, Dong H, Wang Y, Xu X, Zhao Z, et al. Neural epidermal growth factor-like 1 protein-positive membranous nephropathy in Chinese patients. *Clin J Am Soc Nephrol* 2021;16:727-35.

This is an open access journal, and articles are distributed under the terms of the Creative Commons Attribution-NonCommercial-ShareAlike 4.0 License, which allows others to remix, tweak, and build upon the work non-commercially, as long as appropriate credit is given and the new creations are licensed under the identical terms.

**How to cite this article:** Sharma Y, Jain A, Gupta P, Tiwari V, Gupta A, Bhargava V, et al. NELL-1 Associated Membranous Nephropathy - A Case Series from India. *Indian J Nephrol*. doi: 10.25259/ijn\_326\_23

**Received:** 28-07-2023; **Accepted:** 07-12-2023;

**Online First:** 04-06-2024; **Published:** \*\*\*

**DOI:** 10.25259/ijn\_326\_23

