

**Case 1:** A 31-year-old man underwent a pre-transplant evaluation including CDC-XM, FC-XM, panel reactive antibody (PRA) testing, and DSA-SAB assay with his father as a donor. Despite negative results in CDC-XM and FC-XM, the DSA-SAB assay revealed unexpected weak-to-moderate positivity (MFI range = 1000-5000) against a wide range of HLA class I and class II antigens [Figure 1a and 1b]. PRA testing showed no HLA sensitization [Figure 1c and 1d], but the test negative control (CON) values were high, indicating the nonspecific binding, which leads to false-positive tests. In such a scenario, PRA testing alongside DSA-SAB helps.<sup>2</sup>

**Case 2:** A 33-year-old man was planned for transplant with his sister as a donor. Patient exhibited HLA class II positivity for self-antigen DRB1\*13:01, in DSA-SAB testing (Immucor). However, CDC-XM and FC-XM were negative. Repeat testing with another kit from a different vendor (One Lambda, Inc.) showed the absence of antibodies for self-antigen DRB1\*13:01. Reported false positivity may occur due to the presence of antibodies to denatured antigens.<sup>2,3</sup>

We propose stepwise strategies to address these diagnostic challenges:

1. Patient history should be assessed thoroughly for sensitization events.
2. Conduct high-resolution typing and utilize multiple assays to determine true antibodies, including different platforms, solid-phase assays and kits from other vendors.
3. Perform epitope analysis to decipher antibody specificities.<sup>4</sup>

This letter emphasizes the importance of quality control, technical validation, and personalized patient-focused assessments in pre-kidney transplant evaluations.

#### Acknowledgment

We acknowledge Mr. Manoj Kumar and Mr. Heera Singh for technical assistance.

**Conflicts of interest:** There are no conflicts of interest.

**Lekha Rani<sup>1</sup>, Ritu Aggarwal<sup>1</sup>, Mahendra Kumar<sup>1</sup>, Raja Ramachandran<sup>2</sup>, Ashish Sharma<sup>3</sup>, Ranjana W. Minz<sup>1</sup>**

Departments of <sup>1</sup>Immunopathology, <sup>2</sup>Nephrology, <sup>3</sup>Renal Transplant Surgery, Post Graduate Institute of Medical Education and Research (PGIMER), Chandigarh, India.

**Corresponding author:** Ranjana W. Minz, Department of Immunopathology, Post Graduate Institute of Medical Education and Research (PGIMER), India.  
E-mail: [rwminz.minz88@gmail.com](mailto:rwminz.minz88@gmail.com)

#### References

1. Kissmeyer-Nielsen F, Steen Olsen V, Posborg Petersen, Fjeldborg O. Hyperacute rejection of kidney allografts, associated with pre-existing humoral antibodies against donor cells. *Lancet* 1966;2:662–5.
2. McCaughan J, Xu Q, Tinckam K. Detecting Donor-Specific Antibodies: the Importance of sorting the wheat from the chaff. *Hepatobiliary Surg Nutr* 2019;8:37.
3. Mishra VC, Chandra D, Anthwal A, Bhardwaj AK, Raina V. Positive single-antigen bead assay with negative flow crossmatch in a renal transplant-A case report. *Indian J Transplant* 2022;16:425–7.
4. Pandey S, Harville TO. Epitope analysis aids in transplant decision making by determining the clinical relevance of apparent pre-transplant donor specific antibodies (DSA). *Ann Clin Lab Sci* 2019;49:50–6.

This is an open access journal, and articles are distributed under the terms of the Creative Commons Attribution-NonCommercial-ShareAlike 4.0 License, which allows others to remix, transform, and build upon the work non-commercially, as long as appropriate credit is given and the new creations are licensed under the identical terms.

**How to cite this article:** Rani L, Aggarwal R, Kumar M, Ramachandran R, Sharma A, Minz RW. Strategies to Circumvent Discrepancies in Pre-Transplant Donor Specific Antibodies Workup. *Indian J Nephrol*. 2025;35:309-10. doi:10.25259/IJN\_60\_2024

Received: 06-02-2024; Accepted: 08-02-2024;  
Online First: 10-06-2024; Published: 25-02-2025

DOI: 10.25259/IJN\_60\_2024



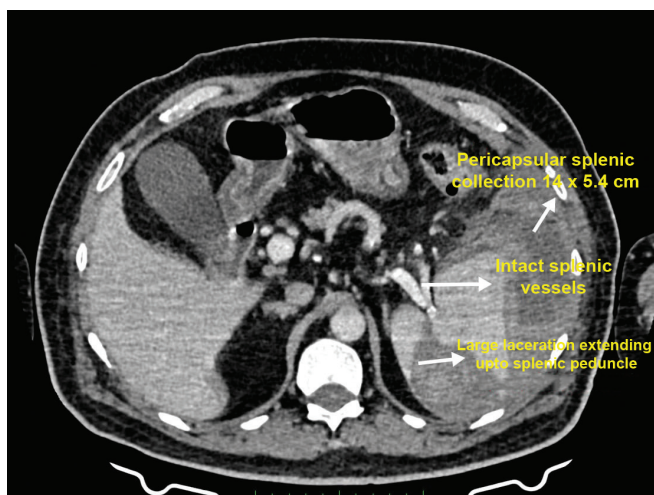
## Conservatively Managed Spontaneous Splenic Rupture in a Hemodialysis Patient

Dear Editor,

A 68-year-old diabetic male with 8-year dialysis vintage reported to Emergency room in March 2023, with a 4-day history of pain left upper abdomen radiating to the left shoulder (Kehr's sign). He appeared anxious with BP of 100/70 mm HG and pulse of 96/min. On examination, there was tenderness and guarding in the left hypochondrium. His hemoglobin was 9.6 g/dl and was leucocyte count was 13,900/cmm. USS showed large tear with a hematoma in the spleen and CT confirmed Class 3 tear (moderate–severe) with hematoma [Figure 1]. Other relevant investigations were negative. As the patient was hemodynamically stable, it was decided to manage him conservatively with close hemodynamic observation, bed rest and avoidance

of anticoagulants (during HD) and antiplatelet drugs. Ambulation was started after a week and heparin was reintroduced after 2 weeks. The patient recovered smoothly. Appropriate patient consent was obtained.

Splenic tear usually results following road traffic accident or trauma. Spontaneous splenic rupture (SSR) is rarely reported. Liu *et al.* in a series of 251 cases of ruptured spleen found 8 cases of SSR (3.2%).<sup>1</sup> In an analysis of risk factors in 848 reported cases of SSR over 28 years, Renzulli *et al.*<sup>2</sup> found underlying neoplasm (30.3%), infection (27.3%) or non-infectious causes (20.0%), and drug-/treatment-related (6.8%) causes as possible risk factors. Management included splenectomy in 84.1% of cases. As per ASST classification, our patient had moderate–severe injury.<sup>3</sup>



**Figure 1:** Large laceration extending up to the splenic peduncle. Distorted spleen with heterogenous hyperdense pericapsular splenic collection (14 cm × 5.4 cm).

There are less than 15 case reports of SSR in dialysis patients and all cases underwent splenectomy.<sup>4,5</sup> Our patient is the first case to be successfully managed conservatively. Uremic coagulopathy, the use of antiplatelet drugs and anticoagulants are possible risk factor in such patients. Because of the rarity of cases, there is no laid down management guideline. This report underscores two points: Spontaneous splenic rupture can present subacutely in dialysis patients, and conservative management can be an option for moderate-severe injuries in hemodynamically stable patients.

**Conflicts of interest:** There are no conflicts of interest.

**Prem P. Varma<sup>1</sup>, Mehak Singla<sup>1</sup>, Shreya Saxena<sup>1</sup>**

<sup>1</sup>Department of Nephrology, Primus Super Specialty Hospital, New Delhi, India

**Corresponding author:**

Prem Varma, Department of Nephrology, Primus Hospital, New Delhi, India. E-mail: varmapp123@rediffmail.com

## References

1. Liu J, Feng Y, Li A, Liu C, Li F. Diagnosis and treatment of a traumatic splenic rupture: experience of 8 cases. *Gastroenterol Res Pract* 2019;2019:582769.
2. Renzulli P, Hostettler A, Schoepfer AM, Gloor B, Candinas D. Systematic review of atraumatic splenic rupture. *Br J Surg* 2009;96:1114-21.
3. Waseem M, Bjerke S. Splenic Injury. (Updated 2023 Jan 30) In: *Stat Pearls*. Treasure Island (FL): Stat Pearls Publishing; 2024 Jan
4. Pandiaraja J. Spontaneous splenic haematoma in a patient on hemodialysis: A case report. *Indian J Nephrol* 2017;27:475-4
5. Ahbala T, Rabbani K, Louzi A, Finech B. Spontaneous splenic rupture: Case report and review of literature. *Pan Afr Med J* 2020;37:36.

This is an open access journal, and articles are distributed under the terms of the Creative Commons Attribution-NonCommercial-ShareAlike 4.0 License, which allows others to remix, transform, and build upon the work non-commercially, as long as appropriate credit is given and the new creations are licensed under the identical terms.

**How to cite this article:** Varma PP, Singla M, Saxena S. Conservatively Managed Spontaneous Splenic Rupture in a Hemodialysis Patient. *Indian J Nephrol*. 2025;35:310-1. doi: 10.25259/IJN\_134\_2024

**Received:** 21-03-2024; **Accepted:** 21-04-2024;  
**Online First:** 22-07-2024; **Published:** 25-02-2025

**DOI:** 10.25259/IJN\_134\_2024

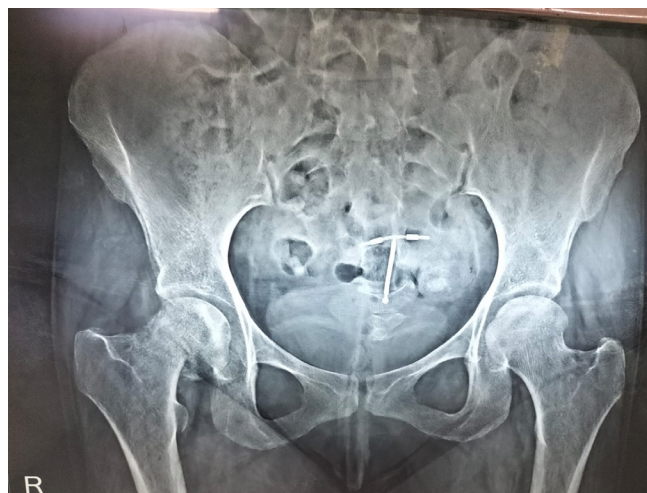


## Tenofovir-Induced Fanconi Syndrome Associated with a Fragility Fracture of the Right Femoral Neck

Dear Editor,

Fanconi syndrome is a metabolic defect in renal transport caused by proximal tubular cell dysfunction. It impairs the reabsorption of water, glucose, phosphate, potassium, amino acids, and other substances.<sup>1</sup> We present a case of renal dysfunction and osteoporosis associated with tenofovir use.

A 36-year-old female, a known case of HIV-1 since 2005, presented with complaints of proximal muscle weakness, muscle pain, and pain in the right hip joint for the past two months, with history of slipping on the floor four months ago. She had been taking a combination of tenofovir, lamivudine, ritonavir, and atazanavir for the past two years. She was diagnosed with a malunited fracture of the right femoral neck [Figure 1]. She underwent evaluation for osteoporosis. Her hemoglobin was 9.0 g/dL, vitamin B12 912 pg/mL, urea 48 mg/



**Figure 1:** X ray imaging of the pelvis with bilateral hip joint showing fracture in the right neck of the femur.