



## Successful Management of Adenine Phosphoribosyl Transferase Enzyme Deficiency in Renal Transplantation: A Case Report

### Abstract

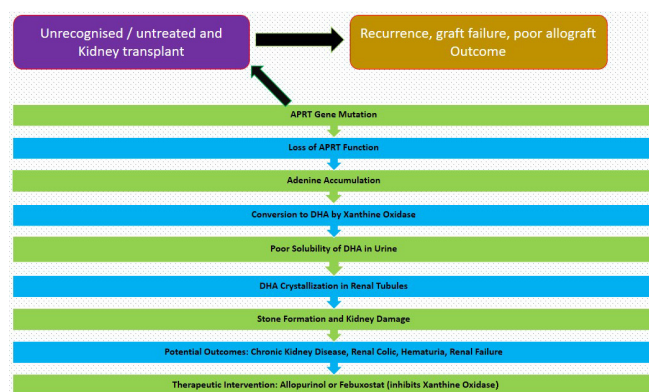
Adenine phosphoribosyltransferase (APRT) enzyme deficiency is a rare inborn metabolic error causing an accumulation of 2,8 dihydroxyadenine (DHA), leading to kidney stones and crystal nephropathy. If untreated, it progresses to end stage renal disease (ESRD) with a subsequent risk of crystal nephropathy recurrence post-renal transplantation. Recurrence post-transplant can be prevented, and allograft outcomes can be improved if treatment with an xanthine oxidoreductase (XOR) inhibitor is initiated before or at the time of kidney transplantation. We describe a case involving a 24-year-old male with ESRD, found to have APRT enzyme deficiency during transplant evaluation, successfully managed with pre- and post-transplant XOR inhibitors to prevent recurrence, resulting in a positive allograft outcome.

**Keywords:** APRT deficiency, XOR inhibitor, Renal failure, Recurrence, DHA crystals

### Introduction

Adenine phosphoribosyltransferase (APRT) deficiency (OMIM 102600) is a rare autosomal recessive disorder impacting purine metabolism, linked to the APRT gene on chromosome 16 (16q24).<sup>1</sup> It results in the formation of 2,8-dihydroxyadenine (DHA) stones, which are insoluble in urine at normal pH levels, leading to recurrent kidney stones and kidney damage. Clinical manifestations include renal colic, hematuria, urinary tract infections (UTIs), and kidney failure, with symptom onset ranging from infancy to later in life. Approximately 50% of those with APRT deficiency are asymptomatic.

Diagnosis is challenging due to the stones' radiographic invisibility and the inability of routine tests to distinguish between DHA and uric acid stones. Accurate diagnosis involves stone analysis, identifying DHA crystals in urine or kidney biopsies, and assessing APRT enzyme activity in red blood cells. Treatment includes allopurinol, high fluid intake, and a low-purine diet. Urine alkalization is ineffective due to DHA's insolubility across different pH levels [Figure 1]. The disease can recur in transplanted kidneys.



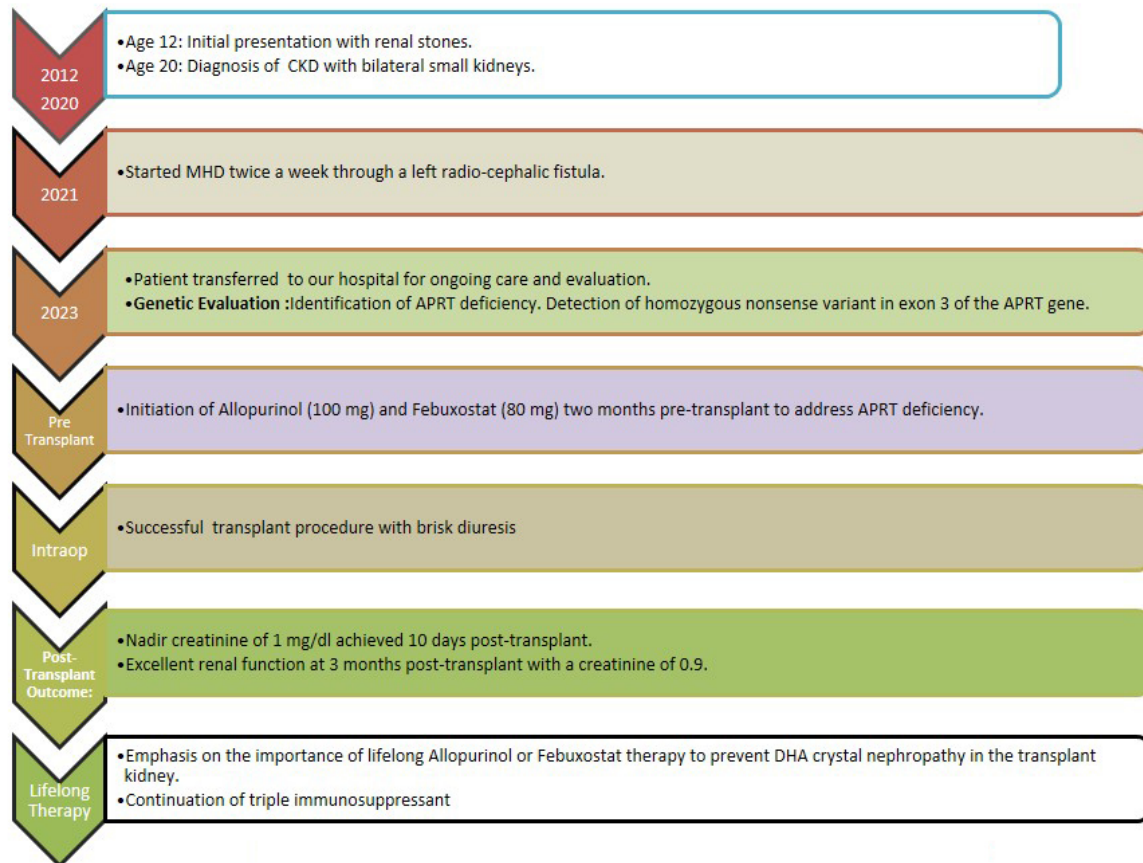
**Figure 1:** APRT deficiency. APRT: Adenine phosphoribosyltransferase, DHA: Dihydroxyadenine.

### Case Report

A 24-year-old male, born from a consanguineous marriage, first presented with symptoms indicative of renal stones (flank pain and hematuria) at the age of 12. Conservative management was adopted, including increased hydration, dietary modifications, and pain management. No further diagnostic evaluations or follow-up imaging were pursued, and the patient did not report any recurrent stone episodes.

By the age of 20, he was diagnosed with chronic kidney disease. Over the next 4 years, the kidney disease progressed, and he was initiated maintenance hemodialysis (MHD). He came to us for kidney transplantation 2 years later. No significant involvement of other organ systems was observed throughout his clinical course. During the pre-transplant evaluation, the patient was diagnosed with hypothyroidism. The genetic evaluation was initially aimed at identifying possible primary oxalosis. However, the results indicated a homozygous nonsense mutation in exon 3 of the APRT gene (chr16:g.88810545G>A; Depth: 117x), which leads to a stop codon and premature truncation of the protein at codon 67 (p.Arg67Ter; ENST00000378364.8) [Figure 2]. This genetic variant was absent in major genomic databases like the 1000 Genomes, gnomAD (v3.1), and gnomAD (v2.1). However, it showed minor allele frequencies of 0.00076% and 0.00231% in the TopMed and the databases of MedGenome Laboratories, respectively. This mutation had been identified in one other reported case of APRT deficiency.<sup>2</sup> Urinalysis was not possible due to anuria.

He was started on allopurinol (100 mg) and febuxostat (80 mg) and received a kidney transplant from his mother. He was induced with basiliximab 20 mg and received standard triple drug immunosuppression. Prompt diuresis was achieved and the serum creatinine levels declined to 1 mg/dl at 10 days. Three months following the transplant, his serum creatinine was 0.9.



**Figure 2:** Journey from renal stones to renal transplantation. CKD: chronic kidney disease, MHD: maintenance hemodialysis, APRT: adenine phosphoribosyl transferase enzyme, DHA: dihydroxyadenine

## Discussion

APRT deficiency, identified in diverse global populations, is often underdiagnosed, leading to missed therapeutic opportunities. The aggressive nature of DHA crystal-induced injury is notably more pronounced in kidney allografts.<sup>3</sup> The role of xanthine oxidoreductase (XOR) inhibitors in preventing DHA crystal nephropathy posttransplant is an area of limited data. The largest case series<sup>4</sup> documented the disease recurrence in allograft biopsies from patients without adequate pretransplant XOR inhibitor treatment. Use of allopurinol 300 mg or more daily was able to prevent DHA nephropathy in transplant recipients. Patients on XOR inhibitor therapy at the time of kidney transplantation and continued this treatment through the posttransplant period had superior allograft outcomes.

This case represents the second instance in India with a pretransplant APRT deficiency diagnosis and underscores the importance of early diagnosis and initiation of XOR inhibitors like febuxostat before transplantation.

While allopurinol’s safety in CKD stage 3 and beyond is not extensively studied, febuxostat’s safety has been demonstrated in observational studies.<sup>5</sup> This case highlights the effectiveness of proactive treatment strategies in

preventing DHA nephropathy recurrence posttransplant and the necessity of comprehensive genetic testing for accurate diagnosis in atypical cases, emphasizing the complexities of identifying rare genetic conditions.

## Conclusion

This case highlights the effectiveness of proactive treatment strategies in preventing DHA nephropathy recurrence post transplant and the necessity of comprehensive genetic testing for accurate diagnosis in atypical cases, emphasizing th complexities of identifying rare genetic conditions.

## Declaration of patient consent

The authors certify that they have obtained all appropriate patient consent.

## Conflicts of interest

There are no conflicts of interest.

**Praveen Vijaykumar Malavade<sup>1</sup>**

<sup>1</sup>Department of Nephrology, NEPHROURO (NU) Hospitals, Shivamogga, Karnataka, India

**Corresponding author:**

Praveen Vijaykumar Malavade, Department of Nephrology, NEPHROURO (NU) Hospitals, Shivamogga, Karnataka, India.  
E-mail: malvadepraveen3@gmail.com

## References

1. Amberger J, Bocchini CA, Scott AF, Hamosh A. McKusick's online mendelian inheritance in man (OMIM). *Nucleic Acids Res* 2009;37:D793-6.
2. Bollée G, Dollinger C, Boutaud L, Guillemot D, Bensman A, *et al.* Phenotype and genotype characterization of adenine phosphoribosyltransferase deficiency. *J Am Soc Nephrol* 2010;21:679-88.
3. Runolfsdottir HL, Pálsson R, Agustsdóttir IM, Indridason OS, Edvardsson VO. Kidney disease in adenine phosphoribosyltransferase deficiency. *Am J Kidney Dis* 2016;67:431-8.
4. Runolfsdottir HL, Pálsson R, Agustsdóttir IMS, Indridason OS, Li J, Dao M, *et al.* Kidney transplant outcomes in patients with adenine phosphoribosyltransferase deficiency. *Transplantation* 2020;104:2120-8.
5. Jeong HJ, Park WY, Kim SH, Dalbeth N, Son CN. Urate-lowering efficacy and renal safety of febuxostat in patients with hyperuricemia and stage 4-5 chronic kidney disease not yet on dialysis: A meta-analysis of observational studies. *Semin Arthritis Rheum* 2022 Oct;56:152073.

This is an open access journal, and articles are distributed under the terms of the Creative Commons Attribution-NonCommercial-ShareAlike 4.0 License, which allows others to remix, tweak, and build upon the work non-commercially, as long as appropriate credit is given and the new creations are licensed under the identical terms.

**How to cite this article:** Malavade PV. Successful Management of Adenine Phosphoribosyl Transferase Enzyme Deficiency in Renal Transplantation: A Case Report. *Indian J Nephrol.* 2024;34:383-5. doi: 10.25259/IJN\_167\_2024

**Received:** 09-04-2024; **Accepted:** 01-05-2024  
**Online First:** 17-06-2024; **Published:** 20-07-2024

**DOI:** 10.25259/ijn\_167\_2024



## Filariasis-Associated Secondary Membranous Nephropathy: A Rare Presentation

### Abstract

Parasitic infections like filariasis are uncommon causes of secondary membranous nephropathy (MN) which requires serological tests to detect circulating *Wuchereria bancrofti* antigens for its diagnosis or the identification of microfilariae in the capillary lumen on kidney biopsy. The immunochromatographic card tests is simple, non invasive and has high sensitivity and specificity. We report a case of 30 year old lady who presented to us with nephrotic syndrome which on kidney biopsy showed features of membranous nephropathy with negative staining for Anti PLA2R , THSD7A and exostosin. A thorough workup was done to find out any secondary cause of MN where she was found positive with filarial antibody test. Hence, a diagnosis of secondary membranous pattern nephropathy was considered for which she was treated with diethylcarbamazine (DEC) and other supportive medications which on follow up showed marked resolution of proteinuria.

**Keywords:** Secondary membranous nephropathy, Nephrotic syndrome, Filariasis

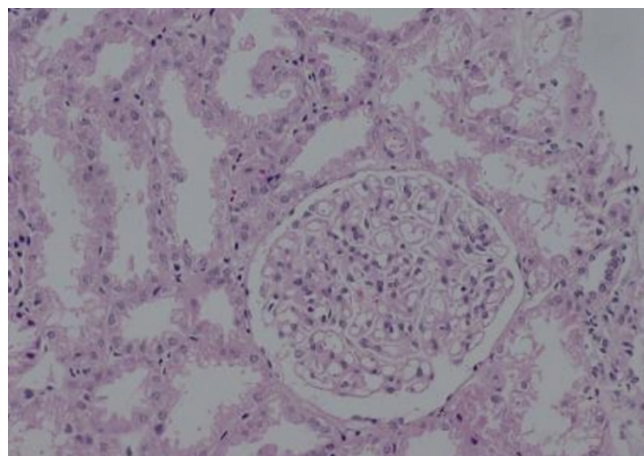
### Introduction

Filariasis is a major health problem in the developing parts of the world such as Africa, Southeast Asia, and South America. India contributes to approximately 40% of the total global clinical burden. The disease is predominantly caused by the parasites *Wuchereria bancrofti* and *Brugia malayi*, which get transmitted through mosquito bite. The most common clinical features due to lymphatic obstruction are chyluria, hydrocoele, lymphedema, and elephantiasis.<sup>1,2</sup> The histopathological lesions on kidney biopsy in filariasis are membranoproliferative (MPGN) and mesangioproliferative glomerulonephritis, and membranous pattern nephropathy (MN) is seen rarely.<sup>3</sup> We present a case of a 30-year-old lady with nephrotic syndrome, which on kidney biopsy showed features of MN. She was found positive for filarial antibody was treated with diethylcarbamazine (DEC) and showed marked resolution of proteinuria.

### Case Report

A 30-year-old lady presented with facial puffiness and lower-limb swelling for 1 month. She had bilateral pitting pretibial edema, and her BP was 120/90 mm Hg; the

rest of the examination was unremarkable. Laboratory tests showed Hb 14.3 g/dL, WBC 8240/mm<sup>3</sup>, platelets 2.43/mm<sup>3</sup>, eosinophil count 4.4%, blood urea 21 mg/dL, creatinine 0.65 mg/dL, uric acid 7.4 mg/dL, total protein 6.4 g/dL, serum albumin 2.6 g/dL, triglyceride 483 mg/dL, total cholesterol 235 mg/dL, blood sugars 112 mg/dL, and TSH 8.65 mIU/L. Serology for hepatitis B surface antigen,



**Figure 1:** Light microscopy showing diffuse thickening of capillaries with altered membrane texture (Periodic Acid-Schiff reaction × 400).