

Pseudo-arterial Temporary Hemodialysis Catheter Placement in the Left Internal Jugular Vein Ipsilateral to a Preexisting Brachio-axillary Arteriovenous Graft

Abstract

Internal jugular vein (IJV) cannulation was originally described by English *et al.* in 1969 as the safest approach. Carotid artery puncture had an incidence rate of 4–6% before ultrasound guidance. We encountered an unexpected sequence of events following the ultrasound-guided placement of a temporary HD catheter in the left IJV. The postprocedure chest radiograph was misinterpreted as an arterial misplacement, the blood return was correspondingly bright red, and simultaneous blood gas analyses from the left IJV catheter and a right radial artery were near mirror images. Subsequently, a transducer to the catheter showed a clearly venous waveform with a pressure of 40 mmHg. Thus, it was realized that the cacophony of missteps, misjudgments, and misinterpretations was due to the contiguous presence of a functional left brachio-axillary arteriovenous (AV) graft. To our knowledge, this is the first such report of this phenomenon of a pseudo-arterial central venous catheter placement in the IJV.

Keywords: Arterial blood gas analysis, carotid artery puncture, hemodialysis catheter, internal jugular vein, ultrasound-guided placement

Introduction

Critically ill patients often require renal replacement therapy (RRT) for severe electrolyte derangements, acidemia, uremia, and volume overload. Urgent or emergent vascular access for RRT demands the placement of temporary dual lumen hemodialysis catheters in large central veins. The cannulation of the internal jugular vein (IJV) for vascular access was originally described by English *et al.* in 1969 as safer than femoral, subclavian, or antecubital veins.^[1] Carotid artery puncture, which can be fatal, had an incidence rate of about 4–6% prior to the introduction of ultrasound guidance.^[2] The subsequent introduction of real-time ultrasound guidance to further enhance the safety of this procedure followed later.^[3–6] Ultrasound guidance has reduced the rate of procedure-related complications from 5.9% to as low as 0.8%.^[2,7] Ultrasound-guided placement of central venous catheters (CVC) is now the standard of practice in contemporary nephrology care.^[4–6] Furthermore, continuous renal replacement

therapy (CRRT) using a preexisting arteriovenous fistula or graft (AVF or AVG) increases the risks for access complications including needle dislodgement, bleeding, thrombosis, and long-term fistula, or graft complications stemming from continuous needle trauma.^[8] Hence in such settings, a new temporary HD catheter is usually deployed.^[8] We recently encountered a peculiar sequence of unexpected events after an ultrasound-guided placement of a dual lumen temporary HD catheter in the left IJV for urgent vascular access.

Case Report

A 69-year-old black male patient had been on maintenance outpatient in-center hemodialysis for end-stage renal disease from hypertensive nephrosclerosis via a left upper extremity brachio-axillary polytetrafluoroethylene AV graft since May 2015. He was delisted from the kidney transplant list in the summer of 2018 due to worsening dyspnea. Evaluation of the dyspnea confirmed the presence of severe mitral valve incompetence with regurgitation, pulmonary hypertension with pulmonary artery pressures measured in

**Macaulay Amechi
Chukwukadibia
Onuigbo,
Nneoma Agbasi¹,
Bibek Sarki,
Sana Khan,
Kramer Wahlberg**

*The Robert Larner, M.D.
College of Medicine,
Department of Medicine,
University of Vermont,
Burlington, VT, ¹Quality
Improvement Programme,
NELF NHS Foundation Trust,
Basildon, Essex, UK*

Received: 21-12-2018

Revised: 16-01-2019

Accepted: 15-02-2019

Published: 27-12-2019

Address for correspondence:

*Dr. Macaulay Amechi
Chukwukadibia Onuigbo,
Division of Nephrology,
Department of Medicine, The
Robert Larner, M.D. College
of Medicine, University of
Vermont, UHC Campus,
1 South Prospect Street,
Burlington, VT 05401, USA.
E-mail: macaulay.onuigbo@
uvmhealth.org*

Access this article online

Website: www.indianj nephrol.org

DOI: 10.4103/ijn.IJN_389_18

Quick Response Code:



How to cite this article: Onuigbo MA, Agbasi N, Sarki B, Khan S, Wahlberg K. Pseudo-arterial temporary hemodialysis catheter placement in the left internal jugular vein ipsilateral to a preexisting brachio-axillary arteriovenous graft. *Indian J Nephrol* 2020;30:29-31.

This is an open access journal, and articles are distributed under the terms of the Creative Commons Attribution-NonCommercial-ShareAlike 4.0 License, which allows others to remix, tweak, and build upon the work non-commercially, as long as appropriate credit is given and the new creations are licensed under the identical terms.

For reprints contact: reprints@medknow.com

excess of 50 mmHg, and mildly reduced right ventricular systolic function. He underwent open mitral valve replacement with implantation of a St. Jude Medical Epic bioprosthetic mitral valve. A right IJV triple-lumen CVC was placed in the operating room (OR) preoperatively for vascular access without any complications. Cardiopulmonary bypass included 76 min of pump time. He received 1 L of del Nido cardioplegia and 500 mL of Ringer’s lactate with 0 mL of urine output in the OR. Intraoperative transesophageal echocardiography confirmed a normally situated and functioning mitral valve prosthesis without evidence of perivalvular leak or stenosis.

Postoperatively, he was transferred to the surgical intensive care unit (SICU) on vasopressor support with phenylephrine. Immediate postoperative laboratory indices were potassium 5.6 mEq/L, CO₂ 22 mEq/L, chloride 103 mEq/L, BUN 53 mg/dL, hemoglobin 9.0 g/dL, platelets 97,000/mL, and INR 1.1. After about 7 h, in the SICU, a follow-up potassium was severely elevated at 8.7 mEq/L. He remained otherwise stable while still requiring vasopressor support. Nephrology follow-up recommended emergent CRRT for potentially life-threatening hyperkalemia. With a CVC already in the right IJV, the decision was made to place a temporary HD catheter in the left IJV for vascular access for CRRT.^[8] A 14-Fr 15-cm double-lumen catheter was placed in the left IJV under ultrasound guidance, secured at 13 cm at the surface of the skin. Blood return from the catheter lumen was observed to be bright red in color, with no observations documented regarding the pulsatile nature or otherwise of flow out of the access needle. A postplacement chest radiograph was interpreted as “concern for arterial placement” with the “tip positioned below the expected contour of the brachiocephalic [vein]” [Figure 1]. A subsequent blood gas analysis on blood drawn from the newly placed left IJV catheter revealed a pH of 7.31, pCO₂ of 40 mmHg, and pO₂ 88 of mmHg. Given that this analysis appeared to represent arterial blood, a separate blood gas analysis was immediately completed on blood drawn from the patient’s right radial artery. The right radial artery blood gas analysis showed a pH of 7.32, pCO₂ of 40 mmHg, and pO₂ of 92 mmHg. The near match of the two concurrently drawn blood gas analyses only further heightened the concern that the left-sided IJV catheter

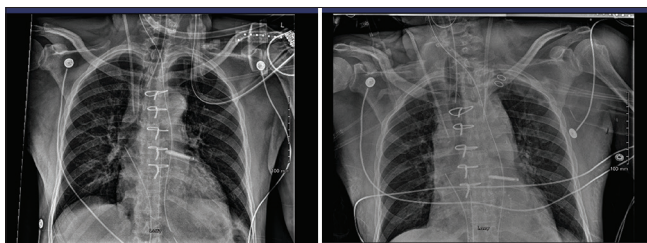


Figure 1: Chest radiographs showing the right internal jugular vein catheter placement in the OR (left) and the subsequent left internal jugular vein catheter placement postoperatively in the SICU (right)

had indeed been inadvertently misplaced in the arterial system [Figure 2]. This observation, taken together with the bright red color of the aspirated blood from the left IJV catheter and the concurrent reading of the postprocedure chest radiograph by radiology, triggered an urgent vascular surgery consultation. The left IJV catheter was left in place. Vascular surgery planned to discontinue the catheter in the OR the following morning. In the interim, CRRT was initiated via a newly placed left femoral vein dual lumen dialysis catheter.

In the morning, just before OR time, a transducer was connected to the left IJV catheter and the pressure was 40 mmHg with a clearly venous waveform. At this point, the realization was made that the cacophony of missteps, misjudgments, and misinterpretations associated with the left IJV catheter placement would be explained by the contiguous presence of a functional left brachio-axillary AV graft. CRRT was subsequently continued via the left IJV catheter without any complications. The left femoral vein was soon discontinued.

Discussion

To the best of our knowledge, this is the first reported case of the ultrasound-guided placement of a left IJV CVC on the same side as a native AVF/AVG leading to confusion for inadvertent arterial puncture.^[2,7]

Several concomitant factors contributed to this unique sequence of observations reported here. The patient already had a CVC placed preoperatively in the right IJV, and given the rationale to avoid the use of the left upper extremity AV graft for CRRT, the placement of a left IJV HD catheter was therefore indicated.^[8] Furthermore, the left IJV catheter was only 15 cm in length, and therefore, the catheter tip terminated in the left brachiocephalic vein as it could not cross the midline to end in the area of the superior vena cava as would typically be expected [Figure 1]. This must have precipitated the radiology misinterpretation of an

10/30/2018 2309	10/30/2018 2333
96	96
7.31 ▼	7.32 ▼
40	40
88	92
22 ▼	22 ▼
VENOUS	ARTERIAL
5	5

Figure 2: Concurrent left internal jugular venous blood gas analysis demonstrating a near-mirror image with a simultaneously drawn right radial arterial blood gas analysis

arterial misplacement. Besides, the visualization of bright red blood return during catheter placement only further validated the fear of an arterial misplacement of the catheter. Moreover, the near match of the left IJV blood gas analysis and the simultaneously drawn right radial artery blood gas analysis corroborated the fear of arterial catheter misplacement [Figure 2]. This phenomenon of matching venous and arterial blood gas analyses, we now in retrospect surmise, was due to the combination of the presence of a functional left upper extremity brachio-axillary AVG on the ipsilateral side of the left IJV catheter, leading to blood flow through the venous system with an “arterial” fingerprint, together with the relatively short length of the left IJV catheter.^[7,9] Ultimately, the utilization of a pressure transducer confirmed the proper placement of the catheter in the venous system, itself a reliable and easy method to troubleshoot a possible inadvertent arterial stick. This pressure transducer maneuver actually spared the patient an unnecessary trip back to the OR with vascular surgery for an arterial catheter extraction. We herein posit that one other theoretical ploy to further troubleshoot and clarify venous catheter placement in such a scenario in the future is as follows: measure a baseline blood gas analysis from the left IJV catheter, then compress the feeding AVF/AVG for about 30 s, and then repeat a postcompression blood gas analysis from the left IJV catheter. We hypothesize that the postcompression blood gas analysis data would be more representative of only venous blood flow after the AV shunt had been temporarily shut down and therefore show a venous “footprint,” no pawn intended.

This case illustrates a rare complication of temporary HD catheter placement that occurred in the context of the concurrent placement of a CVC on the ipsilateral side of a functional brachio-axillary AV graft. Finally, it is important to recognize that a blood gas analysis from a sample obtained from such a catheter may be skewed due to the presence of arterial blood mixture through the arteriovenous shunt.

Arguably, a right IJV triple lumen dialysis catheter could have been easily exchanged over a guidewire to have a triple-lumen nontunneled dialysis catheter. However, our experience has been that such triple lumen nontunneled dialysis catheters are not as functionally reliable as regular dual-lumen dialysis catheters, and there are some concerns about increased infections with their use.^[10,11] Nontunneled dialysis catheters come in lengths ranging from 9 to 30 cm. Arguably, if a >20-cm catheter was used on the left IJV in our patient, many of the missteps, misjudgments, and misinterpretations would have been avoided. There is in fact evidence in the literature that the use of the left IJV for CVC placement can cause difficulties during insertion and has a higher incidence of catheter dysfunction, particularly with nontunneled catheters.^[12]

In retrospect, all the tests described should have been done when the confusion was discovered rather than calling vascular surgery. This is a bedside learning point.

To our knowledge, this is the first such report of a pseudo-arterial placement of a CVC in a large central vein.

Declaration of patient consent

The authors certify that they have obtained all appropriate patient consent forms. In the form the patient(s) has/have given his/her/their consent for his/her/their images and other clinical information to be reported in the journal. The patients understand that their names and initials will not be published and due efforts will be made to conceal their identity, but anonymity cannot be guaranteed.

Financial support and sponsorship

Nil.

Conflicts of interest

There are no conflicts of interest.

References

1. English IC, Frew RM, Pigott JF, Zaki M. Percutaneous catheterisation of the internal jugular vein. *Anaesthesia* 1969;24:521-31.
2. Jobes DR, Schwartz AJ, Greenhow DE, Stephenson LW, Ellison N. Safer jugular vein cannulation: Recognition of arterial puncture and preferential use of the external jugular route. *Anesthesiology* 1983;59:353-5.
3. Hind D, Calvert N, McWilliams R, Davidson A, Paisley S, Beverley C, Thomas S. Ultrasonic locating devices for central venous cannulation: Meta-analysis. *BMJ* 2003;327:361.
4. Slama M, Novara A, Safavian A, Ossart M, Safar M, Fagon JY. Improvement of internal jugular vein cannulation using an ultrasound-guided technique. *Intensive Care Med* 1997;23:916-9.
5. Srinivasan S, Govil D, Gupta S, Patel S, Jagadeesh KN, Tomar DS. Incidence of posterior wall penetration during internal jugular vein cannulation: A comparison of two techniques using real-time ultrasound. *Indian J Anaesth* 2017;61:240-4.
6. Denys BG, Uretsky BF, Reddy PS. Ultrasound-assisted cannulation of the internal jugular vein. A prospective comparison to the external landmark-guided technique. *Circulation* 1993;87:1557-62.
7. Bour ES, Weaver AS, Yang HC, Gifford RR. Experience with the double lumen Silastic catheter for hemoaccess. *Surg Gynecol Obstet* 1990;171:33-9.
8. Vijayan A. Vascular access for continuous renal replacement therapy. *Semin Dial* 2009;22:133-6.
9. Wadelek J. Haemodialysis catheters. *Anestezjol Intens Ter* 2010;42:213-7.
10. Hilton E, Haslett TM, Borenstein MT, Tucci V, Isenberg HD, Singer C. Central catheter infections: Single- versus triple-lumen catheters. Influence of guide wires on infection rates when used for replacement of catheters. *Am J Med* 1988;84:667-72.
11. Grishaber JE, Cunningham MC, Rohret PA, Strauss RG. Analysis of venous access for therapeutic plasma exchange in patients with neurological disease. *J Clin Apher* 1992;7:119-23.
12. Engstrom BI, Horvath JJ, Stewart JK, Sydnor RH, Miller MJ, Smith TP, Kim CY. Tunneled internal jugular hemodialysis catheters: Impact of laterality and tip position on catheter dysfunction and infection rates. *J Vasc Interv Radiol* 2013;24:1295-302.