



Conservatively Managed Spontaneous Splenic Rupture in a Hemodialysis Patient

Dear Editor,

A 68-year-old diabetic male with 8-year dialysis vintage reported to Emergency room in March 2023, with a 4-day history of pain left upper abdomen radiating to the left shoulder (Kehr's sign). He appeared anxious with BP of 100/70 mm HG and pulse of 96/min. On examination, there was tenderness and guarding in the left hypochondrium. His hemoglobin was 9.6 g/dl and was leucocyte count was 13,900/cmm. USS showed large tear with a hematoma in the spleen and CT confirmed Class 3 tear (moderate–severe) with hematoma [Figure 1]. Other relevant investigations were negative. As the patient was hemodynamically stable, it was decided to manage him conservatively with close hemodynamic observation, bed rest and avoidance of anticoagulants (during HD) and antiplatelet drugs. Ambulation was started after a week and heparin was reintroduced after 2 weeks. The patient recovered smoothly. Appropriate patient consent was obtained.

Splenic tear usually results following road traffic accident or trauma. Spontaneous splenic rupture (SSR) is rarely reported. Liu *et al.* in a series of 251 cases of ruptured spleen found 8 cases of SSR (3.2%).¹ In an analysis of risk factors in 848 reported cases of SSR over 28 years, Renzulli *et al.*² found underlying neoplasm (30.3%), infection (27.3%) or non-infectious causes (20.0%), and drug-/treatment-related (6.8%) causes as possible risk factors. Management included splenectomy in 84.1% of cases. As

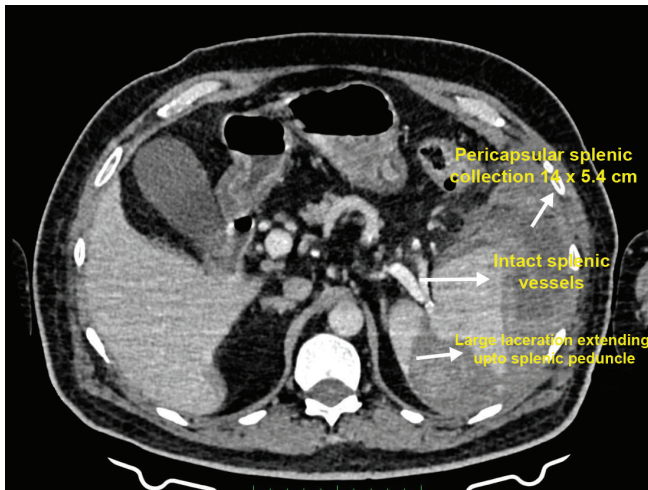


Figure 1: Large laceration extending up to the splenic peduncle. Distorted spleen with heterogeneous hyperdense pericapsular splenic collection (14 cm x 5.4 cm).

per ASST classification, our patient had moderate–severe injury.³

There are less than 15 case reports of SSR in dialysis patients and all cases underwent splenectomy.^{4,5} Our patient is the first case to be successfully managed conservatively. Uremic coagulopathy, the use of antiplatelet drugs and anticoagulants are possible risk factor in such patients. Because of the rarity of cases, there is no laid down management guideline. This report underscores two points: Spontaneous splenic rupture can present subacutely in dialysis patients, and conservative management can be an option for moderate-severe injuries in hemodynamically stable patients.

Conflicts of interest

There are no conflicts of interest.

Prem P. Varma¹, Mehak Singla¹, Shreya Saxena¹

¹Department of Nephrology, Primus Super Specialty Hospital, New Delhi, India

Corresponding author:

Prem Varma, Department of Nephrology, Primus Hospital, New Delhi, India. E-mail: varmapp123@rediffmail.com

References

1. Liu J, Feng Y, Li A, Liu C, Li F. Diagnosis and treatment of a traumatic splenic rupture: experience of 8 cases. *Gastroenterol Res Pract* 2019;2019:582769.
2. Renzulli P, Hostettler A, Schoepfer AM, Gloor B, Candinas D. Systematic review of atraumatic splenic rupture. *Br J Surg* 2009;96:1114-21
3. Waseem M, Bjerke S. Splenic Injury. (Updated 2023 Jan 30) In: *Stat Pearls*. Treasure Island (FL): Stat Pearls Publishing; 2024 Jan
4. Pandiaraja J. Spontaneous splenic haematoma in a patient on hemodialysis: A case report. *Indian J Nephrol* 2017;27:475-4
5. Ahbala T, Rabbani K, Louzi A, Finech B. Spontaneous splenic rupture: Case report and review of literature. *Pan Afr Med J* 2020;37:36.

This is an open access journal, and articles are distributed under the terms of the Creative Commons Attribution-NonCommercial-ShareAlike 4.0 License, which allows others to remix, tweak, and build upon the work non-commercially, as long as appropriate credit is given and the new creations are licensed under the identical terms.

How to cite this article: Varma PP, Singla M, Saxena S. Conservatively Managed Spontaneous Splenic Rupture in a Hemodialysis Patient. *Indian J Nephrol*. doi: 10.25259/IJN_134_2024

Received: 21-03-2024; Accepted: 21-04-2024;
Online First: 22-07-2024; Published: **-**-****

DOI: 10.25259/IJN_134_2024

