

Recombinant activated factor VII for diffuse alveolar hemorrhage in microscopic polyangiitis

S. K. Mandal, G. Sagar, M. Sahoo, S. Jasuja

Department of Nephrology, Indraprastha Apollo Hospital, New Delhi, India

ABSTRACT

Diffuse alveolar hemorrhage is a serious complication of the small vessel vasculitis syndromes and carries a high mortality. Recombinant activated factor VII (rFVIIa) is a powerful hemostatic agent developed for treatment of bleeding in patients with hemophilia and antibodies to factors VIII or IX. It has been used increasingly in life-threatening hemorrhage in a variety of other settings in which conventional medical or surgical therapy is unsuccessful. We report the successful use of rFVIIa for massive pulmonary hemorrhage in a patient of microscopic polyangiitis, which was later complicated by thrombotic microangiopathy and posterior reversible encephalopathy syndrome.

Key words: Diffuse alveolar hemorrhage, microscopic polyangiitis, posterior reversible encephalopathy syndrome, recombinant factor VIIa, thrombotic microangiopathy

Introduction

Microscopic polyangiitis is the most common cause for pulmonary-renal vasculitic syndrome. Renal presentation is in the form of rapidly progressive glomerulonephritis, histologically characterized by necrotizing, crescentic glomerulonephritis of pauci-immune type. Pulmonary involvement usually takes the form of diffuse alveolar hemorrhage (DAH) which is seen in 12 to 29%,^[1] with respiratory failure being a major complication. The conventional treatment of DAH involves a combination of systemic corticosteroids, cytotoxic medications, and plasmapheresis. However, some cases may be refractory to this regimen and have a high mortality rate of around 31%.^[1]

Recombinant factor VIIa is a vitamin K-dependent glycoprotein consisting of 406 amino acid residues and is structurally similar to human plasma derived factor VIIa.

Address for correspondence:

Dr. Sanjiv Jasuja, Department of Nephrology, Indraprastha Apollo Hospital, New Delhi, India. E-mail: dsjacedemics@yahoo.com

It promotes hemostasis by activating the extrinsic pathway of coagulation cascade. This report describes the successful use of recombinant activated factor VII (rFVIIa) for severe pulmonary hemorrhage in a case of microscopic polyangiitis.

Case Report

A 23-year-old woman presented to our hospital with one-month history of fever, loss of appetite, and fatigue. On evaluation, she was found to have advanced uremia (serum creatinine 9.8 mg/dl) and severe anemia (hemoglobin 5.2 g/dl). She was started on hemodialysis through internal jugular catheter and packed red cell transfusion was given. Further evaluation revealed active urinary sediments, normal-sized kidneys on ultrasound, and strongly positive myeloperoxidase-antineutrophilic cytoplasmic antibody (MPO-ANCA) (titer > 500 u/ml). Renal biopsy was done and treatment with pulse methyl prednisolone and oral cyclophosphamide was started. Renal biopsy revealed necrotizing glomerulonephritis with crescent formation of pauci-immune type with severe chronic glomerular and tubulointerstitial changes. Of 14 glomeruli, 11 were completely sclerosed [Figure 1].

On the sixth day of hospital stay, she developed sudden drop in hemoglobin along with dyspnea. Chest X-ray did not reveal any significant abnormality. Computerized tomography (CT) chest showed bilateral pleural effusion with ground glass and nodular opacities without

Access this article online	
Quick Response Code:	Website: www.indianjnephrol.org
	DOI: 10.4103/0971-4065.97134

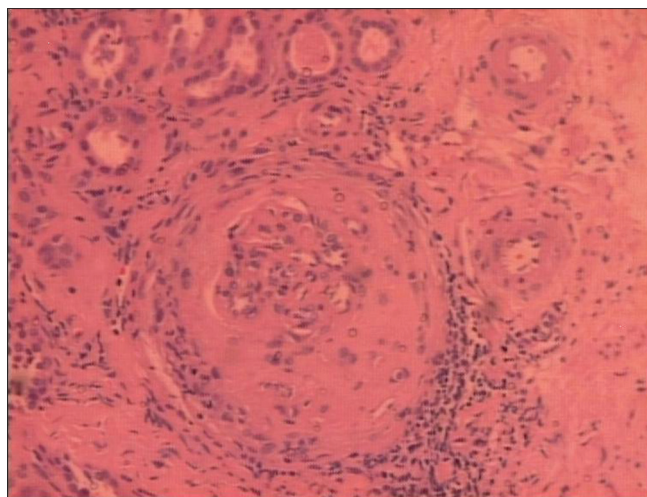


Figure 1: Section showing a glomerulus with fibro-epithelial crescent. Blood vessels in the vicinity showing medial and intimal thickening with surrounding interstitial fibrosis and tubular atrophy (H and E, ×220)

cavitary lesions. In the next 12 hours she developed respiratory distress, which necessitated mechanical ventilation. Bronchoscopy revealed diffuse hemorrhage. She was started on plasma exchange. However, her condition continued to deteriorate with continuous bleeding from the endotracheal tube and increasing oxygen requirements; hence, it was decided to use recombinant factor VII (Novoseven). She was given two doses of 90 µg/kg iv bolus at 2 hours interval. This therapy worked dramatically and within 30 minutes of first dose active bleeding stopped. She showed significant respiratory improvement in next 12 hours, and in 72 hours she could be extubated. Plasma exchange was continued and mycophenolate mofetil started. She received five sessions of plasma exchange.

During the hospital stay, she received heparin-free dialysis, antibiotics, prednisolone, and mycophenolate mofetil. However, her platelet counts showed a downward trend, evaluation of which revealed evidence of thrombotic microangiopathy (TMA) (fragmented red blood cells on peripheral smear, high lactate dehydrogenase - 3000 U/l, and normal PT). She was restarted with plasma exchange. She also had an episode of generalized tonic-clonic seizure. Magnetic resonance imaging (MRI) showed features suggestive of posterior reversible encephalopathy syndrome (PRES). She was started on levetiracetam. There was gradual improvement in her general condition and hematological parameters; she was discharged and put on maintenance hemodialysis program.

Discussion

Recombinant factor VIIa promotes hemostasis by activating the extrinsic coagulation pathway. It forms a

complex with tissue factor (TF) and activates factor X to Xa, as well as Factor IX to IXa. Factor Xa then converts prothrombin to thrombin, which forms a hemostatic plug by converting fibrinogen to fibrin. A therapeutic dose of FVIIa produces supraphysiological concentrations of FVIIa. This high concentration induces hemostasis by enhancing thrombin generation on the surface of activated platelets, thereby bypassing the traditional FVIIa/TF complex.^[2]

Although rFVIIa has been primarily used in patients with hemophilia A/B with Factor VIII or IX inhibitors, its use has been reported in patients with massive pulmonary hemorrhage in a variety of settings like very low birth weight infants,^[3] metastatic choriocarcinoma,^[4] pneumonia,^[5] and blunt thoracic trauma.^[6] Betensley and Yankaskas had earlier reported the use of rFVIIa in DAH due to microscopic polyangiitis with good result.^[7] Similarly, we found an almost immediate control of pulmonary hemorrhage after rFVIIa injection in the present case. Even intrapulmonary administration of rFVIIa through a bronchoscope has been reported to be effective in DAH.^[8,9]

Other unusual features in our case were the development of TMA and PRES. TMA complicating MPO-ANCA-associated vasculitis is rare and was reported by Yamauchi *et al.*, where it was treated with plasma exchange.^[10] We had restarted plasma exchange on finding the features of TMA in the present case and there was gradual improvement of her platelet counts.

PRES is an increasingly diagnosed neurologic disorder with characteristic CT and MRI findings. Classic CT findings are of bilaterally symmetric low attenuation in the posterior parietal and occipital lobes, whereas MRI demonstrates hyperintensity on T2-weighted images. PRES may develop in patients with renal insufficiency, hypertension, or who are on immunosuppressive medications and usually presents with headache, altered alertness, confusion, seizures, and cortical blindness.^[11]

Conclusion

This is an unusual case of microscopic polyangiitis with pauci-immune necrotizing glomerulonephritis and massive pulmonary hemorrhage, complicated by TMA and PRES. Use of rFVIIa helped in the rapid control of life-threatening pulmonary hemorrhage and allowed time for conventional therapy to act. Hence, recombinant factor VIIa may be considered as a treatment option in patients with diffuse pulmonary hemorrhage, who otherwise have a very high mortality rate.

References

1. Lauque D, Cadranet J, Lazor R, Pourrat J, Ronco P, Guillevin L, *et al.* Microscopic polyangiitis with alveolar hemorrhage: A study of 29 cases and review of the literature. *Medicine* 2000;79: 222-33.
2. Monroe DM, Hoffman M, Oliver JA, Roberts HR. Platelet activity of high-dose factor VIIa is independent of tissue factor. *Br J Haematol* 1997;99:542-7.
3. Olomu N, Kulkarni R, Manco-Johnson M. Treatment of severe pulmonary hemorrhage with recombinant factor VII (cFVIIa) in very low birth weight infants. *J Perinatol* 2002;22:672-4.
4. Wheeler MJ, Mead GM, Bhandari S, Fennell J. Recombinant factor VIIa in the management of pulmonary hemorrhage associated with metastatic choriocarcinoma. *J Clin Oncol* 2008;26:1008-10.
5. Macdonald JA, Fraser JF, Foot CL, Tran K. Successful use of recombinant factor VII in the treatment of massive hemoptysis due to community acquired pneumonia. *Chest* 2006;130:577-9.
6. Schreiber J, Lautenschlaeger F, Breuer S, Zagrodnick J, Kachel R, Schueck R. Treatment of diffuse pulmonary hemorrhage with factor VIIa. *Euro J Trauma Emerg Surg* 2008;34:315-8.
7. Betensley AD, Yankaskas JR. Factor VIIa in alveolar hemorrhage in microscopic polyangiitis. *Am J Respir Crit Care Med* 2002;166:1291-2.
8. Heslet L, Nielson JD, Levi M, Sengelov H, Johansson PI. Successful pulmonary administration of activated recombinant factor VII in diffuse alveolar hemorrhage. *Crit Care* 2006;10: R177.
9. Estella A, Jareño A, Perez-Bello Fontaiña L. Intrapulmonary administration of recombinant activated factor VII in diffuse alveolar hemorrhage: a report of two case stories. *Cases J* 2008;1:150.
10. Yamauchi Y, Nagatoya K, Okuno A, Fujii N, Inoue T. Successful treatment of thrombotic thrombocytopenic purpura complicated with myeloperoxidase anti-neutrophil cytoplasmic autoantibody-associated vasculitis. *NDT Plus* 2010; 3:279-81.
11. Hinchey J, Chaves C, Appignani B, Breen J, Pao L, Wang A, *et al.* A posterior reversible encephalopathy syndrome. *N Engl J Med* 1996;334:494-500.

How to cite this article: Mandal SK, Sagar G, Sahoo M, Jasuja S. Recombinant activated factor VII for diffuse alveolar hemorrhage in microscopic polyangiitis. *Indian J Nephrol* 2012;22:130-2.

Source of Support: Nil, **Conflict of Interest:** None declared.