

A Rare Association of Post-Streptococcal Uveitis and Post-Streptococcal Glomerulonephritis in a Child

Post streptococcal glomerulonephritis (PSGN) is one of the oldest renal diseases with significant changes in the epidemiology over the past three decades and new insight regarding the nephritogenic strains.^[1] Post-streptococcal uveitis (PSU) is a rare complication of prior streptococcal infection. Usually, PSU resolves with topical steroids with a good visual prognosis, but some cases warrant systemic immunosuppression. However, very rarely, these cases have concomitant PSGN.^[2] We report a case of a 7-year-old male child who was admitted in the pediatric ward with complaints of redness of eyes, excessive tearing, and photophobia for 7 days, and generalized swelling which the mother noticed for the last 6–7 days (initially involving the periorbital region and later progressed to involve abdomen and legs) and cola-colored urine for the past 6 days. No history of fever, abdominal pain, diarrhea, painful micturition, joint pain/swelling, fatigue, rash, respiratory, and cardiac illness was noted. Physical examination revealed generalized swelling, mild pallor, and stage 1 hypertension (>95th + 8 mm Hg), with a recorded urine output of 0.9 mL/kg/day. The remaining general physical examination and systemic examination were unremarkable. His preliminary reports showed mild anemia with normocytic and normochromic pictures on peripheral smear examination. There was gross hematuria along with mild proteinuria in urine analysis, normal blood gas values along with serial rise in anti-streptolysin O (ASO) titer, and low complement C3 levels [Table 1].

Due to redness of the eyes, an ophthalmologic evaluation was done, which revealed a bilateral corrected vision of 6/6, mild bilateral conjunctival hyperemia. Slit-lamp examination of the right eye in oblique illumination showed fine diffuse keratic precipitates over the corneal endothelium along with +2 cells in the anterior chamber without any synechiae formation [Figure 1]. Alongside supportive care, the child was advised topical prednisolone [1%], intravenous antibiotics [inj ceftriaxone], and antihypertensive drug [oral amlodipine]. The patient responded well to the treatment regime during a hospital stay of 3 weeks. C3 levels done in follow-up at 10 weeks were normal (112 mg/dL).

The potential pathogenetic mechanisms involved can be attributed to the complex interaction of nephritogenic antigens and certain host factors. Nephritogenic antigens, the strains of streptococci isolated from the upper respiratory tract with nephritogenic potential were Rebecca Lancefield's M types 1, 2, 4, 12, 18, and 25, whereas impetigo-associated M types were 49, 55, 57, and 60.^[3] The postulated mechanisms for streptococcal

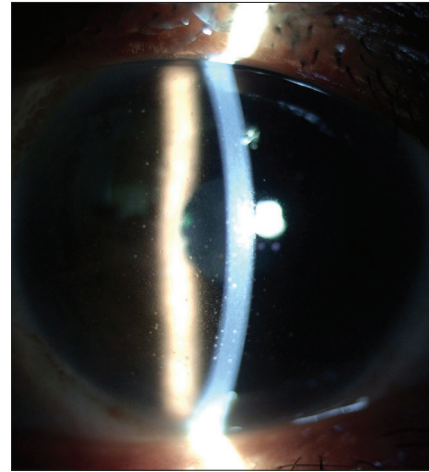


Figure 1: Slit-lamp examination of the right eye in oblique illumination showing fine diffuse keratic precipitates over the corneal endothelium along with +2 cells in the anterior chamber without any synechiae formation

nephritogenicity were molecular mimicry, nephritogenic antigens (e.g., M protein, H1pA, NAP1r- GAPDH, zSepB/SpeB), anti-Ig reactivity (e.g., neuroiminidase and strep Ig receptor binding), strep-related glomerular plasmin binding (e.g., streptokinase, enolase).^[1] However, with growing evidence against nephritogenic antigens such as M proteins, streptokinase, and H1pA,^[1] their primary role in the pathogenesis of PSGN is now nebulous. NAP1r was considered to be nephritogenic due to its plasmin binding capacity, which facilitates immune complex deposition, inexplicably the different localization of NAP1r antigen, C3, and Ig in the glomerulus advocates against it.^[1] However, later studies found that the glomerular localization of immunogold labeled SpeB/zSpeB (cationic cysteine proteinase), Ig, and complement in the subepithelial deposits called “humps” (electron-dense), which were a histological hallmark in PSGN.

The diagnosis of PSGN in this case was based on the clinical presentation (ascites, hematuria, hypertension, and mild proteinuria), low C3 levels, and clear evidence of prior streptococcal infection (such as rising ASO titer: a highly sensitive marker when compared to throat culture and history of prior streptococcal infection).^[4] The diagnosis of post-streptococcal uveitis (PSU) was based on the clinical presentation along with laboratory evidence suggestive of prior streptococcal infection and ophthalmologic features autoimmune uveitis (bilateral anterior segment non-granulomatous uveitis). Management of these cases is with supportive measures, topical steroids, and concomitant intravenous antibiotics to treat any residual infection as done in the index case. The complete resolution of uveitis

Table 1: Laboratory investigations performed in the index case

Analyte	Results		Reference range
	Admission	Discharge	
Hemoglobin (g/dL)	10.3	10.5	11.5-15.5
TLC (cells/mm ³)	15100	12300	4500-13500
Platelet count (10 ³ /μL)	468	392	150-350
hsCRP (mg/L)	2.2		8.8-0.8
ESR	49	38	
Serum Creatinine (mg/dL)	1.24	0.97	
Blood urea (mg/dL)	94	59	5-18
Serum Uric acid (mg/dL)	8.2	6.2	
Serum total protein (g/dL)	5.8	5.1	6.0-8.0
Serum albumin (g/dL)	3.25	3.12	3.6-5.2
Serum Na/K/Ca ²⁺	138/5.3/8.04	134/5.7/8.75	
Urine routine microscopy	RBCs: 80-90/hpf, pus cells: 3-4/hpf, Granular casts.	RBCs: 10-20/hpf, pus cells: nil, casts: nil	
ASO titer (IU)	800	1230	<200
Complement C3 (mg/dL)	34.90	38.7	90-180
ANA	Negative		
ANCA	Negative		
Rheumatoid factor	Negative		
Blood pH	7.33	7.42	7.35-7.45
Blood bicarbonate (mEq/L)	21	22	22-26
Total cholesterol (mg/dl)	149		
Urine Dipstick	+2	Negative	
Urine protein: creatinine ratio (mg/mg)	1.2	0.9	< 0.2
Urinary Beta ₂ microglobulin	Negative		

with topical steroids also reaffirms the good prognosis with PSU as per the previous literature. The PSU is a relatively rare entity with only one previously reported case of PSGN and PSU occurring simultaneously.^[5]

Acknowledgements

We thank the parents and child for consenting to this manuscript.

Financial support and sponsorship

This research received no external funding.

Conflicts of interest

There are no conflicts of interest.

**Najeeb Ahmad, Vivekanand Natarajan,
Vyas Kumar Rathaur, Swathi Chacham**

*Department of Pediatrics, All India Institute of Medical Sciences,
Rishikesh, Uttarakhand, India*

Address for correspondence:


*Dr. Swathi Chacham,
Department of Pediatrics, 6th Level (Floor), A Block, Medical College
Building, All India Institute of Medical Sciences, Virbhadra Marg,
Rishikesh, Uttarakhand, India.
E-mail: swathi.m.lahiri@gmail.com*

References

- Rodríguez-Iturbe B, Batsford S. Pathogenesis of post streptococcal glomerulonephritis a century after Clemens von Pirquet. *Kidney Int* 2007;71:1094-104.
- Curragh DS, McAvoy CE, Rooney M, McLoone E. Post-streptococcal uveitis syndrome in Caucasian population: A case series. *Eye* 2019;33:380-4.
- Cunningham MW. Pathogenesis of group A streptococcal infections. *Clin Microbiol Rev* 2000;13:470-511.
- Trivedi M, Pasari A, Chowdhury AR, Kurien AA, Pandey R. The epidemiology, clinical features, and outcome of infection-related glomerulonephritis from East India: A single center experience. *Indian J Nephrol* 2017;27:307-12.

5. Feldon M, Dorfman L, Tauber T, Morad Y, Bistrizter T, Goldman M. Post-streptococcal glomerulonephritis and uveitis—A case report. *Pediatr Nephrol* 2010;25:2351-3.

This is an open access journal, and articles are distributed under the terms of the Creative Commons Attribution-NonCommercial-ShareAlike 4.0 license, which allows others to remix, tweak, and build upon the work non-commercially, as long as appropriate credit is given and the new creations are licensed under the identical terms.

Access this article online	
Quick Response Code: 	Website: www.indianjnephrol.org
	DOI: 10.4103/ijn.IJN_426_20

How to cite this article: Ahmad N, Natarajan V, Rathaur VK, Chacham S. A rare association of post-streptococcal uveitis and post-streptococcal glomerulonephritis in a child. *Indian J Nephrol* 2022;32:516-8.

Received: 31-08-2020 **Revised:** 16-10-2020 **Accepted:** 25-12-2021 **Published:** 11-10-2022

© 2022 Indian Journal of Nephrology | Published by Wolters Kluwer - Medknow