

Ulcerative colitis after renal transplantation: A case report and review of literature

S. Parameswaran¹, K. Singh¹, R. Nada², M. Rathi, H. Kohli, V. Jha, K. Gupta, V. Sakhuja

Departments of Nephrology, ¹Gastroenterology and ²Histopathology, PGIMER, Chandigarh, India

ABSTRACT

Diarrhea is common after kidney transplantation and is usually related to immunosuppressive medication or is infective in etiology. Inflammatory bowel disease (IBD) is rare after kidney transplantation and is unexpected because the patient is already immunosuppressed. Specific immunomodulatory actions of calcineurin inhibitors have been hypothesized to play a role in the development of IBD in such patients. We report a case of IBD developing de novo after kidney transplantation. Our case is unique in that the patient was not on calcineurin inhibitors for 8 years prior to the development of IBD.

Key words: Immunosuppression, kidney transplantation, ulcerative colitis

Introduction

Gastrointestinal complications are common in renal transplant recipients.^[1] Bacterial, parasitic, viral infections and almost all of the immunosuppressive drugs used can produce diarrhea^[2]; however, inflammatory bowel disease (IBD) is rare in the transplant recipient. We report a case of *de novo* IBD developing 9 years after kidney transplantation.

Case Report

A 46-year-old man who developed end-stage renal disease (ESRD) of unknown etiology underwent live related renal transplantation, with his sister as the donor in 1996. He was started on cyclosporine, azathioprine, and prednisolone, with cyclosporine being withdrawn 1 year after transplantation because of financial constraints. Subsequently, he was only on azathioprine (125 mg daily) and prednisolone (15 mg on alternate days). He had no episodes of graft dysfunction, post-transplant diabetes

mellitus, malignancies, or opportunistic infections. He developed diarrhea in 2005, with four to five episodes of semi-formed stools a day. He had no fever, abdominal pain, or mucus in stool. He took symptomatic treatment for the same for two years. In 2007, he noticed blood streaking of stools and lost about 5 kg of weight. The stool examination was normal except for presence of blood. Multiple stool cultures and examinations were negative for *Salmonella*, *Shigella*, *Campylobacter*, *Clostridium difficile* toxin, *Yersinia*, enterotoxigenic *E. coli*, *Cryptosporidium*, *Giardia*, and strongyloides larvae. CMV PCR was negative. Colonoscopy revealed multiple 5 to 8 mm size superficial ulcers with edematous surrounding mucosa, with clean base and hyperemic margins up to 20 cm from the anal margin. Rest of the colon up to the hepatic flexure was normal. Biopsies were taken. On histological examination, the rectal and sigmoid mucosa showed mucosal hyperplasia with crypt abscesses and evidence of acute and chronic inflammation [Figures 1 and 2]. There was no evidence of CMV infection. A diagnosis of ulcerative colitis was made and he was started on mesalamine 2 gm/day. The frequency of stools decreased to 1 to 2 a day, with no blood or mucus. He is asymptomatic on maintenance treatment for last two years.

Address for correspondence:

Prof. Vinay Sakhuja, Department of Nephrology, PGIMER, Chandigarh - 160 012, India. E-mail: vsakhuja2009@gmail.com

Access this article online	
Quick Response Code:	Website: www.indianjnephrol.org
	DOI: 10.4103/0971-4065.78063

Discussion

Diarrhea is a common complication after transplantation, the incidence being as high as 12%.^[3] An etiology for the diarrhea can be identified in 80% of the cases, with infections being the most common cause (41.5%) followed by immunosuppressive medication (34%).^[3,4] Two-third of the diarrhea episodes develop in the late post-transplant

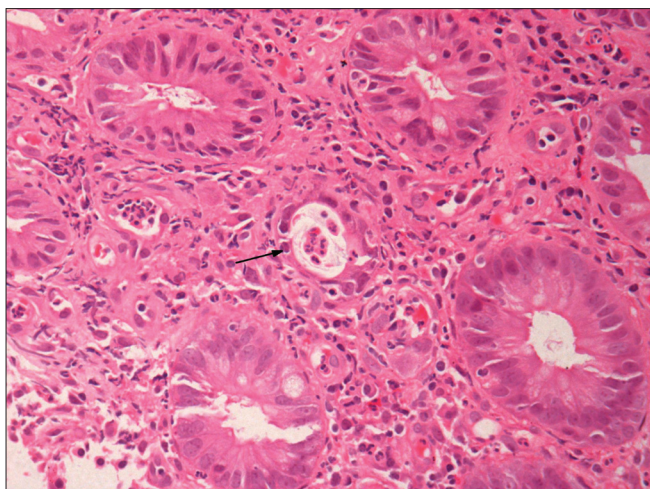


Figure 1: Active colitis with muco-depletion, cryptitis with crypt abscesses (arrow) (H and E, $\times 40$)

period (>6 months after transplantation) and 14% of the episodes are of chronic diarrhea.^[3] Almost all of the immunosuppressive drugs used might cause diarrhea.^[2] The incidence of diarrhea is higher with mycophenolate mofetil (MMF) compared to azathioprine,^[5] tacrolimus compared to cyclosporine,^[6] and with sirolimus compared to azathioprine.^[7] The dose dependence of diarrhea has been demonstrated with MMF^[8,9] and sirolimus,^[7] with higher doses associated with greater incidence of diarrhea. Combinations of immunosuppressive agents, while improving efficacy, may increase risk of diarrhea. For example, the incidence of diarrhea was increased but the rate of acute rejection was significantly less with the combination of MMF with tacrolimus, compared with the combination of MMF with cyclosporine.^[10] Similarly, the combination of MMF with sirolimus was associated with three-fold increase in the incidence of diarrhea compared with its combination with cyclosporine.^[11] A stepwise increase in diarrhea is noted from renal to cardiac to liver transplantation, and an overall higher incidence of diarrhea is seen in the white population.^[12]

IBD is an uncommon cause of diarrhea after transplantation and there are only few case reports of IBD developing *de novo* after kidney transplantation.^[13-15]

Passfall *et al.*^[13] in 1992 reported the first case of ulcerative colitis in a kidney transplant recipient while on monotherapy with cyclosporine. This 60-year-old patient on cyclosporine alone after methylprednisolone being withdrawn 6 months post-transplantation presented with rectal bleeding 6 years after kidney transplantation. The colonoscopy and histological features were consistent with ulcerative colitis and infectious causes were ruled out with extensive investigations. The patient responded to re-introduction of methylprednisolone and cyclosporine was continued.

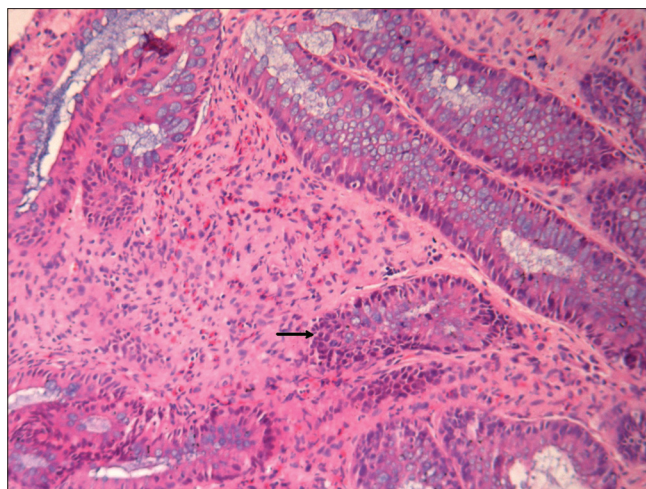


Figure 2: Crypt distortion, crypt loss (arrow), and interstitial inflammation with lymphomononuclear and eosinophilic infiltration (chronic colitis) (H and E, $\times 20$)

In 1997, Riley *et al.*^[14] reported a case series of transplant recipients who developed IBD. Only two of the 14 cases reported in the series were kidney transplant recipients, the rest being liver transplant recipients. The cause of ESRD was obstructive uropathy in one and ADPKD in the other patient. Both the patients were on cyclosporine and prednisolone and the dose of prednisolone at the onset of symptoms was less than 10 mg/day. Although one of the patients responded to treatment with azulfidine, the other continued to have intermittent flares despite increased doses of prednisolone. The mean duration to the onset of symptoms after transplant in this series was 4 years and the presenting symptoms, in order of frequency, were bloody diarrhea (seven), diarrhea (five), abdominal cramping (five), and bright red blood per rectum (three).

Hibbs *et al.*^[15] reported a case of ulcerative colitis developing in a renal transplant recipient 4 years after transplantation. The cause of ESRD in this male child was anti-GBM disease and he received triple immunosuppression with cyclosporine, prednisolone, and azathioprine. Four years after transplantation, he developed bloody diarrhea which was presumed to be CMV enterocolitis as he was CMV seropositive after transplantation and colonic biopsy showed CMV inclusions. He failed to respond to ganciclovir and required colectomy, which on histologic examination did not show any evidence of CMV but had features consistent with ulcerative colitis.

Development of IBD while the patient is on immunosuppression is unexpected, because IBD is believed to be the result of inappropriate and ongoing activation of the mucosal immune system and immunosuppression is used in the treatment of IBD.^[16] The most common situation in which association of transplantation with IBD

is seen is with liver transplantation in primary sclerosing cholangitis (PSC).^[14] About 70% of patients with PSC will develop IBD, which may be before transplantation or as *de novo* disease after liver transplantation.^[17] In the case series by Riley *et al.*,^[14] the average time to IBD diagnosis after transplantation (liver or kidney) was four years and none of them presented in the first post-transplant year. The authors hypothesized that this delay in presentation may be the result of lesser use of corticosteroids in the late post-transplant period. A number of hypotheses have been put forward to explain the unexpected development of IBD while on immunosuppression. The allograft may reconstitute a competent immune system^[18] in the recipient, and immunosuppressive therapy makes the patient susceptible to opportunistic infections which may trigger IBD manifestations.^[19] Both tacrolimus and cyclosporin A inhibit the peptidyl-prolyl isomerase enzyme activity and interfere with effective T cell intracellular signalling. In some predisposed individuals, tacrolimus or cyclosporin A may lead to reduction of the CD8 suppressor cells to a greater degree than other T cell populations, increasing the helper-to-suppressor ratio. Such a T cell imbalance has been reported to be an etiological factor in IBD.^[14,20-22] Riley *et al.* cites two clinical examples to support this theory. First is a case report of an HIV-positive patient with Crohn's disease whose IBD improved with decline in CD4+ cell count, thus decreasing the helper-to-suppressor ratio.^[23] The second example mentions two patients with renal cell cancer who received exogenous interleukin-2 (usually produced by activated T cells) and developed a flare in their preexisting IBD.^[24] These hypotheses explaining the development of IBD while on immunosuppression require further evaluation and validation. Our case is unique in that the patient was not receiving calcineurin inhibitors (CNIs) for 8 years preceding the development of symptoms; he was only on azathioprine and prednisolone and the above hypothesis do not apply in our case. Mechanisms other than the specific action of CNIs on T cell function thus appear to play a role in pathogenesis of IBD while on immunosuppression.

References

1. Rubin RH. Gastrointestinal infectious disease complications following transplantation and their differentiation from immunosuppressant-induced gastrointestinal toxicities. *Clin Transplant* 2001;15:11-22.
2. Helderman JH. Prophylaxis and treatment of gastrointestinal complications following transplantation. *Clin Transplant* 2001;15:29-35.
3. Altıparmak MR, Trabulus S, Pamuk ON, Apaydin S, Sariyar M, Oztürk R, *et al.* Diarrhoea following renal transplantation. *Clin Transplant* 2002;16:212-6.
4. Verdonk RC, Dijkstra G, Haagsma EB, Shostrom VK, Van den Berg AP, Kleibeuker JH, *et al.* Inflammatory bowel disease after liver transplantation: risk factors for recurrence and *de novo* disease. *Am J Transplant* 2006;6:1422-9.

5. Kobashigawa J, Miller L, Renlund D, Mentzer R, Alderman E, Bourge R, *et al.* A randomized active-controlled trial of mycophenolate mofetil in heart transplantation recipients. *Transplantation* 1998;66:507-15.
6. The US Multicenter FK 506 Liver Study Group. A comparison of tacrolimus (FK 506) and cyclosporine immunosuppression in liver transplantation. *N Engl J Med* 1994;331:1110-5.
7. Kahan BD, The rapamune US Study Group. Efficacy of sirolimus compared with azathioprine for reduction of acute renal allograft rejection: a randomized multicentre study. *Lancet* 2000;356:194-202.
8. Sollinger HW. Mycophenolate mofetil for the prevention of acute rejection in primary cadaveric renal allograft recipients. US Renal Transplant Study Group. *Transplantation* 1995;60:225-32.
9. Tricontinental Mycophenolate Mofetil Renal transplantation study Group. A blinded, Randomized clinical trial of mycophenolate mofetil for the prevention of acute rejection in cadaveric renal transplantation. *Transplantation* 1996;61:1029-37.
10. Miller J, Mendez R, Pirsch JD, Jensik SC. Safety and efficacy of tacrolimus in combination with mycophenolate mofetil (MMF) in cadaveric renal transplant recipients. FK506/MMF Dose-Ranging Kidney Transplant Study Group. *Transplantation* 2000;69:875-80.
11. Kreis H, Cisterne JM, Land W, Wrammer L, Squifflet JP, Abramowicz D, *et al.* Sirolimus in association with mycophenolate mofetil induction for the prevention of acute graft rejection in renal allograft recipients. *Transplantation* 2000;69:1252-60.
12. Neylan JF. Racial differences in renal transplantation after Immunosuppression with tacrolimus versus cyclosporine. FK506 Kidney Transplant Study Group. *Transplantation* 1998;65:515-23.
13. Passfall J, Distler A, Riecken EO, Zeitz M. Development of ulcerative colitis under the immunosuppressive effect of cyclosporine. *Clin Investig* 1992;70:611-3.
14. Riley TR, Schoen RE, Lee RG, Rakela J. A case series of transplant recipients who despite immunosuppression developed inflammatory bowel disease. *Am J Gastroenterol* 1997;92:279-82.
15. Hibbs AM, Bznik-Cizman B, Guttenberg M, Goldberg B, Meyers K. Ulcerative colitis in a renal transplant patient with previous Goodpasture disease. *Pediatr Nephrol* 2001;16:543-6.
16. Podolsky DK. Inflammatory bowel disease. *N Engl J Med* 2002;347:417-29.
17. LaRusso NF, Wiesner RH, Ludwig J, MacCarty RL. Primary sclerosing cholangitis. *N Engl J Med* 1984;310:899-903.
18. Wörns MA, Lohse AW, Neurath MF, Croxford A, Otto G, Kreft A, *et al.* Five cases of *de novo* inflammatory bowel disease after orthotopic liver transplantation. *Am J Gastroenterol* 2006;101:1931-7.
19. Wahbeh G, Hupertz V, Hallowell S, Patel R, Chrisant MR. Idiopathic colitis following cardiac transplantation: Three pediatric cases. *Pediatr Transplant* 2003;7:464-8.
20. Senju M, Hulstaert F, Lowder J, Jewell DP. Flow cytometric analysis of peripheral blood lymphocytes in ulcerative colitis and Crohn's disease. *Gut* 1991;32:779-83.
21. Hoang P, Senju M, Lowes JR, Jewell DP. Phenotypic characterization of isolated intraepithelial lymphocytes in patients with ulcerative colitis and normal controls. *Dig Dis Sci* 1992;37:1725-8.
22. Neissner M, Volk BA. Phenotypic and immunoregulatory analysis of intestinal T-cells in patients with inflammatory bowel disease: Evaluation of an *in vitro* model. *Eur J Clin Invest* 1995;25:155-64.
23. James SP. Remission of Crohn's disease after human immunodeficiency virus infection. *Gastroenterology* 1988;95:1667-9.
24. Sparano JA, Brandt LJ, Dutcher JP, DuBois JS, Atkins MB. Symptomatic exacerbation of Crohn's disease after treatment with high-dose interleukin-2. *Ann Intern Med* 1993;118:617-8.

How to cite this article: Parameswaran S, Singh K, Nada R, Rathi M, Kohli H, Jha V, *et al.* Ulcerative colitis after renal transplantation: A case report and review of literature. *Indian J Nephrol* 2011;21:120-2.

Source of Support: Nil, **Conflict of Interest:** None declared.