

## Renal Cysts and Nephrocalcinosis in 11 Beta-hydroxylase Deficiency

A 24-year-old male born of a nonconsanguineous union was admitted with sudden onset right-sided hemiplegia. He had a history of early onset of secondary sexual characteristics (facial and pubic hair growth, deepening of voice, and appearance of acne) and growth spurt since the age of 4 years. He also had features of mineralocorticoid excess including hypertension and hypokalemia since the age of 10 years. He was evaluated and diagnosed to have 11 beta-hydroxylase deficiency based on high-plasma 11-deoxycortisol and urinary 17-ketosteroids levels and the clinical features. He was noncompliant to his medications. He had three siblings, of whom one younger sibling was affected. Examination showed high blood pressure and right-sided hemiplegia. Ophthalmoscopy showed cotton wool spots and optic disc edema. Biochemical parameters were random blood sugar 111 mg%, urea 103 mg/dl, creatinine 6.7 mg/dl, sodium 124 mmol/L, and potassium 3.0 mmol/L. Arterial blood gas analysis showed pH 7.52, pCO<sub>2</sub>-25, paO<sub>2</sub>-95, and HCO<sub>3</sub><sup>-</sup>-20 mEq/L. He had mild hypocalcemia and hyperphosphatemia with normal urinary calcium. Liver function tests showed only mild hypoalbuminemia. Noncontrast computed tomography of brain showed acute intraparenchymal hemorrhage involving the left temporoparietal region with intraventricular extension and mass effect. A renal sonogram revealed bilateral medullary nephrocalcinosis with multiple renal cysts and bilateral shrunken kidneys. Noncontrast computed tomography of abdomen showed bilateral medullary nephrocalcinosis with multiple bilateral renal cysts and bulky adrenals [Figure 1a and b]. Follow-up serum creatinine was 3.4 mg/dl.

11β-hydroxylase deficiency is the second most common cause of congenital adrenal hyperplasia, which is a family of inborn errors of steroidogenesis.<sup>[1]</sup> In the classic form of 11β-hydroxylase deficiency, decreased or absent cortisol secretion stimulates adrenocorticotropic hormone secretion, which in turn, leads to accumulation of steroid precursors that are shunted into the androgen synthesis pathway. Patients have features of androgen excess including

masculinization of female external genitalia and precocious pseudopuberty in both sexes. Elevated metabolites with mineralocorticoid activity such as deoxycorticosterone and its derivatives can cause hypertension in about two-thirds of patients. Hypokalemic alkalosis can also be seen.

Long-standing hypokalemia due to various causes can result in renal cysts. Disorders such as primary hyperaldosteronism, distal renal tubular acidosis, Liddle's syndrome, apparent mineralocorticoid excess syndrome, and Bartter syndrome have been previously described to be associated with hypokalemia-induced renal cysts.<sup>[2,3]</sup> Various reasons for cyst formation and nephrocalcinosis in chronic hypokalemia have been postulated. Hypokalemia is a potent stimulus for hypertrophy and hyperplasia of the epithelial cells in the collecting duct, which can cause luminal obstruction and tubular dilatation. Hypokalemia also increases intrarenal ammonium ion levels, which in turn induce cyst formation by a number of mechanisms, namely, stimulating DNA, RNA, and protein synthesis. Increased intrarenal ammonium ion levels cause complement activation, which leads to interstitial nephritis, healing by dystrophic calcification. This calcification can plug in tubules and cause cyst formation. Nephrocalcinosis may be a consequence of dystrophic calcification.<sup>[2,3]</sup> Nephrocalcinosis in our patient may be secondary to hypokalemia-induced interstitial nephritis. Only one similar case of 11 beta-hydroxylase deficiency with hypokalemia-induced cyst formation and nephrocalcinosis was described previously.<sup>[4]</sup> We describe a patient with 11 beta-hydroxylase deficiency having two complications (nephrocalcinosis and renal cyst) to help the readers to be aware of such rare presentations.

### Financial support and sponsorship

Nil.

### Conflicts of interest

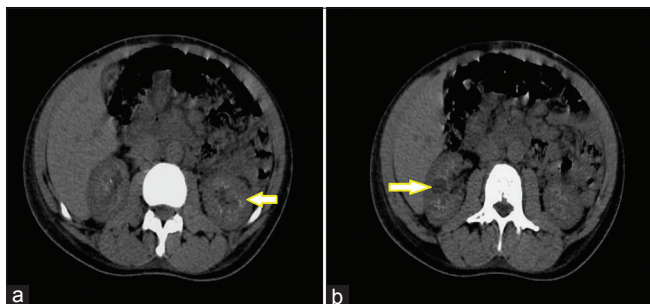
There are no conflicts of interest.

**M. C. Abdulla, R. Narayan, S. Ahamed<sup>1</sup>**

Departments of General Medicine and <sup>1</sup>Radiology, MES Medical College, Perinthalmanna, Kerala, India

### Address for correspondence:

Prof. M. C. Abdulla,  
Department of General Medicine, MES Medical College,  
Perinthalmanna - 679 338, Kerala, India.  
E-mail: drcamans@gmail.com



**Figure 1: (a and b) Noncontrast computed tomography of abdomen showing bilateral medullary nephrocalcinosis with multiple bilateral renal cysts**

### References

- Menabò S, Polat S, Baldazzi L, Kulle AE, Holterhus PM, Grötzinger J, *et al*. Congenital adrenal hyperplasia due to 11-beta-hydroxylase deficiency: Functional consequences of four CYP11B1 mutations. *Eur J Hum Genet* 2014;22:610-6.

2. Watanabe T, Tajima T. Renal cysts and nephrocalcinosis in a patient with Bartter syndrome type III. *Pediatr Nephrol* 2005;20:676-8.
3. Moudgil A, Rodich G, Jordan SC, Kamil ES. Nephrocalcinosis and renal cysts associated with apparent mineralocorticoid excess syndrome. *Pediatr Nephrol* 2000;15:60-2.
4. Aswani Y, Thakkar H, Hira P. Renal cysts and nephrocalcinosis in a patient deficient in 11 beta-hydroxylase enzyme. *Pol J Radiol* 2015;80:379-81.

This is an open access article distributed under the terms of the Creative Commons Attribution-NonCommercial-ShareAlike 3.0 License, which allows others to remix, tweak, and build upon the work non-commercially, as long as the author is credited and the new creations are licensed under the identical terms.

Access this article online	
<b>Quick Response Code:</b> 	<b>Website:</b> <a href="http://www.indianjephrol.org">www.indianjephrol.org</a>
	<b>DOI:</b> 10.4103/ijn.IJN_327_16

**How to cite this article:** Abdulla MC, Narayan R, Ahamed S. Renal cysts and nephrocalcinosis in 11 beta-hydroxylase deficiency. *Indian J Nephrol* 2017;27:410-1.