

## Immunotactoid Glomerulopathy: A Rare Glomerular Disease Case Study

### Abstract

Immunotactoid glomerulopathy (ITG) is a rare glomerular disease with variable responsiveness to the immunosuppressive therapy and with uncertain prognosis. ITG was diagnosed in two patients with type 2 diabetes mellitus with nephrotic syndrome and chronic kidney disease. The absence of diabetic retinopathy in the first case and the recent onset of diabetes in the second case accompanied with sudden increase in the 24-hour proteinuria and rapid decline in kidney function, prompted us to perform kidney biopsy. The electron microscopy set the diagnosis of ITG in both cases. There is no consensus for the treatment of ITG. The first patient was treated with combination of steroids and mycophenolate mofetil with reduction of the 24-hour proteinuria, but with persistence of the chronic kidney disease. The second patient received high doses of steroids with continuous deterioration of kidney function with the need of hemodialysis treatment.

**Keywords:** Chronic kidney failure, electron microscopy, glomerulonephritis, immunosuppression therapy, nephrotic syndrome

### Introduction

Immunotactoid glomerulopathy (ITG) is a rare form of immunoglobulin-derived fibrillary glomerular disease found in only 0.04% of native kidney biopsies.<sup>[1]</sup> It is characterized by deposition of parallelly arranged microtubules with hollow cores with diameter of 15 to 50 nm, located in the subepithelial space, mesangium, and/or subendothelial space of the glomerulus.<sup>[1-3]</sup> Based on these unique electron microscopic properties, ITG should be distinguished from other Congo red negative glomerulopathies: cryoglobulinemia, systemic lupus erythematosus (SLE) and fibrillary glomerulonephritis.<sup>[3]</sup> ITG is primary glomerulopathy subdivided into monoclonal and polyclonal variants with clinical and therapeutic implications.<sup>[1]</sup> A significant number of patients with monoclonal variant of ITG had lymphoproliferative disorders that produced monoclonal immunoglobulins that caused kidney damage.<sup>[1,4]</sup> Diabetes mellitus could be associated with an ITG.<sup>[1]</sup> Hypertension, nephrotic proteinuria, chronic kidney disease, extensive glomerular involvement,

and tubulointerstitial scarring were factors associated with the poorer prognosis of the ITG.<sup>[4]</sup>

Two cases with diabetes mellitus presented with nephrotic syndrome and chronic kidney disease were diagnosed with ITG by kidney biopsy. There was a reduction in the proteinuria in both cases with the immunosuppressive treatment, with no improvement in kidney function.

### Case 1

A 39-year-old woman with a history of insulin-dependent type 2 diabetes mellitus, hypothyroidism, thrombophilia, infertility, hypertension, nephrotic syndrome, and chronic kidney disease was admitted to our hospital for kidney biopsy. The physical examination of the patient revealed pitting edema in lower extremities bilaterally, and fine crackles in the bases of the lung lobes. One year ago, the patient was diagnosed with chronic kidney disease (CKD) with serum creatinine level of 1.5 mg/dL (normal for women: 0.5–1.1 mg/dL), serum blood urea nitrogen (BUN) level of 23.8 mg/dL (normal: 6–24 mg/dL), and 24-hour proteinuria of 2.7 g (<0.2 g). The progression of the CKD (serum creatinine level of 2.8 mg/dL, BUN level of 66.9 mg/dL, and proteinuria of 5.4 g/d) was noted in the

Vlatko Karanfilovski,  
Vesna Ristovska,  
Nikola Gjorgjievski,  
Igor G. Nikolov,  
Pavlina  
Dzekova-Vidimliski,  
Gordana Petrushevska<sup>1</sup>

University Hospital of  
Nephrology, Medical Faculty,  
Ss. Cyril and Methodius  
University- Skopje, <sup>1</sup>Institute  
of Pathology, Medical Faculty,  
Ss. Cyril and Methodius  
University- Skopje, Republic of  
North Macedonia

Received: 20-03-2022

Revised: 28-04-2022

Accepted: 13-05-2022

Published: 02-10-2022

### Address for correspondence:

Dr. Pavlina Dzekova-Vidimliski,  
University Hospital of  
Nephrology, Mother Theresa  
Str. 17, 1000 Skopje, Republic  
of North Macedonia.  
E-mail: pavlinadzekova@yahoo.  
com

### Access this article online

Website: <https://journals.lww.com/ijn>

DOI: 10.4103/ijn.ijn\_107\_22

### Quick Response Code:



**How to cite this article:** Karanfilovski V, Ristovska V, Gjorgjievski N, Nikolov IG, Dzekova-Vidimliski P, Petrushevska G. Immunotactoid glomerulopathy: A rare glomerular disease case study. Indian J Nephrol 2023;33:140-3.

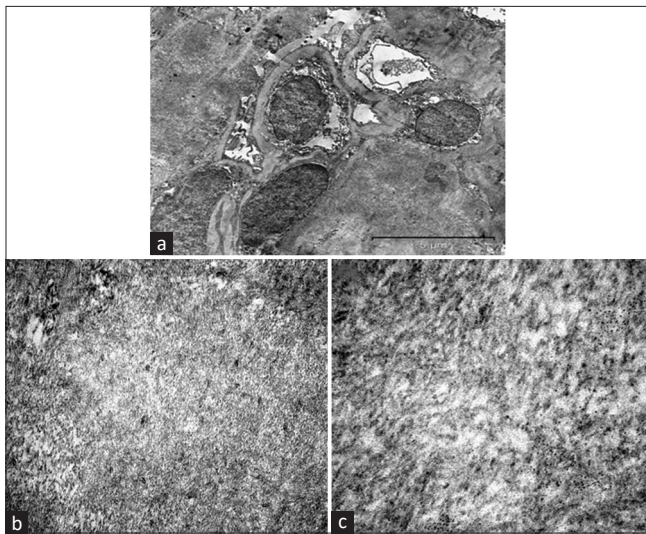
This is an open access journal, and articles are distributed under the terms of the Creative Commons Attribution-NonCommercial-ShareAlike 4.0 License, which allows others to remix, tweak, and build upon the work non-commercially, as long as appropriate credit is given and the new creations are licensed under the identical terms.

For reprints contact: WKHLRPMedknow\_reprints@wolterskluwer.com

patient after a period of one year. There was an absence of diabetic retinopathy. The serum immunoglobulins, serum complement compounds (C3 and C4), anti-double stranded DNA (anti-dsDNA), and serum-free light chains were negative. Antibodies against hepatitis B, hepatitis C, and HIV were not detected. A percutaneous ultrasound-guided kidney biopsy was performed. Five glomeruli were obtained: two glomeruli showed global sclerosis; three glomeruli had thickened glomerular basement membrane, diffuse and irregular mesangial nodules composed by “fibrillar-like” material negative for PAS and silver stain. Tubular atrophy and interstitial fibrosis were present. Electron microscopy indicated microtubular structures with hollow cores and thickened walls arranged in parallel arrays with average diameter of 35 nm, located predominantly in subendothelial space and mesangium of the glomeruli [Figure 1]. The final diagnosis of diabetic glomerulopathy with superimposed immunotactoid glomerulopathy was established. The patient was treated with mycophenolate mofetil (daily dose of 2000 mg) combined with dexamethasone (daily dose of 5 mg with slow tapering), and angiotensin II receptor blocker. Two months after initiation of the treatment, the 24-hour proteinuria decreased to 1.8 g, and remained stable over the next six months, with complete remission of the edema, but with the persistence of CKD.

## Case 2

A 49-year-old man was admitted to our hospital with generalized edema, oliguria, difficulty breathing, and continued weight gain (12 kg) over the last several months. The patient's medical history included hypertension, chronic obstructive lung disease, hypospadias, dilatative



**Figure 1:** Electron microscopy showing massive accumulation of organized moderate dense deposits in capillary loops and mesangial regions (1a - magnification  $\times 10000$ ). On higher magnification, the mesangial deposits exhibited characteristic microtubular substructure, with hollow cores and thickened walls focally arranged in parallel arrays typical of immunotactoid glomerulopathy (1b - magnification  $\times 50000$  and 1c - magnification  $\times 150000$ )

cardiomyopathy, and newly diagnosed type 2 diabetes mellitus without diabetic retinopathy. On admission, laboratory findings showed serum creatinine level of 2.9 mg/dL (normal for men 0.6–1.2 mg/dL), serum BUN level of 80.1 mg/dL, 24-hour proteinuria of 7 g, HbA1c of 6.5% (normal  $<5.7\%$ ), serum albumin level of 2.5 g/dL (normal 3.5–5 g/dL), and total cholesterol level of 348 mg/dL (normal  $<200$  mg/dL). Additional investigations revealed normal levels of serum immunoglobulins and complement compounds (C3 and C4). Serum-free light chains, antineutrophil cytoplasmic antibodies (c-ANCA), anti-dsDNA and anti-glomerular basement membrane (anti-GBM) antibodies were also negative. Hepatitis B surface antigen resulted positive. A percutaneous ultrasound-guided kidney biopsy was performed. Under light microscopy, a total number of 15 glomeruli were observed. Five glomeruli were ischemically collapsed, and all other glomeruli were replaced with amorphous eosinophilic material predominantly with endocapillary localization. The renal tubules were atrophic with protein intratubular casts. Mild interstitial fibrosis with mixed mononuclear cell infiltration was also noted. On immunofluorescence (IF), IgG and C3 were dominant deposits in the glomeruli, with an irregular pattern of distribution. Electron microscopy showed non-branching, hollow-core microtubules in the subendothelial zone, confirming the diagnosis of immunotactoid glomerulopathy. The patient was treated with high doses of corticosteroids (500 mg/day) for 3 consecutive days with a gradual reduction of the dose. There was still rapid a decline in the patient's kidney function, with the need of hemodialysis treatment. One month after initiation of the immunosuppressive treatment, the 24-hour proteinuria of the patient decreased to 2.6 g, with the persistence of kidney failure. The patient survived on the maintenance hemodialysis treatment for three years and died from cardiac failure.

## Discussion

Immunotactoid glomerulopathy belongs to a heterogeneous group of glomerular diseases characterized by deposition of fibrils or microtubules in different zones of the glomeruli.<sup>[5]</sup> The exact pathogenesis of ITG remains unclear. Circulating immune complexes or *in situ* reaction of antibodies directed against native or “planted” antigens within glomeruli were not identified in this disease, suggesting that ITG represents a unique pathogenic mechanism of glomerular injury.<sup>[6]</sup> The physiochemical environment of glomerulus and/or some circulating factor may trigger the deposition of a “yet-to-be” identified protein with the intrinsic ability of polymerization.<sup>[1]</sup>

Clinically and/or serologically, patients with ITG have no evidence of cryoglobulinemia, amyloidosis, systemic lupus erythematosus, or a paraproteinemia, diseases associated with glomerular deposits with tactoidal or

fibrillar characteristics.<sup>[6]</sup> Immunotactoid glomerulopathy is a primary glomerulopathy, with the clinical presentation like other primary glomerular diseases. Patients present with proteinuria (nephrotic range in more than 60%), and over a half of the patients have hypertension, hematuria, CKD, and hematologic disorders.<sup>[1,6-8]</sup> The recurrence to allograft was seen in half of the transplanted patients, but usually with a more benign course.<sup>[5]</sup> In the largest available series of 73 patients with ITG, Nasr *et al.*<sup>[1]</sup> reported that all patients had proteinuria (nephrotic range in 76% of the patients), and nephrotic syndrome was present in more than half of the patients (57%). The other reported comorbidities were hypertension (88%), diabetes mellitus (15%), and autoimmune diseases (14%).<sup>[1]</sup> In the study of Korbet *et al.*,<sup>[6]</sup> progression to kidney failure had occurred in more than 40% of patients, and recurrence of ITG in the renal allograft was detected in two out of four transplanted patients. The present case patients with ITG had diabetes mellitus with a sudden increase of 24-hour proteinuria in nephrotic range, with an absence of diabetic retinopathy. Hypertension and CKD were also present in both cases, at the time of diagnosis, and the second patient developed kidney failure with the need for hemodialysis treatment.

The most frequently encountered patterns of glomerular injury seen by light microscopy in ITG patients were endocapillary proliferative glomerulonephritis (GN), membranoproliferative GN (MPGN), and membranous GN.<sup>[1,9]</sup> The IgG (mean intensity 2.3+; on a scale of 0–3+) and C3 (mean intensity 2+; on a scale of 0–3+) were the most frequently deposited in the glomeruli of patients with ITG on immunofluorescence.<sup>[1,10]</sup> Ultrastructural evaluation usually revealed glomerular electron-dense microtubules with a mean diameter of 30 nm and hollow cores arranged in parallel arrays.<sup>[1,3,6,9]</sup> In MPGN and endocapillary proliferative GN, deposits were located in subepithelial space, whereas membranous GN showed global deposits distribution.<sup>[1]</sup> Diffuse and irregular nodular expansion of glomerular mesangial matrix found in our first case patient was highly suggestive of diabetic glomerulosclerosis, but the electron microscopic analysis demonstrated fibrillary background of these nodules and established the final diagnosis of ITG. In our second case patient, glomerular sclerosis and tubular atrophy were more prominent, associated with severe loss of kidney function.

To date, there is no proven effective therapy for ITG. In a study by Nasr *et al.*<sup>[1]</sup> out of 48 patients with available data on treatment, 9 (19%) received only supportive therapy, 5 (10%) received steroid monotherapy, and 34 (71%) received immunosuppressive/chemotherapy (rituximab, cyclophosphamide, bendamustine, fludarabine, pentostatin, mycophenolate mofetil, lenalidomide) with or without steroids. Out of five patients treated with steroid monotherapy, one patient achieved complete remission, one patient had stable proteinuria with

CKD, and three progressed to kidney failure. Out of 34 patients who were treated with immunosuppressive agents with or without steroids, 14 (42%) achieved complete remission, 11 (33%) were with CKD, 6 (18%) partial remission, and 2 (6%) progressed to kidney failure. The serum creatinine level, diabetes mellitus, and moderate-to-severe tubulointerstitial scarring were factors associated with worse outcome (kidney failure or death).<sup>[1,4]</sup> Two smaller studies reported worse response of ITG to immunosuppressive therapy (12.5% and 14.2%, respectively) with development of kidney failure over 2-4 years in 50% of treated patients.<sup>[11,12]</sup> Contrary to this, clone-directed therapy (chemotherapy) in monoclonal ITG was associated with a more favorable prognosis.<sup>[1]</sup>

## Conclusion

The presence of proteinuria and CKD in a patient with diabetes almost always suggests diabetic nephropathy. The development of diabetic nephropathy is usually a progressive process that takes years. Other causes of proteinuria should be considered in patients with diabetes with new onset of nephrotic proteinuria when there is no evidence of microvascular disease. Diabetes mellitus could be associated with an immunotactoid glomerulopathy. Immunotactoid glomerulopathy is a rare glomerular disease with poor prognosis, often progressing to kidney failure within a few years.

## Declaration of patient consent

The authors certify that they have obtained all appropriate patient consent forms. In the form, the patient(s) has/have given his/her/their consent for his/her/their images and other clinical information to be reported in the journal. The patients understand that their names and initials will not be published and due efforts will be made to conceal their identity, but anonymity cannot be guaranteed.

## Financial support and sponsorship

There are no financial support and sponsorship.

## Conflicts of interest

There are no conflicts of interest.

## References

- Nasr SH, Kudose SS, Said SM, Santoriello D, Fidler ME, Williamson SR, *et al.* Immunotactoid glomerulopathy is a rare entity with monoclonal and polyclonal variants. *Kidney Int* 2021;99:410-20.
- Ferluga D, Hvala A, Vizjak A, Koselj-Kajtna M, Mihelic-Brcic M. Immunotactoid glomerulopathy with unusually thick extracellular microtubules and nodular glomerulosclerosis in a diabetic patient. *Pathol Res Pract* 1995;191:585-96.
- Ohashi A, Kumagai J, Nagahama K, Fujisawa H. Case of immunotactoid glomerulopathy showing high responsiveness to steroids therapy despite severe pathological features. *BMJ Case Rep* 2019;12:e229751.
- Schwartz MM, Korbet SM, Lewis EJ. Immunotactoid glomerulopathy. *J Am Soc Nephrol* 2002;13:1390-7.

5. Azevedo A, Cotovio P, Góis M, Nolasco F. Rare diagnosis in a patient with diabetes with nephrotic proteinuria. *BMJ Case Rep* 2019;12:bcr-2017-223835.
6. Korbet SM, Schwartz MM, Lewis EJ. Immunotactoid glomerulopathy. *Am J Kidney Dis* 1991;17:247-57.
7. Nagaharu K, Sugimoto Y, Kawakami K. A rare case of immunotactoid glomerulopathy associated with hodgkin lymphoma. *Case Rep Nephrol* 2021;2021:5527966.
8. Kuang C, Quann K, Liman AK, Frye R, Alshoubaki N, Ramkumar M, *et al.* A rare case of MGRS with immunotactoid glomerulopathy responding to bortezomib, dexamethasone, and rituximab. *Clin Case Rep* 2020;8:1984-7.
9. Rosenstock JL, Markowitz GS, Valeri AM, Sacchi G, Appel GB, D'Agati VD. Fibrillary and immunotactoid glomerulonephritis: Distinct entities with different clinical and pathologic features. *Kidney Int* 2003;63:1450-61.
10. Hirashio S, Arima T, Satoh A, Mandai K, Hara S, Masaki T. A case of immunotactoid glomerulopathy with false-negative IgG staining. *BMC Nephrol* 2018;19:143.
11. Nasr SH, Fidler ME, Cornell LD, Leung N, Cosio FG, Sheikh SS, *et al.* Immunotactoid glomerulopathy: Clinicopathologic and proteomic study. *Nephrol Dial Transplant* 2012;27:4137-46.
12. D'Agati V, Sacchi G, Truong L. Fibrillary glomerulopathy: Defining the disease spectrum. *J Am Soc Nephrol* 1991;2:591.