

## Renal Metastases Masquerading as Glomerulonephritis

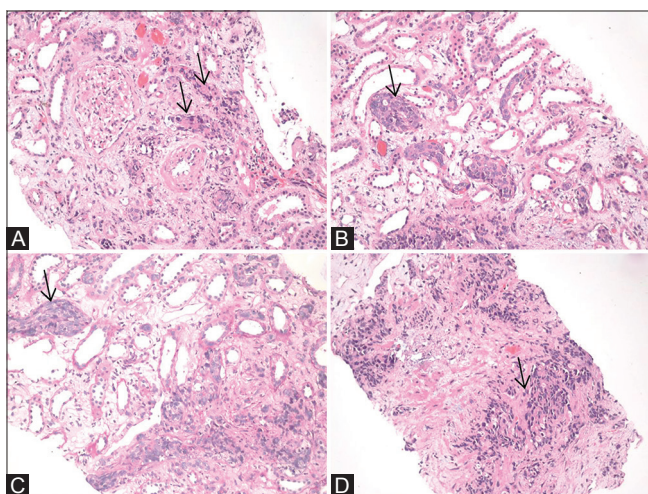
A 41-year-old man with no past comorbidities presented with anorexia and malaise for 15 days. On evaluation, he was found to have progressive renal impairment with rise of serum creatinine from 1.2 to 2.7 mg/dl and then to 3.4 mg/dl over 10 days. His urine examination showed 2+ albumin, 25–30 red blood cells, and 5–6 pus cells per high-power field. The spot urine protein-to-creatinine ratio was 1.2. He was diagnosed to have rapidly progressive renal failure, and initial differential diagnoses were rapidly progressive glomerulonephritis (GN) because of IgA nephropathy/membranoproliferative GN/pauci-immune crescentic GN, and acute interstitial nephritis.

Ultrasonography showed mildly enlarged kidneys with no hydronephrosis. His serum calcium and uric acid levels were normal. Renal biopsy showed interstitium containing focal deposits of neoplastic tissue composed of nests of tumor cells with hyperchromatic nuclei and scanty-to-moderate amount of cytoplasm [Figure 1]. Mitotic figures were present and staining for mucin was negative. Stromal desmoplasia was noted around the metastatic deposits. There were minimal tubular injury and moderate interstitial lymphocytic infiltrate. The biopsy suggested presence of secondaries in the kidney with interstitial nephritis. Immunohistochemical staining for routine tumor markers such as cytokeratin 7, cytokeratin 20, thyroid transcription factor, caudal-type homeobox 2, prostate-specific antigen (PSA), and paired-box gene 8 was negative. The primary tumor site was not confirmed from this immune profile. Serum cancer antigen 19-9, PSA, human chorionic gonadotropin, carcinoembryonic antigen, and alpha-fetoprotein levels were normal. Computed

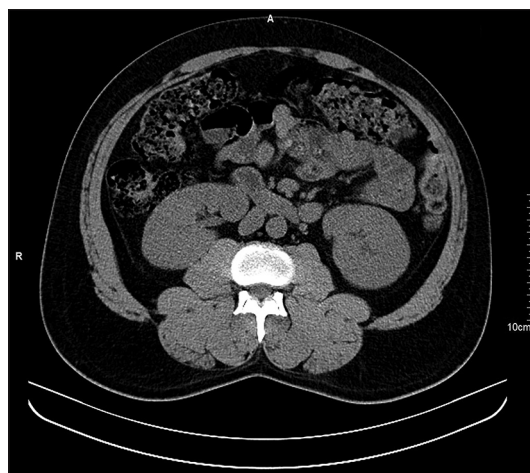
tomography chest and abdomen did not reveal any mass lesions or lymph node enlargement. Except for little bulky kidneys, there were no focal lesions presumably because of diffuse involvement of kidneys by tumor deposits [Figure 2]. He was diagnosed with renal metastatic deposits from carcinoma of unknown primary. Radionuclide scan and further evaluation were planned, but the patient succumbed to death because of sepsis from pneumonia.

Renal metastases are usually solitary, unilateral, asymptomatic and detected as mass lesions on radiologic imaging. If symptomatic, they may present with flank pain, hematuria, or weight loss. Renal function may not be affected in majority, unless there are associated complications such as hypercalcemia, uric acid nephropathy, or sepsis. Proteinuria is usually absent or insignificant. Most often, renal metastases occur as a part of advanced systemic disease with widespread dissemination of primary tumor. The majority of tumors are carcinomas and most of them are adenocarcinomas. Most common primary tumor sites include lung, breast, gastrointestinal, head and neck, prostate, and thyroid; rare sites include adrenal gland, skin, bone, testis, and ovary. Hematologic malignancies such as leukemia, lymphoma, and multiple myeloma may also invade the kidneys. Most cases of renal metastases are discovered during evaluation or follow-up of the primary nonrenal tumor. Rarely, they are identified incidentally during abdominal imaging and metastasis to kidney precedes diagnosis of primary tumor. If there is no identified primary nonrenal tumor, it could be mistaken for renal cell carcinoma.

In a larger retrospective study of 151 cases of renal metastasis, up to 80% cases of primary tumors were carcinomas. The most common primary tumor sites were lung (43.7%), colorectal (10.6%), ENT (6%), breast (5.3%),



**Figure 1:** Composite picture showing tumor deposits (marked by arrows) in the cortex and medulla. The tumor cells are darkly stained, irregular, and have an acinar pattern. Mucin was negative. Panels B and C show tumor emboli within peritubular capillaries, and in Panel D, the tumor is in the interstitium at the cortico-medullary region (hematoxylin and eosin, x200)



**Figure 2:** Axial image of plain computed tomography (CT) showing bilateral mild bulky kidneys with no focal lesions or hydronephrosis

soft tissue (5.3%), and thyroid (5.3%). Renal metastases were typically solitary in majority (77.5%) of cases.<sup>[1]</sup> In a clinicopathological study of 43 cases of renal metastasis, common primary sites included the lung, breast, female genital tract, and head and neck. The majority (86%) of the tumors were carcinomas, and most of these were adenocarcinomas. Most of the metastases were solitary (70%) and unilateral (77%). Lack of other distant organ metastases was found in 37% and a medullary rather than a cortical location was found in 11%. In 88% of the cases (38/43), the primary cancer was diagnosed first, whereas in 2% (1/43), the kidney metastasis was diagnosed first; in the rest, the primary and the metastasis were diagnosed concurrently. In about 35% of patients, the clinical features favored a primary renal neoplasm over a kidney metastasis; this was especially observed with metastases from the thyroid.<sup>[2]</sup>

Isolated microscopic renal metastasis with no mass lesion on imaging, presenting incidentally with progressive renal impairment and masquerading as a glomerular disease, is very rare and has not been reported in the literature. This case illustrates that renal metastases can present with features simulating GN and renal impairment can result from secondaries affecting the kidneys with no obvious mass lesion on imaging. Clinicians should be vigilant and aware of this rare phenomenon.

### Declaration of patient consent

The authors certify that they have obtained all appropriate patient consent forms. In the form the patient(s) has/have given his/her/their consent for his/her/their images and other clinical information to be reported in the journal. The patients understand that their names and initials will not be published and due efforts will be made to conceal their identity, but anonymity cannot be guaranteed.

### Financial support and sponsorship

Nil.

### Conflicts of interest

There are no conflicts of interest.

### Praveen Kumar Etta, Mulpuru Venkateswara Rao, Madhavi Thatipamula<sup>1</sup>, Swarnalata Gowrishankar<sup>2</sup>

*Department of Nephrology and Renal Transplantation, Asian Institute of Nephrology and Urology, <sup>1</sup>Department of Radio-diagnosis, Yashoda Hospitals, <sup>2</sup>Department of Histopathology, Apollo Hospitals, Hyderabad, Telangana, India*

#### Address for correspondence:

*Dr. Praveen Kumar Etta,  
Department of Nephrology and Renal Transplantation, Asian Institute of Nephrology and Urology, Hyderabad, Telangana, India.  
E-mail: drpraveen85@gmail.com*

### References

1. Zhou C, Urbauer DL, Fellman BM, Tamboli P, Zhang M, Matin SF, et al. Metastases to the kidney: A comprehensive analysis of 151 patients from a tertiary referral centre. *BJU Int* 2016;117:775-82.
2. Wu AJ, Mehra R, Hafez K, Wolf JS Jr, Kunju LP. Metastases to the kidney: A clinicopathological study of 43 cases with an emphasis on deceptive features. *Histopathology* 2015;66:587-97.

This is an open access journal, and articles are distributed under the terms of the Creative Commons Attribution-NonCommercial-ShareAlike 4.0 License, which allows others to remix, tweak, and build upon the work non-commercially, as long as appropriate credit is given and the new creations are licensed under the identical terms.

Access this article online	
<b>Quick Response Code:</b> 	<b>Website:</b> <a href="http://www.indianjephrol.org">www.indianjephrol.org</a>
	<b>DOI:</b> 10.4103/ijn.IJN_245_18

**How to cite this article:** Etta PK, Rao MV, Thatipamula M, Gowrishankar S. Renal Metastases Masquerading as Glomerulonephritis. *Indian J Nephrol* 2019;29:300-1.