

## An Unusual Case of Cryoglobulinemic Glomerulonephritis Revealing Waldenstrom's Macroglobulinemia

Dear Editor,

Kidney complications in multiple myeloma are well described, but kidney pathology encountered in Waldenstrom's macroglobulinemia (WM) has received less attention.<sup>1</sup> Cryoglobulinemic membranoproliferative glomerulonephritis (CMGN) has been described in only few isolated cases of WM.

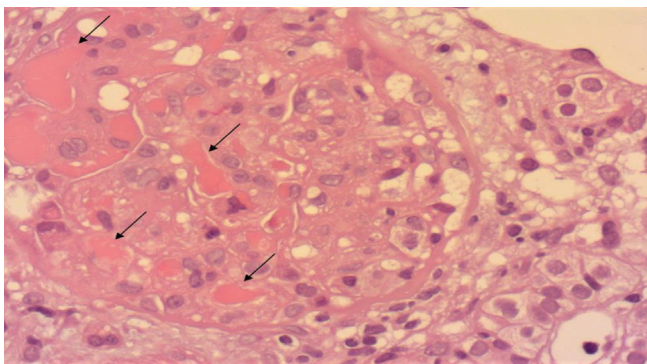
We present the case of a 68-year-old woman with lower limb edema, creatinine clearance 24.8 mL/min with hematuria and proteinuria. Protein electrophoresis revealed a monoclonal band in the Gamma region with monoclonal gammopathy in Immunoglobulin M (IgM) and Kappa region. Free kappa (68 mg/L), free lambda (26,39 mg/L), and kappa/lambda (2,58) were observed.

Kidney biopsy shows membranoproliferative glomerulonephritis (MPGN) with intracapillary proliferation. Eosinophilic endoluminal and glomerular deposits with double-contoured basement membranes were seen [Figure 1]. Direct immune-fluorescence was diffusely positive for IgM, C3, and kappa light chains.

Bone marrow infiltrating lymphoid cells comprised small lymphocytes (6%) and plasmacytoid lymphocytes (15%). On immunohistochemistry, small lymphocytes and plasmacytoid lymphocytes were positive for CD20, with Kappa clonality compatible with WM.

Treatment with rituximab, edoxan, and prednisone with eight plasma exchange sessions was done, leading to progressive decrease of proteinuria, remission of edema, and amelioration of renal function.

Renal involvement of WM is a rare manifestation. The first reported case of acute kidney injury associated with WM was described by Argani in 1964.<sup>2</sup> Glomerular diseases are a result of direct infiltration of malignant cells, an immune-mediated reaction to the cells, or production of an abnormal paraprotein. Kidney biopsy findings include light



**Figure 1:** Cryoglobulinemic glomerulonephritis with membrano-proliferative pattern: A glomerulus showing mesangial hypercellularity and cryoglobulin plugs within capillary loops (black arrows) (H&E stain, original magnification  $\times 400$ ).

chain amyloidosis, cryoglobulinemic glomerulonephritis (CG), and direct infiltration by lymphoid cells with intracapillary aggregation of IgM.<sup>3</sup> WM is characterized by an indolent course. However, in some cases, it is associated with a worse prognosis. Recent studies recommend a combination of rituximab with cyclophosphamide.<sup>4</sup>

This observation of severe CMGN revealing WM demonstrates the value of renal biopsy coupled with careful hematological evaluation in managing nephropathy associated with monoclonal Ig.

### Declaration of patient consent

The authors certify that they have obtained all appropriate patient consent.

### Conflicts of interest

There are no conflicts of interest.

**Sonia Dziri<sup>1</sup>, Narjess Ben Aicha<sup>1</sup>, Awatef Azzabi<sup>1</sup>,  
Wissal Sahtout<sup>1</sup>, Safa Nouira<sup>1</sup>, Asma Fradi<sup>1</sup>,  
Raja Boukadida<sup>1</sup>, Yosra Guedri<sup>1</sup>, Senda Mrabet<sup>1</sup>,  
Dorsaf Zellama<sup>1</sup>**

<sup>1</sup>Department of Nephrology, Sahloul Teaching Hospital, Khzema Ouest, Sousse, Tunisia.

### Corresponding author:

Sonia Dziri, Department of Nephrology, Sahloul Teaching Hospital, Khzema Ouest, Sousse, Tunisia. E-mail: dziri.sonia@yahoo.com

### References

- Costa PZ, Chorão P, Póvoa A, Vieira P, Cabrera H, Mendes O, et al. Waldenström macroglobulinemia and cerebral venous thrombosis: From diagnosis to complication. *Case Rep Med*. 2019;9581605.
- Argani I, Kipkie GF. Macroglobulinemic nephropathy. Acute renal failure in macroglobulinemia of Waldenström. *Am J Med*. 1964;151–7.
- Ramos R, Poveda R, Sarrá J, Domingo A, Carreras L, Grinyó JM. Renal involvement in non-malignant IgM gammopathy. *Nephrol Dial Transplant*. 2007;22:627–30.
- Dimopoulos MA, Anagnostopoulos A. Waldenström's macroglobulinemia. *Best Pract Res Clin Haematol*. 2005;18:747–65.

This is an open access journal, and articles are distributed under the terms of the Creative Commons Attribution-NonCommercial-ShareAlike 4.0 License, which allows others to remix, tweak, and build upon the work non-commercially, as long as appropriate credit is given and the new creations are licensed under the identical terms.

**How to cite this article:** Dziri S, Ben Aicha N, Azzabi A, Sahtout W, Nouira S, Fradi A, et al. An Unusual Case of Cryoglobulinemic Glomerulonephritis Revealing Waldenstrom's Macroglobulinemia. *Indian J Nephrol*. 2024;34:542. doi: 10.25259/IJN\_102\_2024

Received: 28-02-2024; Accepted: 14-03-2024;

Online First: 04-06-2024; Published: 30-08-2024

DOI: 10.25259/IJN\_102\_2024

