

## Urgent Dialysis as a Bridge to Palliative Care in Advanced Cancer Patients

Dear Editor,

I am writing to highlight the imperative role of urgent dialysis as a bridge to palliative care in the management of advanced cancer patients with renal complications.

A 39-year-old woman, diagnosed with extensive anorectal cancer, underscores the complexities of managing renal dysfunction in the palliative care setting.<sup>1</sup> Despite exhaustive chemotherapy regimens the patient's disease progressed relentlessly, compelling the primary team to transition her to best supportive care. Earlier in her disease course, the palliative medicine team managed her symptoms, focusing on pain control and preserving quality of life. The recent onset of symptoms suggestive of uremic encephalopathy, including flapping tremors, asterixis, and intractable vomiting, raised concern for acute kidney injury (AKI) secondary to obstructive uropathy. Laboratory investigations confirmed severe uremia with creatinine at 9.7 mg/dL. Point-of-care ultrasound demonstrated bilateral hydronephrosis, consistent with disease progression leading to post-renal AKI.

Considering her deteriorating clinical status and the urgency of symptom management, urgent dialysis emerged as a pivotal intervention. By promptly addressing the metabolic derangements associated with severe uremia, dialysis provided immediate relief, aligning with the ethos of best supportive care. It served as a bridge, affording time for planning a percutaneous nephrostomy (PCN) to alleviate the obstructive etiology of the AKI. In palliative care, where curative measures are no longer feasible, interventions must be judiciously selected to optimize comfort and dignity.<sup>2</sup> Urgent dialysis, as demonstrated in this case, represents a critical adjunct to palliative care,

facilitating symptom control and preserving quality of life in the face of complex medical challenges.<sup>3</sup>

### Conflicts of interest

There are no conflicts of interest.

**Devina Juneja**<sup>1</sup> 

<sup>1</sup>Department of Palliative Medicine, All India Institute of Medical Sciences (AIIMS), New Delhi, India

**Corresponding author:** Devina Juneja,  
Department of Palliative Medicine, All India Institute of Medical Sciences (AIIMS), New Delhi, India. E-mail: [juneja.devina1995@gmail.com](mailto:juneja.devina1995@gmail.com)

### References

1. Grubbs V, Moss AH, Cohen LM, Fischer MJ, Germain MJ, Jassal SV, *et al.* Dialysis advisory group of the American society of nephrology. A palliative approach to dialysis care: A patient-centered transition to the end of life. *Clin J Am Soc Nephrol* 2014;9:2203–9.
2. Moss AH. Integrating supportive care principles into dialysis decision making: A primer for palliative medicine providers. *J Pain Symptom Manage* 2017;53:656–62.e1.
3. Sturgill D, Bear A. Unique palliative care needs of patients with advanced chronic kidney disease - the scope of the problem and several solutions. *Clin Med (Lond)* 2019;19:26–9.

This is an open access journal, and articles are distributed under the terms of the Creative Commons Attribution-NonCommercial-ShareAlike 4.0 License, which allows others to remix, transform, and build upon the work non-commercially, as long as appropriate credit is given and the new creations are licensed under the identical terms.

**How to cite this article:** Juneja D. Urgent Dialysis as a Bridge to Palliative Care in Advanced Cancer Patients. *Indian J Nephrol*. 2024;34:676. doi: [10.25259/IJN\\_243\\_2024](https://doi.org/10.25259/IJN_243_2024)

**Received:** 21-05-2024; **Accepted:** 01-06-2024  
**Online First:** 01-08-2024; **Published:** 28-10-2024  
**DOI:** [10.25259/IJN\\_243\\_2024](https://doi.org/10.25259/IJN_243_2024)



## Tetany in a Patient with Gastroesophageal Reflux Disease

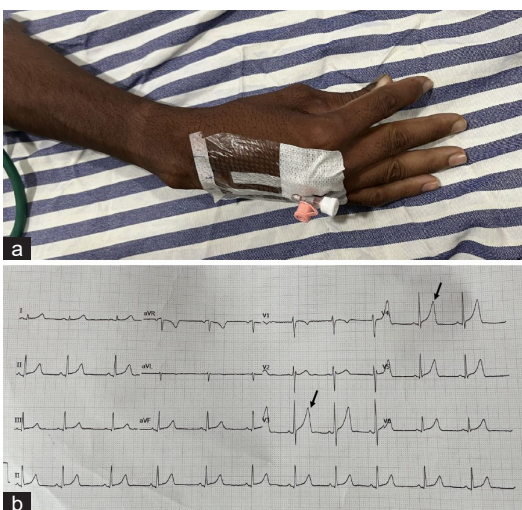
Dear Editor,

Proton pump inhibitors (PPI) are widely prescribed drugs and generally well tolerated. However, prolonged intake of PPI increases risk of micronutrient deficiency (iron, magnesium, and vitamin B12), infections, and kidney disease.<sup>1</sup> We report the occurrence of tetany due to hypomagnesemia in a patient who had been on long-term PPI therapy for gastroesophageal reflux.

Our patient was a 32-year-old man, who had been receiving pantoprazole 40 mg/day and domperidone 20 mg/day for 5 years for refractory gastroesophageal reflux disease. Attempts to stop pantoprazole resulted in resurgence of reflux symptoms. He presented during peak summer with recurrent muscle cramps to different

hospitals where heat cramp was diagnosed and treated symptomatically. There was no respite of symptoms and he presented to our emergency room with generalized muscle cramps. He had excess fatigue and cramping was aggravated by ambulation. There was no associated fever, vomiting, or diarrhea. He consumed alcohol occasionally and denied intake of illicit drugs. He did not have diabetes mellitus or hypertension, and he was not taking any other medications. Family history was unremarkable.

On arrival, he was conscious, oriented, afebrile lean-built, and his vital signs were normal. Inflation of blood pressure cuff provoked tetany [Figure 1a]. Plantar reflex was flexor, muscle power and sensory system examination were normal and deep tendon reflexes were brisk. A diagnosis of tetany was made.



**Figure 1:** (a) Tetany induced by inflating blood pressure cuff. (b) Electrocardiogram reveals tall, peaked T-waves in precordial leads (black arrows) when serum potassium was 3.0 mmol/L and serum magnesium was 0.9 mg/dl (reference: 1.6–2.5 mg/dl).

Complete blood count; blood sugar; and serum levels of creatinine, sodium, and total protein and albumin were normal. He had hypokalemia (K 3.0 mmol/L) and hypocalcemia (calcium<sub>total</sub> 7.9 mg/dl; calcium<sub>ionized</sub> 4.1 mg/dl). Serum phosphorus was normal, and intact parathormone was suppressed (3.1 pg/mL). Arterial blood gas analysis revealed normal pH and bicarbonate. Electrocardiogram revealed tall, peaked T-waves [Figure 1b]. Tall T-waves, despite hypokalemia arouse suspicion of hypomagnesemia. Serum magnesium was low (0.9 mg/dl). Urinary fractional excretion of magnesium (FEMg) was 1.3%, implying renal conservation of magnesium and loss through extra-renal route (gastrointestinal tract). A diagnosis of PPI-induced hypomagnesemia with resultant hypocalcemia and hypokalemia was made.

He received intravenous followed by oral magnesium replacement along with intravenous calcium gluconate and oral potassium chloride supplementation. Pantoprazole was stopped. Serum magnesium, calcium, and potassium returned to normal by the third day. Tetany resolved and T-wave amplitude normalized.

Hypomagnesemic tetany due to PPI was reported as early as 2006<sup>2</sup> and further studies have established the association.<sup>3,4</sup> An estimated 2–36% of patients on PPI develop hypomagnesemia.<sup>4</sup> PPI impairs the gastrointestinal absorption of magnesium by inhibiting Transient Receptor Potential Channel Melastatin 6 and 7 (TRPM6/7)

responsible for magnesium absorption in the gut.<sup>5</sup> Prolonged use (>1 year), old age, and concomitant diuretic therapy are predisposing factors for hypomagnesemia.

Fractional excretion of magnesium (FEMg) is a useful test to differentiate renal from gastrointestinal loss of magnesium. FEMg of 3% or above implies renal magnesium wasting while a lesser value indicates renal magnesium conservation in the face of gastrointestinal magnesium loss.<sup>6</sup> Hypomagnesemia induces hypoparathyroidism by reducing parathormone secretion and promoting end organ resistance to parathormone.<sup>6</sup> While hypoparathyroidism contributes to hypocalcemia, hypokalemia in hypomagnesemia is the result of renal potassium wasting. Tall T-waves despite hypokalemia should arouse suspicion of hypomagnesemia.<sup>6</sup>

#### Conflicts of interest

There are no conflicts of interest.

**Subrahmanian Sathivageesan**<sup>1</sup> 

<sup>1</sup>Department of Nephrology, Sundaram Hospital, Trichy, Tamilnadu, India

**Corresponding author:** Subrahmanian Sathivageesan,  
Department of Nephrology, Sundaram Hospital, Trichy,  
Tamil Nadu, India. E-mail: spssubrahmanian@yahoo.co.in

#### References

1. Wilhelm SM, Rjater RG, Kale-Pradhan PB. Perils and pitfalls of long-term effects of proton pump inhibitors. *Expert Rev Clin Pharmacol* 2013;6:443–51.
2. Epstein M, McGrath S, Law F. Proton-pump inhibitors and hypomagnesemic hypoparathyroidism. *N Engl J Med* 2006;355:1834–6.
3. Mackay JD, Bladon PT. Hypomagnesaemia due to proton-pump inhibitor therapy: A clinical case series. *QJM* 2010;103:387–95.
4. Srinutta T, Chewcharat A, Takkavatakarn K, Praditpornsilpa K, Eiam-Ong S, Jaber BL, *et al.* Proton pump inhibitors and hypomagnesemia: A meta-analysis of observational studies. *Medicine (Baltimore)* 2019;98:e17788.
5. Gommers LMM, Hoenderop JGJ, de Baaij JHF. Mechanisms of proton pump inhibitor-induced hypomagnesemia. *Acta Physiol (Oxf)* 2022;235:e13846.
6. Agus ZS. Hypomagnesemia. *J Am Soc Nephrol* 1999;10:1616–22.

This is an open access journal, and articles are distributed under the terms of the Creative Commons Attribution-NonCommercial-ShareAlike 4.0 License, which allows others to remix, transform, and build upon the work non-commercially, as long as appropriate credit is given and the new creations are licensed under the identical terms.

**How to cite this article:** Sathivageesan S. Tetany in a Patient with Gastroesophageal Reflux Disease. *Indian J Nephrol.* 2024;34:676-7. doi: 10.25259/IJN\_239\_2024

**Received:** 20-05-2024; **Accepted:** 01-06-2024  
**Online First:** 24-07-2024; **Published:** 28-10-2024

**DOI:** 10.25259/IJN\_239\_2024

