

Metastatic Thyroid Abscess: A Rare Presentation of Catheter-related Bloodstream Infection in an End-Stage Kidney Disease Patient on Hemodialysis

Dear Editor,

Over two-third of patients initiated on hemodialysis (HD) in India have temporary catheters as the initial venous access.^[1] Bloodstream infections caused by infection of the catheters can lead to metastatic complications like infective endocarditis and septic arthritis.^[2] We report a case of acute suppurative thyroiditis in an end-stage kidney disease (ESKD) patient with a history of prolonged use of non-tunneled catheter.

A 35-year-old male had been undergoing HD through a right internal jugular non-tunneled catheter for three months. He presented to us with complaints of high fever, chills and rigors, swelling of the neck, and dysphagia for 10 days. Local examination revealed a large, tender, warm, and fluctuant anterior neck mass [Figure 1a].

Contrast-enhanced computed tomography of the neck revealed multiple loculated hypodense collections, approximating around 90 cc and showing enhancement of walls and septa in both lobes of the thyroid: these were suggestive of acute suppurative thyroiditis [Figure 1b]. Blood cultures sent from the catheter, peripheral blood, and pus culture from the thyroid abscess grew

methicillin-resistant *Staphylococcus aureus* (MRSA). Henceforth, a diagnosis of metastatic thyroid abscess secondary to catheter-related bloodstream infection was considered.

The catheter was removed followed by ultrasound-guided drainage of the abscess and antibiotics as per culture sensitivity. There was complete resolution of the abscess [Figure 1c].

Metastatic infections have been observed in approximately 5%–10% of patients undergoing HD through central venous catheters.^[3] The tough capsule, high iodine content, and good lymphatic drainage make the thyroid gland resistant to infections.^[4] We could find only one other case^[5] that reported acute suppurative thyroiditis in an ESKD patient. CRBSI presenting as thyroid abscess is extremely rare and should always be suspected in any HD patient with painful neck swelling.

Declaration of patient consent

The authors certify that they have obtained all appropriate patient consent forms.

Financial support and sponsorship

Nil.

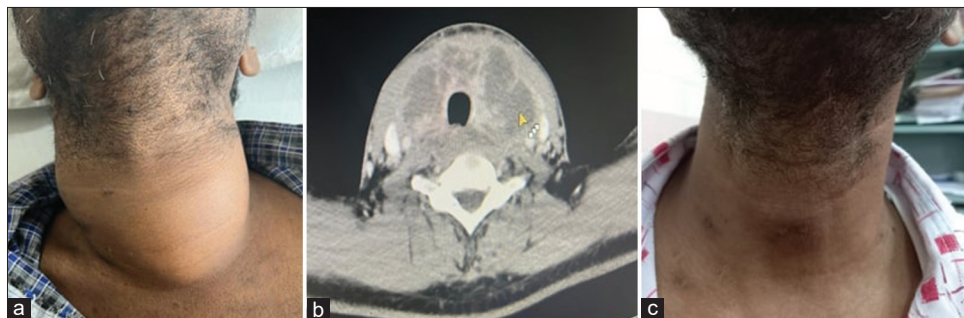


Figure 1: (a) A patient having diffuse painful neck swelling on admission. (b) Contrast-enhanced computed tomography of the neck showing multiple hypodense collections in both lobes of the thyroid and extending to the retropharyngeal space. (c) Resolution of swelling of the same patient after treatment

Conflicts of interest

There are no conflicts of interest.

**Siddharth Herur, Niranjana M,
Vijay C. Bukka, Ankit Tiwari, Srinivas N. Kinjarapu,
Prasanna Murugan, Swarnalatha Gudithi**

*Department of Nephrology, Nizams Institute of Medical Sciences,
Hyderabad, Telangana, India*

Address for correspondence:

*Dr. Siddharth Herur,
Department of Nephrology, Nizam's Institute of Medical Sciences,
Punjagutta, Hyderabad - 500 082, Telangana, India.
E-mail: siddhu.bmcricri@gmail.com*

References

- Bansal D, Kher V, Gupta KL, Banerjee D, Jha V. Haemodialysis vascular access: current practices amongst Indian nephrologists. *J Vasc Access* 2018;19:172-6.
- El Khudari H, Ozen M, Kowalczyk B, Bassuner J, Almeahi A. Hemodialysis catheters: Update on types, outcomes, designs and complications. *Semin Intervent Radiol* 2022;39:90-102.
- Farrington CA, Allon M. Management of the hemodialysis patient with catheter-related bloodstream infection. *Clin J Am Soc Nephrol* 2019;14:611-3.
- Falhammar H, Wallin G, Calissendorff J. Acute suppurative thyroiditis with thyroid abscess in adults: Clinical presentation, treatment and outcomes. *BMC Endocr Disord* 2019;19:130.
- Sulaiman S, Sethi J, Kohli HS, Gupta KL. Painful neck swelling in a patient with end-stage renal disease on haemodialysis. *BMJ Case Rep* 2019;12:e229085. doi: 10.1136/bcr-2018-229085.

This is an open access journal, and articles are distributed under the terms of the Creative Commons Attribution-NonCommercial-ShareAlike 4.0 License, which allows others to remix, tweak, and build upon the work non-commercially, as long as appropriate credit is given and the new creations are licensed under the identical terms.

Access this article online	
Quick Response Code: 	Website: https://journals.lww.com/ijon
	DOI: 10.4103/ijn.ijn_82_23

How to cite this article: Herur S, Niranjana M, Bukka VC, Tiwari A, Kinjarapu SN, Murugan P, *et al.* Metastatic thyroid abscess: A rare presentation of catheter-related bloodstream infection in an end-stage kidney disease patient on hemodialysis. *Indian J Nephrol* 2023;33:482-3.

Received: 02-03-2023; **Accepted:** 13-03-2023; **Published:** 19-05-2023

© 2023 Indian Journal of Nephrology | Published by Wolters Kluwer - Medknow