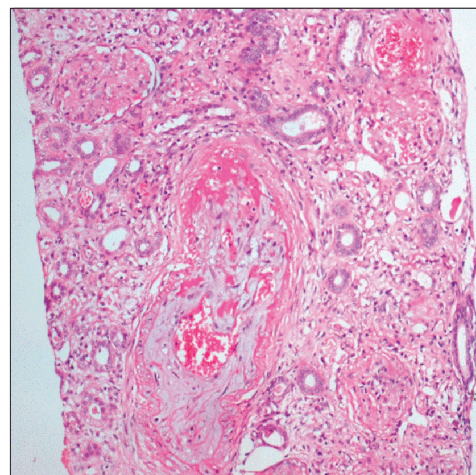


## *Plasmodium vivax* malaria presenting as hemolytic uremic syndrome

Sir,

A 20-year-old female presented with fever, chills, rigors followed by oliguria for 4 days. She had no history of any major diseases. Clinical examination revealed icterus, pallor with peripheral edema. Systemic examination was unremarkable. Her investigations revealed hemoglobin of 8.2 g/dL, platelet count of  $53 \times 1000/\text{cm}^3$ , serum bilirubin of 6.7 mg/dL (direct 2.9; indirect 3.8), and a peripheral smear showed schizonts of *Plasmodium vivax* along with schistocytes. Her serum creatinine level was 7.3 mg/dL and LDH was 2838 IU/L (normal range: 100-190 U/L). Serological tests for Hepatitis B and C, Widal test, IgM Dengue antibody, and blood and urine cultures were negative. She was initiated on hemodialysis (HD) and received IV artesunate with oral doxycycline. Though fever responded well to anti-malarial drugs, renal failure persisted with a consistent need for HD. Additional work up with immunological markers (serum complement level C3/C4, antinuclear antibody, antineutrophil cytoplasmic antibodies, and Coombs' test) were negative. We therefore performed renal biopsy which revealed that most of the glomeruli were necrosed, blood vessels showed sub-intimal fibrin deposition with muco-intimal proliferation, and luminal obliteration with organizing thrombus [Figure 1]. Immunofluorescence microscopy was unremarkable. Consequently, we considered a diagnosis of acute patchy cortical necrosis with severe thrombotic microangiopathy leading to hemolytic uremic syndrome (HUS) associated with vivax malarial infection and then she received three sessions of plasmapheresis. Although platelet count and LDH were normalized with the therapy renal function recovered partially (serum creatinine 3 mg/dL).

Questions are raised about "benign" nature of vivax malaria as it has been associated with renal failure.<sup>[1,2]</sup> Factors like volume depletion, intra-vascular hemolysis, and sepsis along with hypercatabolic state can lead to acute renal failure in vivax malaria and usually leads to acute tubular necrosis with renal recovery over 3-4 weeks depending on early diagnosis and treatment.<sup>[3,4]</sup> Our case highlights that *P. vivax* infection can lead



**Figure 1:** Renal biopsy section showing sub-intimal fibrin deposition and muco-intimal proliferation leading to luminal obliteration of a blood vessel with organizing thrombus and surrounding necrosed glomeruli (H and E,  $\times 200$  magnification)

to severe malaria with renal failure. Additionally, combination of micro-angiopathic hemolytic anemia, thrombocytopenia, and thrombotic micro-angiopathy with patchy cortical necrosis on renal histology leading to HUS indicates severe form endothelial dysfunction. The endothelial damage leading to renal failure has occasionally been described with malaria.<sup>[5]</sup> This unusual presentation of vivax malaria with HUS is novel and indicates malignant behavior of the parasite. Future studies will throw light on the association of *P. vivax* with HUS and determine the factors related with its occurrence.

**M. P. Patel, V. B. Kute, M. R. Gumber, D. N. Gera, P. R. Shah, H. V. Patel, H. L. Trivedi, A. V. Vanikar<sup>1</sup>**

Department of Nephrology and Clinical Transplantation, Institute of Kidney Diseases and Research Centre, Dr. HL Trivedi Institute of Transplantation Sciences, <sup>1</sup>Department of Pathology, Laboratory Medicine, Transfusion Services and Immunohematology, IKDRC-ITS, Ahmedabad, Gujarat, India

**Address for correspondence:**

Dr. Mohan P. Patel,

Department of Nephrology and Clinical Transplantation, Institute of Kidney Diseases and Research Centre [IKDRC], Dr. HL Trivedi Institute of Transplantation Sciences [ITS], Civil Hospital Campus, Asarwa, Ahmedabad - 380 016, Gujarat, India.  
E-mail: drmohan610@yahoo.com

### References

1. Price RN, Tjitra E, Guerra CA, Yeung S, White NJ, Anstey NM. Vivax malaria: Neglected and not benign. *Am J Trop Med Hyg* 2007;77:79-87.
2. Kochar DK, Das A, Kochar SK, Saxena V, Sirohi P, Garg S, et al. Severe *Plasmodium vivax* malaria: A report on serial

cases from Bikaner in northwestern India. *Am J Trop Med Hyg* 2009;80:194-8.

3. Jha V, Chugh KS. Acute kidney injury in malaria. In: Ronco C, Bellomo R, Kellum J, editors. *Critical Care Nephrology*. 2<sup>nd</sup> ed. Philadelphia (PA): Saunders Elsevier; 2009. p. 850-5.
4. Jha V, Chugh KS. Community-acquired acute kidney injury in Asia. *Semin Nephrol* 2008;28:330-47.
5. Elsheikha HM, Sheashaa HA. Epidemiology, pathophysiology, management and outcome of renal dysfunction associated with plasmodia infection. *Parasitol Res* 2007;101:1183-90.

Access this article online	
Quick Response Code:	Website: <a href="http://www.indianjephrol.org">www.indianjephrol.org</a>
	DOI: 10.4103/0971-4065.107217