

A New De Novo Genetic Mutation of Fabry Disease in a Young Indian Male

Dear Sir,

Fabry disease (FD) is an inherited X-linked lysosomal storage disorder due to the deficiency of alpha-galactosidase A (α -GLA) enzyme activity involved in the degradation of glycosphingolipids with consequent accumulation of globotriaosylceramide (Gb3) inside the cells. The GLA gene was mapped to the region q22.1 of the X chromosome.^[1] The X-chromosomal trait has increased the frequency of spontaneous (de novo) mutations and most of the patients/families have different mutations. Hence, the great majority of GLA mutations are unique ('private').^[2] About 5% of the patients carry a pathogenic GLA mutation and the non-disease-associated variant p.Asp313Tyr. More than 900 currently known *GLA* mutations due to missense (57%), nonsense mutations (11%), partial deletions (6%), insertions (6%) and abhorrent splicing (6%) have been identified as causing a spectrum of clinical manifestations. De novo mutations are relatively rare.^[3] We describe a young male patient with a biopsy-proven FD with negative family history and a newly detected missense variant p.Asp165Gly, which was not listed in Clinvar/HGMD2017.3.

A 24-year-old male patient presented with sudden, painless diminution of vision in his right eye (RE). He had a history of occasional migratory body aches, tingling and numbness in all four limbs and tinnitus for the past 2 years. His visual acuity was finger counting at 1 m with relative afferent pupillary defect (Marcus Gunn). Fundus examination revealed whitening of the posterior pole, cherry red spot and occluded major retinal arteries, suggesting central retinal artery occlusion. His left eye was normal. He had a visual recovery of 6/24 following anterior chamber paracentesis of RE. Systemic examination did not reveal any signs suggestive of significant neurological or cardiac illness. Blood tests showed the following results: blood group – B positive; serum creatinine – 1.5 mg/dl; and urine spot protein creatinine ratio – 0.67 g/gm. His random blood sugar, complete blood picture with ESR, serum electrolytes, liver, thyroid profile and lipid profile were within normal limits. Autoimmune workups (antinuclear antibodies, anti-dsDNA, antineutrophil cytoplasmic autoantibodies, immunoglobulin A (IgA), IgG, and IgM) were negative. His echocardiography and carotid Doppler of neck vessels were also normal.

A percutaneous renal biopsy revealed 16 glomeruli, and all of them showed podocytes with clear and lacy cytoplasm, with some of the lining epithelial cells of tubules also appearing pale and vacuolated. Interstitium showed dense inflammatory infiltrate comprising

lymphocytes and plasma cells with fibrosis. Electron microscopy examination [Figure 1] revealed mean glomerular basement membrane thickness of 317.4 nm, focal effacement (20–30%) of visceral epithelial cell foot processes, osmiophilic lamellated structures in visceral epithelial cell cytoplasm as well as in the cytoplasm of glomerular, peritubular endothelial cells, mesangial areas and tubular epithelial cells. α -GLA enzyme estimation was done by a fluorometric assay using 4-methyl umbelliferone, and the levels were found to be significantly low, i.e., 4 nmol/h/mg (normal: 45–85 nmol/h/mg). Beta-galactosidase levels were found to be normal. His eye examination did not reveal any corneal abnormality. The genetic analysis was done by DNA extraction, polymerase chain reaction and sequencing of all coding exons and flanking intronic regions. A hemizygous variant: c.[494A>G] (p.[Asp165Gly]) was noted. A missense variant p.Asp165Gly was detected that is not listed in Clinvar/HGMD2017.3 and predicted to be pathogenic by several *in silico* prediction tools. Genetic analysis was not done on the family members as none had symptoms. He was initiated on enzyme replacement therapy with intravenous injections of Agalsidase beta (Sanofi Genzyme), 60 mg, once in 15 days. During the follow-up period of 4 years, despite symptomatic improvement, his creatinine gradually increased up to 2.3 mg/dl.

Discussion

De novo mutations possess a clinical challenge in the diagnosis of the disease with variable presentation. A missense variant p.Asp165Gly was detected that is not listed in Clinvar/HGMD2017.3. Similar missense variants p.Asp165His/Tyr/Val have been reported earlier in FD.

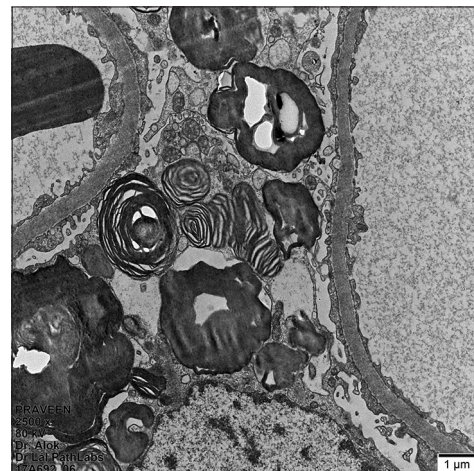

Figure 1: Osmiophilic lamellations seen in FD

There appears to be no correlation between genotype and phenotype as similar mutations can show different clinical manifestations in different patients. Also, several environmental factors including blood groups AB and B may have a more severe disease since they have an additional accumulation of glycosphingolipids in the membrane of erythrocytes of blood group B.

Many FD patients are asymptomatic till the third and fourth decade as observed in our patient, and most of the patients present with non-specific symptoms. The average duration to develop ESRD is approximately 4 years. An estimated annual decrease in glomerular filtration rate is approximately 12.2 ml/min which is significantly 'more rapid' compared to other renal diseases like diabetes and hypertension. In general, the severity of the renal condition correlates with residual enzyme activity. Branton *et al.*^[4] elucidated the renal involvement in FD in which 82% of the patients developed proteinuria at a mean age of 32 years and 22% developed chronic kidney disease, but nephrotic syndrome was rare. Our patient had insignificant proteinuria and mild renal dysfunction without other systemic manifestations.

To conclude, FD can present with a variety of clinical manifestations and de novo mutations. Studies of additional FD families will provide information about the nature and frequency of the mutations as well as the structure/function relationships of the GLA gene.

Declaration of patient consent

The authors certify that they have obtained all appropriate patient consent forms. In the form, the patient(s) has/have given his/her/their consent for his/her/their images and other clinical information to be reported in the journal. The patients understand that their names and initials will not be published and due efforts will be made to conceal their identity, but anonymity cannot be guaranteed.

Financial support and sponsorship

Nil.

Conflicts of interest

There are no conflicts of interest.

Sree Bhushan Raju, Alok Sharma¹, Anvesh Golla²

Department of Nephrology, Nizams Institute of Medical Sciences, Hyderabad, Telangana, ¹Department of Pathology, Dr Lalpathlabs National Reference Laboratories, New Delhi, ²Department of Nephrology, Nizam's Institute of Medical Sciences, Vijayawada, Andhra Pradesh, India


Address for correspondence:

Dr. Sree Bhushan Raju,
Nizams Institute of Medical Sciences, Hyderabad, Telangana, India.
E-mail: sreebhushan@hotmail.com

References

1. Desnick RJ, Ioannou YA, Eng CM. A-galactosidase deficiency: Fabry disease. In: Valle D, Beaudet AL, Vogelstein B, Kinzler KW, Antonarakis SE, Ballabio A, *et al.*, editors. The Online Metabolic and Molecular Bases of Inherited Disease. New York, NY: McGraw-Hill; 2014.
2. Ishii S, Sakuraba H, Suzuki Y. Point mutations in the upstream region of the α -galactosidase A gene exon 6 in an atypical variant of Fabry disease. Hum Genet 1992;89:29-32.
3. Brokalaki EI, Hentschke M, Grabbe S, Jansen T. Fabry disease in a female patient due to a de novo point mutation at position 691 of exon 5. Eur J Med Res 2006;11:306-8.
4. Branton MH, Schiffmann R, Sabnis SG, Murray GJ, Quirk JM, Altarescu G, *et al.* Natural history of Fabry renal disease: Influence of alpha-galactosidase A activity and genetic mutations on clinical course. Medicine (Baltimore) 2002;81:122-38.

This is an open access journal, and articles are distributed under the terms of the Creative Commons Attribution-NonCommercial-ShareAlike 4.0 License, which allows others to remix, tweak, and build upon the work non-commercially, as long as appropriate credit is given and the new creations are licensed under the identical terms.

Access this article online	
Quick Response Code: 	Website: www.indianjnephrol.org
	DOI: 10.4103/ijn.ijn_19_22

How to cite this article: Raju SB, Sharma A, Golla A. A new de novo genetic mutation of fabry disease in a young Indian male. Indian J Nephrol 2022;32:392-3.

Received: 15-01-2022; **Accepted:** 15-03-2022; **Published:** 16-07-2022

© 2022 Indian Journal of Nephrology | Published by Wolters Kluwer - Medknow