



Enamel Renal Gingival Syndrome: A Rare Form of Dystrophic Gingival Calcification with Nephrocalcinosis

Enamel renal syndrome (ERS; OMIM 204690) is a rare autosomal recessive disorder characterized by hypoplastic amelogenesis imperfecta, failed tooth eruption, intrapulpal calcifications, gingival enlargement, and nephrocalcinosis.^{1,2}

A 12-year-old boy presented with poor enamel formation, noticed by his parents, since early infancy. He was otherwise asymptomatic and developmentally normal for his age, with weight and height being between the 75th and 90th centile for his age. He was normotensive and had normal head-to-toe and systemic examination, except small widely spaced teeth with a yellowish brown discoloration with absent enamel layer [Figure 1a]. His investigations were all within normal limits, except nephrocalcinosis

and multiple small calculi in both the kidneys on ultrasonography of the kidneys [Figure 1b]. Histopathology of gingival tissue from the upper premaxillary region showed dystrophic gingival calcifications. Genetic workup proved compound heterozygous pathogenic mutation in *FAM20A* gene and the patient was diagnosed with amelogenesis imperfecta type 1G (enamel renal syndrome or ERS). This mutation was also confirmed on Sanger sequencing [Figure 1c].

ERS is a rare autosomal recessive disorder that is characterized by amelogenesis imperfecta of the hypoplastic type and nephrocalcinosis (OMIM #204690). It presents with presence of a thin enamel or absence of it, delayed dental eruption, intrapulpal calcifications, bilateral nephrocalcinosis with normal plasma calcium level, and normal renal function tests

**Maj Priyamol TM¹,
Maj Shruti¹,
Sachendra Badal²,
Suprita Kalra²**

¹Resident Pediatrics, Armed Forces Medical College, Pune, Maharashtra, ²Department of Pediatrics, Command Hospital, Pune, Maharashtra, India

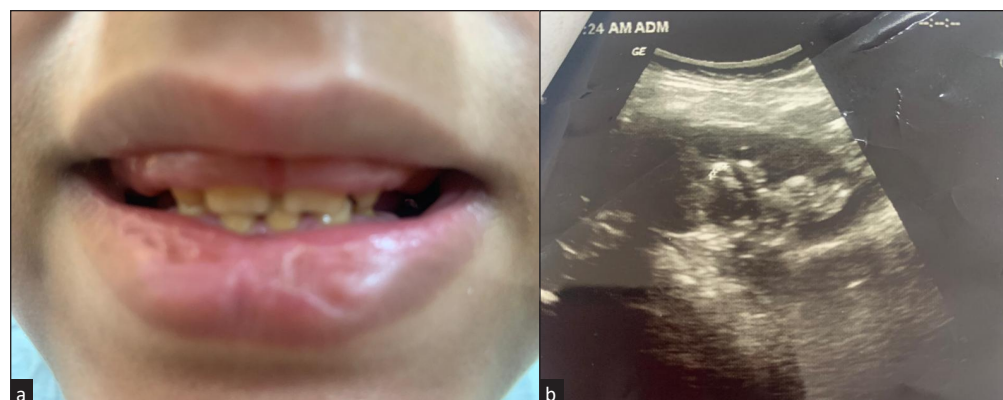
Corresponding author:

Suprita Kalra, Department of Pediatrics, Command Hospital, Pune, Maharashtra, India.
E-mail: kalrasuprita@gmail.com

DOI: 10.25259/ijn_162_23



Received: 28-04-2023
Accepted: 24-05-2023
Published: 10-04-2024



LIKELY COMPOUND HETEROZYGOUS VARIANTS CAUSATIVE OF THE REPORTED PHENOTYPE WERE IDENTIFIED						
Gene* (Transcript)	Location	Variant	Zygoty	Disease (OMIM)	Inheritance	Classification
FAM20A (-) (ENST00000592554.2)	Intron 9	c.1302-1G>C (3' Splice Site)	Heterozygous	Amelogenesis imperfecta type 1G (enamel-renal syndrome)	Autosomal recessive	Pathogenic
	Intron 10	c.1362-2A>G (3' Splice Site)	Heterozygous			Pathogenic

Figure 1: Yellowish brown discoloration of teeth with absent enamel layer and gingival thickening. (a) Amelogenesis imperfecta with thin enamel, (b) bilateral nephrocalcinosis seen on Ultrasound of the kidneys, (c) compound heterozygous pathogenic variant detected in the child on Whole exome sequencing with bold values highlighting the pathogenic variant. OMIM: Online Mendelian Inheritance in Man.

This is an open access journal, and articles are distributed under the terms of the Creative Commons Attribution-NonCommercial-ShareAlike 4.0 License, which allows others to remix, tweak, and build upon the work non-commercially, as long as appropriate credit is given and the new creations are licensed under the identical terms.

How to cite this article: Maj Priyamol TM, Shruti M, Badal S, Kalra S. Enamel Renal Gingival Syndrome: A Rare Form of Dystrophic Gingival Calcification with Nephrocalcinosis. Indian J Nephrol. 2024;34:199–200. doi: 10.25259/ijn_162_23.

due to an underlying mutation in the *FAM20A* gene. Only a few cases have been reported worldwide with the complete spectrum of hypoplastic enamel and nephrocalcinosis as described first by MacGibbon.³ ERS should be suspected in children with absent/abnormal enamel.

Acknowledgement

Surg. Capt. Dr. Chengappa, Orthodontist, INHS ASVINI.

Ethical approval

Institutional Review Board approval is not required.

Declaration of patient consent

The authors certify that they have obtained all appropriate patient consent.

Financial support and sponsorship

Nil.

Conflicts of interest

There are no conflicts of interest.

Use of artificial intelligence (AI)-assisted technology for manuscript preparation

The authors confirm that there was no use of artificial intelligence (AI)-assisted technology for assisting in the writing or editing of the manuscript and no images were manipulated using AI.

References

1. Jaureguiberry G, De la Dure-Molla M, Parry D, Quentric M, Himmerkus N, Koike T, *et al.* Nephrocalcinosis (enamel renal syndrome) caused by autosomal recessive *FAM20A* mutations. *Nephron Physiol* 2012;122:1-6.
2. Farias MLM, Ornela GO, de Andrade RS, Martelli DRB, Dias VO, Júnior HM. Enamel renal syndrome: A systematic review. *Indian J Nephrol* 2021;31:1-8. doi: 10.4103/ijn.IJN_27_19.
3. MacGibbon D. Generalized enamel hypoplasia and renal dysfunction. *Aust Dent J* 1972;17:61-3.