

Terry's nails

B. S. Lakshmi, R. Ram, V. S. Kumar

Department of Nephrology, Sri Venkateshwara Institute of Medical Sciences, Tirupati, Andhra Pradesh, India

A 45-year-old male renal allograft recipient with chronic allograft nephropathy was on tacrolimus, mycophenolate mofetil and steroids. He was not a diabetic. He was hypertensive with blood pressure under control. On examination of his nails, All finger nails were dull white with brownish pink pigmentary band at the distal portion measuring 3 mm band width suggestive of Terry's nails [Figure 1].

Richard Terry was the first to describe this abnormality in the nails in patients of cirrhosis. He described it in 82 of 100 consecutive patients with cirrhosis.^[1] His description was white nail bed showing ground-glass opacity not affected by venous congestion and indistinguishable from the lunula with a 1–2 mm distal band of normal pink. However, Terry's criteria were later revised: The distal band width may be between 0.5 mm and 3 mm, can be brown in color and the proximal nail bed can be light pink.^[2] Terry's nails are the result of changes in the nail bed vascularity, a decrease in the proximal portion and the increase in the distal edge. Usually, all the nails are affected uniformly. Biochemical data correlation in association with Terry's nails revealed no relation with hypoalbuminemia and anemia but, abnormal ratio of estrogen to androgen and abnormal steroid metabolism were identified.^[2] In one report, this nail change has preceded the renal impairment.^[3]

Often, Lindsay's (half and half) nails are needed to be considered in the differential diagnosis. In Terry's nail, the proximal three-fourth of the nail is dull pale while the distal one-fourth was pink or red, Lindsay nails appear split where the proximal half (20–60%) of the nail is opaque,

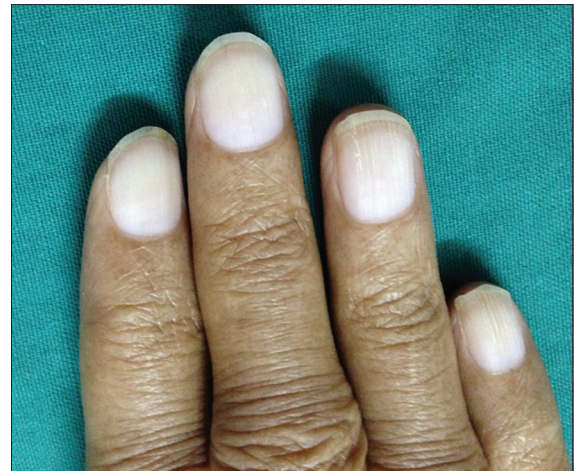


Figure 1: Terry's nails

and the distal half (40–80%) is pink to red-brown.^[4] These half and half nails may be found in approximately 10–40% of patients with chronic renal disease.^[5]

Terry's nail is described in congestive cardiac failure, adult onset diabetes mellitus, peripheral vascular disease, chronic renal failure,^[6] peritoneal dialysis,^[7] hemodialysis and renal transplant patients^[8] and in human immunodeficiency disease.

References

1. Terry R. White nails in hepatic cirrhosis. *Lancet* 1954;266:757-9.
2. Holzberg M, Walker HK. Terry's nails: Revised definition and new correlations. *Lancet* 1984;1:896-9.
3. Nia AM, Ederer S, Dahlem KM, Gassanov N, Er F. Terry's nails: A window to systemic diseases. *Am J Med* 2011;124:602-4.
4. Bean WB. A discourse on nail growth and unusual fingernails. *Trans Am Clin Climatol Assoc* 1962;74:152-67.
5. Lindsay PG. The half-and-half nail. *Arch Intern Med* 1967;119:583-7.
6. Raffle EJ. Terry's nails. *Lancet* 1984;1:1131.
7. Ozturk P, Ozyurt K, Kurutas E, Kalender M, Atasevend A, Dogan E. Nail disorders in patients with chronic renal failure undergoing peritoneal dialysis. *World J Nephrol Urol* 2014;3:30-4.
8. Al-Hamamy HR, Al-Mashhadani SA, Fadheel BM, Salman SH. Nail changes in hemodialysis patients and renal transplant recipients (a case-control study). *Am J Dermatol Venereol* 2014;3:30-4.

Address for correspondence:

Dr. R. Ram, Department of Nephrology, Sri Venkateshwara Institute of Medical Sciences, Tirupati, Andhra Pradesh, India.
E-mail: ram_5_1999@yahoo.com

Access this article online	
Quick Response Code:	Website: www.indianjnephrol.org
	DOI: 10.4103/0971-4065.146030

How to cite this article: Lakshmi BS, Ram R, Kumar VS. Terry's nails. *Indian J Nephrol* 2015;25:184.

Source of Support: Nil, **Conflict of Interest:** None declared.