



## A Rare Case of Tuberculosis Masquerading as Collapsing Glomerulopathy

### Abstract

Collapsing glomerulopathy (CG), usually presents with renal dysfunction, hypertension and proteinuria. The etiology is uncertain, yet a number of associations, including many viral infections commonly have been reported. Tuberculosis (TB), one of the most common infections, is not known to cause CG. We report a case of severe renal dysfunction requiring dialysis who had collapsing glomerulopathy on biopsy and evidence of active pulmonary tuberculosis. Anti-tubercular therapy alone resulted in improvement in kidney function.

**Keywords:** Tuberculosis, Collapsing glomerulopathy, Antitubercular therapy, Immune dysregulation, Renal recovery

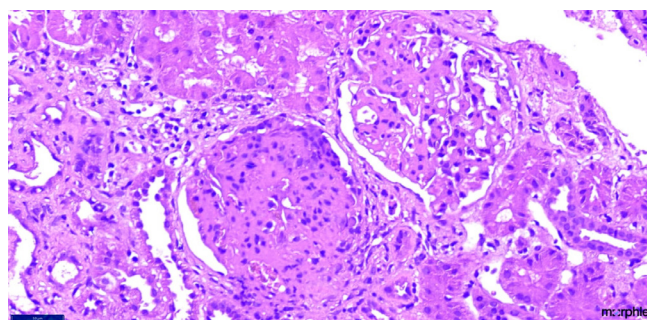
### Introduction

Collapsing glomerulopathy (CG) is a clinicopathologic entity characterized by severe nephrotic syndrome and greater kidney function impairment than other histological variants of Focal segmental Glomerulosclerosis (FSGS) and carries a bad prognosis.<sup>1</sup> HIV infection is a common cause of CG. In non-HIV population, most of the cases of CG are idiopathic, but a number of other disorders, including autoimmune, malignancy, genetic, and drug-induced collapsing glomerulopathies have been reported.<sup>2</sup> Though tuberculosis is very commonly seen in India, there are only a few case reports suggesting tuberculosis as a secondary cause of CG. Here, we report a case of biopsy-proven CG with active pulmonary tuberculosis treated by anti-tubercular therapy.

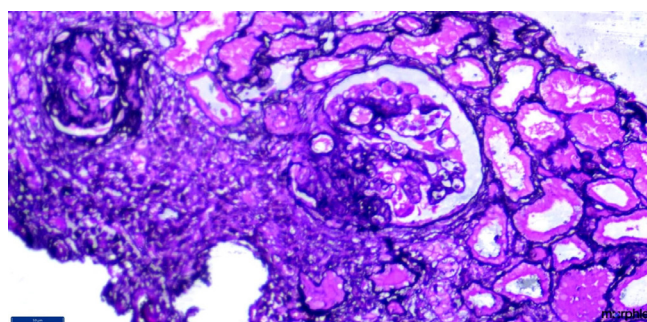
### Case Report

A 45-year-old male, presented with pedal edema and oliguria. He denied dysuria, hematuria, pyuria, fever, cough, SOB, weight and appetite changes. On examination, pallor was detected along with pedal edema, without lymphadenopathy; his blood pressure was 120/70 mmHg. Systemic examination revealed coarse rales bilaterally in lung bases. His investigations showed hemoglobin of 7.0 gm/dl, with leucocytosis and serum creatinine of 3.5 mg/dl with urinalysis showing proteins 4+, 18–20 Rbc, and plenty of pus cells. ANA and Anti ds DNA, ANCA were negative. He was started on dialysis. His chest X-ray showed left upper and middle lobe infiltrates. High resolution computed tomography (HRCT) chest showed patchy consolidation in the left upper lobe, fibrosis in both upper lobes with dilated pulmonary arteries.

On further probing, the patient gave a history of cough on and off which was not fully improving with antibiotics and antitussives. Meanwhile, kidney biopsy, was done and was reported as collapsing FSGS [Figures 1 and 2]. The other causes of FSGS (HIV, HBSAG and HCV, CMV and Parvoviral PCR) were negative. His mantoux was 15 mm; his induced sputum was negative for acid fast bacilli. Bronchoalveolar lavage samples after bronchoscopy were positive for acid fast bacilli. He was started on ATT. One week after starting ATT, his urine output increased to 1.5 liter, and he was



**Figure 1:** Renal biopsy (40x magnification in H and E staining) depicting two glomeruli; the upper glomerulus is showing segmental sclerosis (9 to 12 o'clock position) while the lower glomerulus is showing pseudocrescent with collapse of the glomerular tuft.



**Figure 2:** Renal biopsy (40x magnification in silver stain) showing two glomeruli; the one on the right side of the field is showing segmental sclerosis from 6 to 9 o'clock position with podocyte hyperplasia and collapsed glomerular tuft.

discharged with creatinine of 5.0 mg/dl. One month after starting ATT, he had a serum creatinine of 3.2 mg/dl.

### Discussion

CG is a recognized variant of FSGS, known to be associated with infections. However, only a few cases associated with pulmonary TB have been reported in the literature.<sup>3,4</sup> Immune dysregulation due to infections in a genetically susceptible individual was causing changes in glomerulus consistent with CG.<sup>5,6</sup> Coventry and Shoemaker reported steroid-resistant nephrotic syndrome in pulmonary TB. In view of absence of the usual associations, infection was the sole known risk factor.<sup>3</sup> Another case of TB-related CG requiring dialysis for 5 months but with full renal recovery

after TB treatment and corticosteroid therapy was reported by Rodrigues *et al.*<sup>4</sup> Currently, there is no specific treatment for CG. However, steroids or immunosuppressive agents have been tried in idiopathic FSGS.<sup>5,6</sup> Our patient responded to ATT, with improved urine output and improvement in kidney function. However, long-term follow-up is needed to assess the progression of renal disease in this patient.

### Declaration of patient consent

The authors certify that they have obtained all appropriate patient consent.

### Conflicts of interest

There are no conflicts of interest.

**Vishnu Keerthana Kotha<sup>1</sup>, Vijay Chander Bukka<sup>1</sup>,  
M. Niranjana<sup>1</sup>, Ankit Tiwari<sup>1</sup>, Siddharth Herur<sup>1</sup>,  
G. Swarnalatha<sup>1</sup>**

<sup>1</sup>Department of Nephrology, Nizam's Institute of Medical Sciences,  
Hyderabad, Telangana, India.

#### Corresponding author:

Vijay Chander B, Department of Nephrology, Nizam's Institute of Medical  
Sciences, Hyderabad, Telangana, India.  
E-mail: vijaychander.bukka@gmail.com

### References

1. Thomas DB, Franceschini N, Hogan SL, Ten Holder S, Jennette CE, Falk RJ, *et al.* Clinical and pathologic characteristics of focal segmental glomerulosclerosis pathologic variants. *Kidney Int* 2006;69:920–6.
2. Nicholas Cossey L, Larsen CP, Liapis H. Collapsing glomerulopathy: A 30-year perspective and single, large center experience. *Clin Kidney J* 2017;443–9.
3. Coventry S, Shoemaker LR. Collapsing glomerulopathy in a 16-year-old girl with pulmonary tuberculosis: The role of systemic inflammatory mediators. *Pediatr Dev Pathol* 2004;7:166–70.
4. Rodrigues CE, Sette LH, Torritani J, Malheiros DM, Titan SM, Barros RT, *et al.* Tuberculosis-associated collapsing glomerulopathy: Remission after treatment. *Ren Fail* 2010;32:143–6.
5. Albaqumi M, Soos TJ, Barisoni L, Nelson PJ. Collapsing glomerulopathy. *J Am Soc Nephrol* 2006;17:2854–63.
6. Albaqumi M, Barisoni L. Current views on collapsing glomerulopathy. *J Am Soc Nephrol* 2008;19:1276–81.

This is an open access journal, and articles are distributed under the terms of the Creative Commons Attribution-NonCommercial-ShareAlike 4.0 License, which allows others to remix, tweak, and build upon the work non-commercially, as long as appropriate credit is given and the new creations are licensed under the identical terms.

**How to cite this article:** Kotha VK, Bukka VC, Niranjana M, Tiwari A, Herur S, Swarnalatha G. Tuberculosis - A Rare Case of Tuberculosis Presenting as Collapsing Glomerulopathy. *Indian J Nephrol*. doi: 10.25259/ijn\_443\_23

**Received:** 12-01-2024; **Accepted:** 17-03-2024;

**Online First:** 17-06-2024; **Published:** \*\*\*

**DOI:** 10.25259/ijn\_443\_23

