



## Hydroxychloroquine-Induced Phospholipidosis – A Forgotten Complication of a Common Drug

### Abstract

Hydroxychloroquine (HCQ) has immunomodulatory and immunosuppressive properties and is used in many rheumatological conditions like systemic lupus erythematosus, rheumatoid arthritis, and Sjogren's syndrome. It is usually a widely used and well-tolerated DMARD (Disease Modifying Anti Rheumatic Drugs). Its most feared toxicities include retinopathy and, rarely, cardiomyopathy. Among its other reported side effects is drug-induced phospholipidosis. Here, we report two cases of HCQ-induced phospholipidosis based on renal biopsy electron microscopy. HCQ-induced phospholipidosis, although uncommon, must be considered as one of the differentials in a patient with persistent proteinuria.

**Keywords:** *Hydroxychloroquine, phospholipidosis, proteinuria*

### Introduction

Hydroxychloroquine (HCQ) has both immunomodulatory and immunosuppressive properties and is used in many rheumatological conditions like systemic lupus erythematosus (SLE), rheumatoid arthritis, and Sjogren's syndrome. It is usually a widely used and well-tolerated DMARD. Its most feared toxicities include retinopathy and rarely, cardiomyopathy. Among its other reported side effects is drug-induced phospholipidosis. These kinds of lesions are also specifically observed in Fabry's disease (FD), an X-linked inborn deficiency of the lysosomal enzyme  $\alpha$ -galactosidase A that causes an accumulation of globotriaosylceramide. Here, we present two cases of HCQ-induced phospholipidosis in systemic lupus erythematosus and rheumatoid arthritis, which mimics FD.

### Case 1

A 54-year-old lady presented in 2019 with a 3-year history of inflammatory polyarthritis, photosensitivity, oral ulcers, alopecia, and multiple painless nodular lesions over the face and the upper arms. She was previously given steroids, with which she had improvement in her symptoms. On examination, these lesions were non erythematous and non tender, with areas of lipoatrophy. On evaluation, she was found to have antinuclear antibody (ANA) 2+ positivity with centromere pattern and

normal double-stranded DNA levels and complements levels with elevated 24-h urine protein of 602 mg/day. Detailed laboratory investigations are enlisted in Table 1. Skin biopsy of the lesions showed predominantly lobular panniculitis with septal infiltration suggestive of lupus panniculitis. Renal biopsy showed Class 2 lupus nephritis with immunofluorescence positivity for IgG, IgM, and C1q. She was started on 1 mg/kg prednisolone equivalent dose of steroids, mycophenolate (MMF) 2g/day, HCQ 300 mg/day, and antiproteinuric measures with losartan 50 mg/day. She had improvement in her skin lesions, with complete resolution of proteinuria after 1 year. Her steroids were slowly tapered and stopped, and she was continued on MMF and HCQ. In February 2021, on routine evaluation, she was found to have proteinuria of 931 mg/day; however, she was clinically asymptomatic. Since she was in serological remission at that point, her antiproteinuric measures were optimized and planned for a close follow-up. There was an increase in proteinuria to 1500 mg/day after 4 months, at which point a repeat renal biopsy was performed. The light microscopy was suggestive of focal segmental glomerulosclerosis with interstitial fibrosis (<5%) and tubular injury with IgG and C3 deposits on immunofluorescence staining. However, the electron microscopy

**Nagamounika Kothapalli<sup>1</sup>, Shivraj Padiyar<sup>1</sup>, Aswin M. Nair<sup>2</sup>, Prathyusha Manikuppam<sup>1</sup>, Smitha M. Matthai<sup>1</sup>, Sanjeet Roy<sup>1</sup>, Anna Pulimood<sup>1</sup>, Suceena Alexander<sup>1</sup>, John Mathew<sup>1</sup>**

<sup>1</sup>Department of Clinical Immunology and Rheumatology, Christian Medical College, Vellore, Tamil Nadu,

<sup>2</sup>Department of Rheumatology, Travancore Medical College Hospital, Kollam, Kerala, India

### Corresponding author:

Dr. John Mathew,  
Department of Clinical Immunology and Rheumatology, Christian Medical College, Vellore, Tamil Nadu, India.  
E-mail: johnmathewtvm@hotmail.com

DOI: 10.4103/ijn.ijn\_325\_22



**Received:** 30-09-2022  
**Accepted:** 31-01-2023  
**Online First:** 04-08-2023  
**Published:** 10-04-2024

This is an open access journal, and articles are distributed under the terms of the Creative Commons Attribution-NonCommercial-ShareAlike 4.0 License, which allows others to remix, tweak, and build upon the work non-commercially, as long as appropriate credit is given and the new creations are licensed under the identical terms.

**How to cite this article:** Kothapalli N, Padiyar S, Nair AM, Manikuppam P, Matthai SM, Roy S, *et al.* Hydroxychloroquine-Induced Phospholipidosis – A Forgotten Complication of a Common Drug. *Indian J Nephrol.* 2024;34:175–7. doi: 10.4103/ijn.ijn\_325\_22

[Figure 1] revealed 30%–40% foot process effacement with multiple podocytes showing myelin-like inclusion bodies in the cytoplasm, a feature mimicking lipid storage disorders like FD. Given the long duration of intake of HCQ and no features favoring a possibility of FD (acral paresthesias, angiokeratomas, family history, male sex), a drug-induced etiology, most probably due to HCQ, was thought of. HCQ was stopped. She, however, continues to have the same amount of proteinuria at 1 year of follow-up.

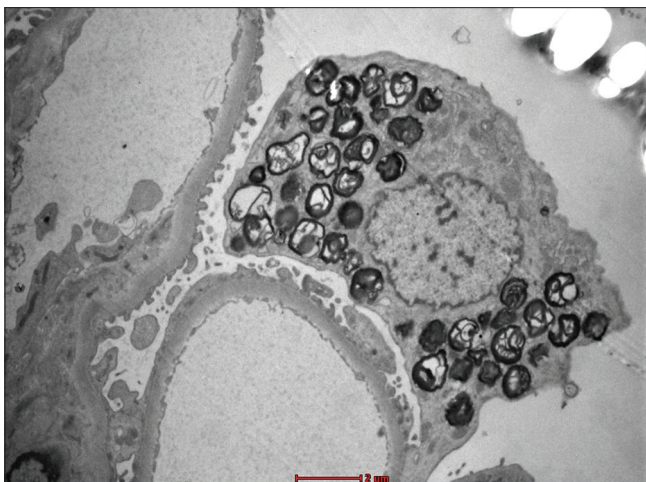
## Case 2

A 59-year-old lady, a known patient of rheumatoid arthritis since 2008, with interstitial lung disease diagnosed in 2014, on regular treatment with MMF and HCQ presented to us in 2017 with complaints of pedal edema and facial puffiness. On evaluation, she was found to have proteinuria of 1700 mg/day. Her urine routine was bland, with normal serological parameters [Table 1]. Renal

**Table 1: Summary of laboratory investigations of case 1 and case 2**

	Case 1	Case 2	Normal range
Hemoglobin (g/dl)	12.1	10	12
Total WBC count, cells/mm <sup>3</sup>	4200	6500	4000–11,000
Platelets, cells/mm <sup>3</sup>	2,30,000	3,20,000	1.5-4 lakh
SGPT (IU/l)	30	15	<35
Creatinine (g/dl)	0.6g	0.5 mg	0.5-1.2
24-hurine protein (mg)	905	1700	0-150 mg
ANA (by IIF)	2+centromere	Negative	Negative
Anti-dsDNA (IU/ml)	2	NA	<100
C3 (mg/dl)	101	NA	90–180 mg/dl
C4 (mg/dl)	20		10–40 mg/dl
Anti-CCP (RU/ml)	NA	355	<20

ANA=antinuclear antibody, anti-CCP=anti-cyclical citrullinated peptide, anti-dsDNA=anti-double-stranded DNA, SGPT=serum glutamic pyruvic transaminase, WBC=white blood cell, IIF= Indirect immunofluorescence

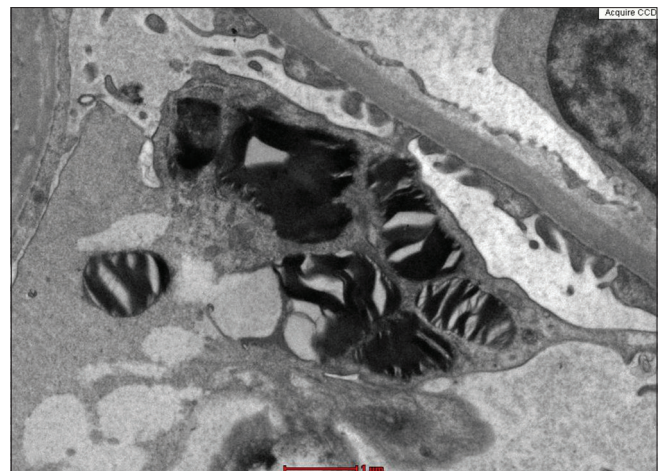


**Figure 1:** Podocyte cytoplasm displaying multiple osmiophilic, irregular, lamellated structures (transmission electron microscopy, magnification ×4200).

biopsy on light microscopy showed foamy vacuolations in podocytes with no interstitial or tubular changes. Electron microscopy [Figure 2] revealed ultrastructural features suggestive of phospholipidosis – lamellated, vacuolated, and zebra inclusion bodies in podocytes. She had no clinical features of FD and in the given context, it was considered to be drug-induced phospholipidosis, the culprit drug being HCQ. HCQ was stopped in 2017, but she persisted to have proteinuria of 1200 mg/day in 2022.

## Discussion

Here, we present two cases of HCQ-induced phospholipidosis in the podocytes presenting with proteinuria. There are only a handful of cases documented in the literature [Table 2], most of which are in lupus. HCQ and chloroquine (CQ) are part of the long-term treatment armamentarium in SLE. Although they are considered to be generally safe, there can be some rare potentially severe toxicities. One of its rare reported adverse effects is phospholipidosis. Drug-induced phospholipidosis has been described in the literature with drugs like amiodarone,<sup>1</sup> HCQ, and CQ. CQ and HCQ are amphiphilic lysosomotropic substances, which can cause lysosomal damage. CQ and HCQ are weak bases that cross the lysosomal membrane and become concentrated therein by protonation. The resulting increase in lysosomal pH leads to the inactivation of lysosomal enzymes such as galactosidase A, cathepsin, acid hydrolase, and phospholipases, resulting in lipidosis.<sup>2</sup> Although predominantly podocytes are affected, it can affect a variety of cells including parietal and visceral epithelial cells, endothelium, mesangial cells, and distal and proximal tubular epithelium.<sup>3</sup> Subsequently, mesangial expansion and glomerulosclerosis, finally leading to interstitial fibrosis and tubular atrophy can occur. One of the close differentials to consider in such scenarios is a lipid storage disorder like FD, which demonstrates whorled layers of alternating dense and pale material (“zebra bodies” or myelin figures) in the podocytes.<sup>4</sup> In the cases described here, FD was considered



**Figure 2:** Podocytes filled with zebra body inclusions and myelinoid figures (transmission electron microscopy, magnification 9900×).

**Table 2: Previous cases reported in the literature on CQ/HCQ phospholipidosis**

	Underlying disease	Age/sex	Drug	Response after discontinuing CQ/HCQ
Muller-Hocker <i>et al.</i> <sup>5</sup>	pSS	46/F	CQ	Renal parameters recovered to as before starting CQ
Albay <i>et al.</i> <sup>3</sup>	RA	56/F	CQ	Renal functions normalized after 1 year of discontinuation
Bracamonte <i>et al.</i> <sup>6</sup>	Inflammatory polyarthritis	56/F	HCQ	Slight improvement of proteinuria
Woywodt <i>et al.</i> <sup>7</sup>	SLE	70/F	HCQ	
Costa <i>et al.</i> <sup>8</sup>	SLE	31/F	HCQ	Stable creatinine clearance
Khubchandani and Bichle <sup>9</sup>	SLE	30/F	HCQ	Renal function remained stable
De Menezes Neves <i>et al.</i> <sup>10</sup>	SLE	28/F	HCQ	Renal function remained stable
Navratil and Jureković <sup>11</sup>	SLE	14/F	HCQ	No renal progression after discontinuation of HCQ
Brealey and Carroll <sup>12</sup>	SLE	46/F	HCQ	Proteinuria resolved
Bojic <i>et al.</i> <sup>13</sup>	SLE	26/F	HCQ, CQ	Slight improvement in patient's renal function
Sperati and Rosenberg, 2018 <sup>14</sup>	SLE	27/F	HCQ	Proteinuria significantly improved
Serre <i>et al.</i> <sup>15</sup>	SLE	36/F	HCQ	Proteinuria significantly improved No effect on proteinuria, stable renal function

CQ=chloroquine, HCQ=hydroxychloroquine, pSS=primary Sjogren syndrome, RA=rheumatoid arthritis, SLE=systemic lupus erythematosus

unlikely, as both the patients were females with a negative family history, while FD is an X-linked recessive disease. Both the cases had no other clinical features of FD like angiokeratomas, acroparesthesias, or corneal involvement. Treatment is mainly stoppage of the drug. The reversibility of podocyte injury is variable as seen in various studies. While some patients had marked resolution of proteinuria,<sup>5</sup> the rest had only marginal reduction<sup>6,7</sup> [Table 2].<sup>3,5-15</sup> This article also highlights the importance of considering other differentials of proteinuria in a lupus patient, especially when the patient is on adequate immunosuppression and clinical and serological remission. Electron microscopy is an important added investigation, along with routine histopathology which one should consider while encountering these kinds of cases.

## Conclusion

HCQ-induced phospholipidosis, although uncommon, must be considered as one of the differentials in a patient with persistent proteinuria.

## Declaration of patient consent

The authors certify that they have obtained all appropriate patient consent. Informed written consent was taken from the patient for publication.

## Financial support and sponsorship

Nil.

## Conflicts of interest

There are no conflicts of interest.

## References

- Liu FL, Cohen RD, Downar E, Butany JW, Edelson JD, Rebeck AS. Amiodarone pulmonary toxicity: functional and ultrastructural evaluation. *Thorax* 1986;41:100-5.
- Hostetler KY, Richman DD. Studies on the mechanism of phospholipid storage induced by amantadine and chloroquine in Madin Darby canine kidney cells. *Biochem Pharmacol* 1982;31:3795-9.
- Albay D, Adler SG, Philipose J, Calescibetta CC, Romansky SG, Cohen AH. Chloroquine-induced lipidosis mimicking Fabry disease. *Mod Pathol* 2005;18:733-8.
- Huang X, Zhang R. Zebra bodies in the kidney. *N Engl J Med* 2020;383:e2.
- Muller-Hocker J, Weiss SM, Dendorfer U, Braun GS. Chloroquine-induced phospholipidosis of the kidney mimicking Fabry disease: Case report and review of literature. *Hum Pathol* 2003;34:285-9.
- Bracamonte ER, Kowalewska J, Starr J, Gitomer J, Alpers CE. Iatrogenic phospholipidosis mimicking Fabry disease. *Am J Kidney Dis Off J Natl Kidney Found* 2006;48:844-50.
- Woywodt A, Hellweg S, Schwarz A, Schaefer RM, Mengel M. A wild zebra chase. *Nephrol Dial Transplant* 2007;22:3074-7.
- Costa RM, Martul EV, Reboredo JM, Cigarrán S. Curvilinear bodies in hydroxychloroquine-induced renal phospholipidosis resembling Fabry disease. *Clin Kidney J* 2013;6:533-6.
- Khubchandani SR, Bichle LS. Hydroxychloroquine-induced Phospholipidosis in a Case of SLE: The wolf in zebra clothing. *Ultrastruct Pathol* 2013;37:146-50.
- De Menezes Neves PDM, Machado JR, Custódio FB, dos Reis Monteiro MLG, Iwamoto S, Freire M, *et al.* Ultrastructural deposits appearing as "zebra bodies" in renal biopsy: Fabry disease?- comparative case reports. *BMC Nephrol* 2017;18:157.
- Navratil M, Jureković II. Chloroquine toxicity misdiagnosed as Fabry disease associated with systemic lupus erythematosus and hashimoto thyroiditis. *J Rheumatol* 2017;44:1940.
- Brealey J, Carroll R. Hydroxychloroquine-induced phospholipidosis in a renal transplant patient. *Ultrastruct Pathol* 2017;41:124-5.
- Bojic M, Kozakowski N, Bécède M, Kerschbaumer A, Bobacz K. The Case | Myeloid bodies in the kidney biopsy of a patient with systemic lupus erythematosus. *Kidney Int* 2017;92:271-2.
- Sperati CJ, Rosenberg AZ. Hydroxychloroquine-induced mimic of renal Fabry disease. *Kidney Int* 2018;94:634.
- Serre J, Buob D, Boffa J-J. Hydroxychloroquine-induced podocytopathy mimicking Fabry disease. *BMJ Case Rep* 2019;12:e228876. Ibul consta L. Quod inatratus hocul coninat videes nonsulegit cum omnemen tracipsedo, que est cem asuspera equit? Fuis rem sulis se con hiliaedo, se fac mena mod