

Thrombotic microangiopathy: An unusual cause of renal failure in rheumatoid arthritis

R. Sakthirajan, J. Dhanapriya, T. Dineshkumar, N. Gopalakrishnan, S. Murugan, T. Balasubramaniyan

Department of Nephrology, Madras Medical College and Rajiv Gandhi Government General Hospital, Chennai, Tamil Nadu, India

ABSTRACT

Rheumatoid arthritis (RA) is one of the commonest rheumatological diseases. Renal involvement is not common but can occur as a result of chronic inflammation as part of disease process or drug toxicity. Thrombotic microangiopathy (TMA) is characterized by microangiopathic hemolytic anemia, thrombocytopenia, and organ failure of variable severity. Only a few cases of TMA in patients with RA were reported to date. We describe a 45-year-old female patient with RA who presented with oliguria and edema. Renal biopsy showed TMA with patchy cortical necrosis. She improved with hemodialysis and plasmapheresis.

Key words: Hemodialysis, plasmapheresis, renal biopsy, rheumatoid arthritis

Introduction

Renal disease in rheumatoid arthritis (RA) is usually asymptomatic and is detected only on biochemical investigations.^[1] Manifestations include glomerulonephritis, amyloidosis, tubulointerstitial nephritis, and drug toxicity.^[2] Thrombotic microangiopathy (TMA) results in thrombocytopenia, microangiopathic hemolytic anemia (MAHA), and thrombotic occlusion of the microvasculature.^[3] Primary TMA includes hemolytic-uremic syndrome (HUS) and thrombotic thrombocytopenic purpura (TTP). Secondary TMA is associated with neoplasia, autoimmune diseases (antiphospholipid antibody syndrome, systemic lupus erythematosus (SLE), and others), infections, and drugs.^[4] We report here a female patient with RA who developed TMA and improved subsequently with plasmapheresis.

Case Report

A 45-year-old woman presented with oliguria and edema for 2 days. She was known to have RA and was taking oral steroids and diclofenac tablets on and off as self-medication. There was no history of diarrhea, fever, native medication, or any other drug intake. On examination, she had edema legs, pulse rate of 80/min, and blood pressure of 130/80 mm/Hg. Urinalysis showed 3 + protein, 5–6 red cells/hpf; urine protein creatinine ratio 2.8. Hemoglobin was 9.2 g/dl; total count 5600/cu.mm; platelet count 80,000/cu.mm; peripheral smear numerous schistocytes; blood urea 200 mg/dl; serum creatinine 12 mg/dl; prothrombin time 12.3 s; INR 0.9; activated partial thromboplastin time 38.5 s; serum lactate dehydrogenase (LDH) 931 IU/L; total bilirubin 1.2 mg/dl; indirect bilirubin 0.8 mg/dl; and direct Coomb's test negative. She received supportive treatment and was started on hemodialysis. Rheumatoid factor and anti-cyclic citrullinated peptide antibodies were positive; antinuclear antibody (ANA) and anti dsDNA antibody were negative. Serum C3 and C4 levels were

Address for correspondence:

Dr. J. Dhanapriya,
Department of Nephrology, Madras Medical College and Rajiv
Gandhi Government General Hospital, Chennai, Tamil Nadu, India.
E-mail: priyamdhana@gmail.com

Access this article online

Quick Response Code:



Website:

www.indianjnephrol.org

DOI:

10.4103/0971-4065.179207

This is an open access article distributed under the terms of the Creative Commons Attribution-NonCommercial-ShareAlike 3.0 License, which allows others to remix, tweak, and build upon the work non-commercially, as long as the author is credited and the new creations are licensed under the identical terms.

For reprints contact: reprints@medknow.com

How to cite this article: Sakthirajan R, Dhanapriya J, Dineshkumar T, Gopalakrishnan N, Murugan S, Balasubramaniyan T. Thrombotic microangiopathy: An unusual cause of renal failure in rheumatoid arthritis. Indian J Nephrol 2017;27:81-3.

normal. Anti-Sjogren's syndrome related antigen A (SSA), anti-Sjogren's syndrome related antigen B (SSB), anti-SM, anti-U1RNP anti-JO antibodies and serum antineutrophil cytoplasmic antibodies were negative. Antiphospholipid, anticardiolipin, and lupus anticoagulant antibodies were also negative.

Renal biopsy revealed patchy cortical necrosis, fibrin thrombi, and fragmented red blood cells (RBCs) [Figure 1] occluding capillary loops in 4/7 glomeruli. Interstitial hemorrhage and edema were observed. Tubular epithelial cells showed signs of acute injury. Subintimal swelling was noted in arterioles. Immunofluorescence was negative for all stains. She received totally 6 sessions of plasmapheresis (two plasma volume exchanges each time) after which her platelet count and LDH levels were normalized. She was started on 1 mg/kg/day prednisolone tapered over next 6 months. Her renal failure improved and was discharged with serum creatinine of 2.2 mg/dl. She was started on methotrexate and at 2 years after presentation, her creatinine was 1.5 mg/dl without further recurrence of TMA.

Discussion

RA is a chronic systemic disease characterized by persistent inflammatory synovitis, involving peripheral joints in a symmetric distribution. RA affects about 1% of the population.^[5] TMA was defined as pathological lesions characterized by endothelial injury and platelet-rich thrombi formation in microvasculature, leading to MAHA, thrombocytopenia, and end-organ ischemic damages.^[6] Amorosi and Ultmann defined the classic pentad of thrombocytopenia, MAHA, acute renal impairment, neurologic abnormalities, and fever.^[7] However, the dyad of otherwise unexplained thrombocytopenia and MAHA are sufficient to diagnose of TMA.^[8]

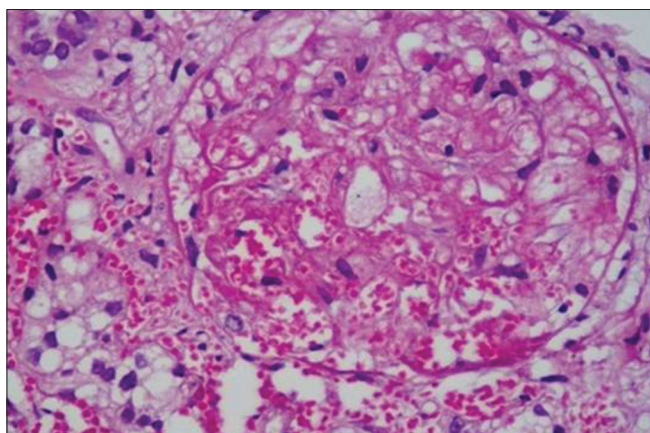


Figure 1: Renal biopsy showing fibrin thrombi and fragmented red blood cells in glomerulus (H and E)

Although TMA occurs in association with connective tissue disorders (CTDs), TMA in RA is rarely reported. To our knowledge, only two case reports and a case study^[9-11] with RA and TMA have been described so far. Nomura *et al.*^[9] published a case report of a 35-year-old female patient with RA presenting with TMA and antiphospholipid syndrome. She had thrombocytopenia, positivity for lupus anticoagulant and ANA. She was treated successfully with monthly cyclophosphamide pulse therapy. Kfoury Baz *et al.* reported another female patient presenting with TTP at 18 months after onset of RA. She was tested negative for ANA and antiphospholipid antibodies and was treated with plasma exchanges and glucocorticoids.^[10]

The pathogenetic mechanisms behind the development of TMA in RA are linked to severe deficiency of ADAMTS13 (a disintegrin and metalloprotease with thrombospondin-1-like domains) due to autoantibodies that alter its function.^[9,10] ADAMTS13 is a plasma enzyme involved in cleavage of unusually large (UL) von Willebrand factor (vWF) multimers into smaller and less adhesive vWF forms. Failure to degrade these UL-vWF multimers leads to excessive platelet aggregation and microvascular occlusion.

In a study of 127 patients with CTD and TMA including 10 patients with RA, severe deficiency of ADAMTS13 activity was seen and was closely associated with the presence of anti-ADAMTS13 IgG antibodies.^[11] Therapeutic plasma exchange resulted in high remission rate in patients with SLE than in patients with RA.

Our patient, who had RA for 5 years, presented with features suggestive of TMA. Renal biopsy showed platelet-fibrin thrombi and fragmented RBCs in glomeruli and patchy cortical necrosis. The possibility of SLE, mixed connective tissue disorder, antiphospholipid syndrome, and drug-induced TMA was ruled out. However, atypical HUS, which may have been unmasked by the inflammatory process in this patient, could not be ruled out. Testing for ADAMTS13 deficiency, antibodies against ADAMTS13, factor H and anti-factor H autoantibodies was not done due to logistic reasons. She was treated with high-dose steroids and plasmapheresis following which her renal function improved. She was started on methotrexate due to high disease activity and currently on follow-up. To conclude, the possibility of renal TMA should be considered in RA patients who present with renal failure as timely diagnosis and treatment with plasmapheresis improve the long-term renal outcome.

Acknowledgment

We would like to thank Dr. Anila Abraham Kurien, Nephropathologist, Center for Renal and Urological

Pathology Pvt Ltd, Chennai, for her help in renal biopsy evaluation.

Financial support and sponsorship

Nil.

Conflicts of interest

There are no conflicts of interest.

References

1. Boers M. Renal disorders in rheumatoid arthritis. *Semin Arthritis Rheum* 1990;20:57-68.
2. Helin HJ, Korpela MM, Mustonen JT, Pasternack AI. Renal biopsy findings and clinicopathologic correlations in rheumatoid arthritis. *Arthritis Rheum* 1995;38:242-7.
3. Barbour T, Johnson S, Cohn S, Hughes P. Thrombotic microangiopathy and associated renal disorders. *Nephrol Dial Transplant* 2012;27:2673-85.
4. Portolés J, de Tomás E, Espinosa A, Gallego E, Nieva GS, Blanco J. Thrombotic thrombocytopenic purpura and acute renal failure in adult Still's disease. *Nephrol Dial Transplant* 1997;12:1471-3.
5. Lee DM, Weinblatt ME. Rheumatoid arthritis. *Lancet* 2001;358:903-11.
6. George JN, Kremer Hovinga JA, Terrell DR, Vesely SK, Lämmle B. The oklahoma thrombotic thrombocytopenic purpura-hemolytic uremic syndrome registry: The Swiss connection. *Eur J Haematol* 2008;80:277-86.
7. Amorosi EL, Ultmann JE. Thrombotic thrombocytopenic purpura: Report of 16 cases and review of literature. *Medicine* 1966;45:139-59.
8. George JN. Clinical practice. Thrombotic thrombocytopenic purpura. *N Engl J Med* 2006;354:1927-35.
9. Nomura M, Okada J, Tateno S, Kobayashi Y, Kondo H. Renal thrombotic microangiopathy in a patient with rheumatoid arthritis and antiphospholipid syndrome: Successful treatment with cyclophosphamide pulse therapy and anticoagulant. *Intern Med* 1994;33:484-7.
10. Kfoury Baz EM, Mahfouz RA, Masri AF. Thrombotic thrombocytopenic purpura in a patient with rheumatoid arthritis treated by plasmapheresis. *Ther Apher* 1999;3:314-6.
11. Matsuyama T, Kuwana M, Matsumoto M, Isonishi A, Inokuma S, Fujimura Y. Heterogeneous pathogenic processes of thrombotic microangiopathies in patients with connective tissue diseases. *Thromb Haemost* 2009;102:371-8.