

Proliferative glomerulonephritis associated with monoclonal immune deposits: A case report and review of literature

R. Fatima, R. Jha, S. Gowrishankar¹, G. Narayan, B. S. Rao

Department of Nephrology, Medwin Hospital, Nampally, ¹Department of Histopathology, Apollo Hospitals, Hyderabad, Andhra Pradesh, India

ABSTRACT

Proliferative glomerulonephritis with monoclonal IgG deposits (PGNMID) is a newly recognized entity caused by monoclonal deposition of IgG. PGNMID resembles immune complex glomerulonephritis (GN) on light and electron microscopy. The monotypic immunoglobulin deposits seen on immunofluorescence (IF) clinches the diagnosis. We report a case of proliferative GN associated MGRS and review the relevant literature. The patient had significant proteinuria and elevated serum creatinine. The renal biopsy showed proliferative GN with focal crescents and monoclonal immune deposits confirming a diagnosis of PGNMID. Serum work up showed no monoclonal proteins. Proliferative GN as a manifestation of a monoclonal gammopathy needs to be borne in mind especially in renal biopsies of older patients.

Key words: Monoclonal immune deposits, proliferative glomerulonephritis, immunofluorescence, outcome

Introduction

Multiple myeloma is the most frequent monoclonal gammopathy to involve the kidney and may present with glomerular immunoglobulin deposition.^[1] Other glomerular diseases associated with monoclonal gammopathies include monoclonal immunoglobulin deposition disease (light chain deposition disease, and heavy chain deposition disease), Type 1 cryoglobulinemic glomerulonephritis (GN), immunotactoid GN, light and heavy chain amyloidosis, light chain proximal tubulopathy, and rarely fibrillary GN.^[2] They are all distinguished by the monoclonal immunoglobulin (or component) deposits in immunofluorescence (IF) study.

Ultrastructurally, electron-dense deposits (EDD) can be categorized into two distinct patterns: One with organized EDD formation, as seen in immunotactoid glomerulopathy, fibrillary GN, amyloidosis, and the other particularly with nonorganized powdery EDD, often seen in light/heavy-chain deposition disease. Recently in this group of monoclonal gammopathy of renal significance (MGRS), a unique category of renal disorder characterized by proliferative GN and associated with monoclonal immune deposits of IgG (PGNMID) has been added. The pathogenesis, outcome, and management of this disorder remains controversial.^[2,3] We report a case of proliferative GN with monoclonal immune deposits with short-term follow-up of 1 year and review of the literature.

Case Report

A 55-year-old female who was hypertensive for 7 years presented with history of generalized swelling of the body since 3 months and a recent seizure. She was alert, pale, and edematous and had blood pressure of 160/90 mm of Hg. There was no bone tenderness. Her systemic examination was unremarkable. Her lab evaluation was as follows: Hemoglobin (Hb): 7.6 g/dl, total leucocyte count: 13,000/cumm, platelets: 2.7 lacs/cumm, erythrocyte sedimentation rate (ESR): 66 mm/1st h, urine analysis: Protein 3 + red blood cell (RBC) plenty/hpf, white blood cell (WBC): 20-25/hpf, granular cast present. Spot urine

Address for correspondence:

Dr. Ratan Jha,
Department of Nephrology, Medwin Hospital, Nampally,
Hyderabad - 500 001, Andhra Pradesh, India.
E-mail: rtjha@yahoo.com

Access this article online	
Quick Response Code:	Website: www.indianjnephrol.org
	DOI: 10.4103/0971-4065.133012

protein/creatinine ratio was 7.5, blood urea 214 mg/dl, serum creatinine: 11 mg/dl. Na/K/Cl: 116/3.3/97 meq/L. Ca/P/- 7 mg/4.6 mg/dl. Serum protein 5.8/albumin 2.3 g/dl, alkaline phosphatase (ALP) 127 IU/l, serum cholesterol 166 mg/dl, triglyceride 212 mg/dl. Her serum complement (C3 and C4) was normal and serum cryoglobulin negative. Serology for hepatitis B, hepatitis C and human immunodeficiency virus were negative. Chest X-ray was normal and on sonography kidneys were of normal size and echogenicity. A diagnosis of rapidly progressive GN with possible systemic vasculitis was considered and kidney biopsy performed. X-ray skull showed no evidence of lytic lesion. Serum electrophoresis and free light chain assay were normal. Urine immunoelectrophoresis showed faint monoclonal protein in gamma region on immunofixation initially which on repeat test was negative. Renal biopsy showed 21 glomeruli with 2 sclerosed. All viable glomeruli were enlarged, hypercellular with lobular accentuation. There was marked mesangial and endocapillary proliferation obliterating the capillary lumina. Ten glomeruli showed associated cellular crescents (circumferential in four and segmental cellular in six). The tubules showed few small foci of atrophy. The vessels showed mild medial hyperplasia and mild intimal fibrosis. IF study had glomeruli with significant peripheral and mesangial deposits of IgG, C3c and kappa light chains. IgM, IgA, C1q and lambda light chains were negative [Figures 1 and 2]. Bone marrow aspiration was normal.

Patient received three sessions of hemodialysis followed by oral prednisolone (1 mg/kg) for 3 months with improvement in renal function (creatinine: 2.3 mg/dl) at 1 month follow-up. At 6 months follow-up, she had a relapse of swelling with the rise of serum creatinine to 3.5 mg/dl. A repeat renal biopsy showed proliferating

GN without crescents, but persistent monoclonal immune deposits. A 3 months course of prednisolone was repeated and at 1 year, she is asymptomatic with serum creatinine: 1.7 mg/dl Bl urea: 79 mg/dl Hb: 12.3 g/dl ESR: 50/1st h, Ca 9 mg/dl, P 4.4 mg/dl and ALP 125 IU/L. Urinalysis showed RBC++, protein ++, and urine protein/creatinine ratio - 5.7. She is now off steroids and is on conservative treatment for chronic kidney disease (CKD).

Discussion

Glomerular diseases have diverse etiologies and are influenced by age, sex, and race.^[4,5] In older individuals above 40 years a rational approach is to be undertaken to identify the underlying cause of glomerular disease with renal dysfunction. It may be related to rapidly progressive GN, vasculitis, mixed cryoglobulinemia, IgA nephropathy, post infectious glomerulonephritis and fibrillary glomerulonephritis. Presentation in this age group particularly with heavy nephrotic proteinuria may be caused by membranous GN, FSGS, diabetic nephropathy, IgA nephropathy, primary amyloidosis and light chain deposition disease. The paraproteinemic glomerular disorders have a different natural history and disease progression with a risk of recurrence in post renal transplantation period. It is prudent to include SPE/free light chain assay in the work up of glomerular diseases in the elderly in addition to the routine work-up. The appropriate use of term “MGRS,” which separates it from MM and monoclonal gammopathy of undetermined significance (MGUS) helps in guiding management plan.

The diagnosis of PGNMID is based on the following criteria as reported in the literature.^[2] Renal biopsy findings of GN with (a) glomerular immune deposits staining positive

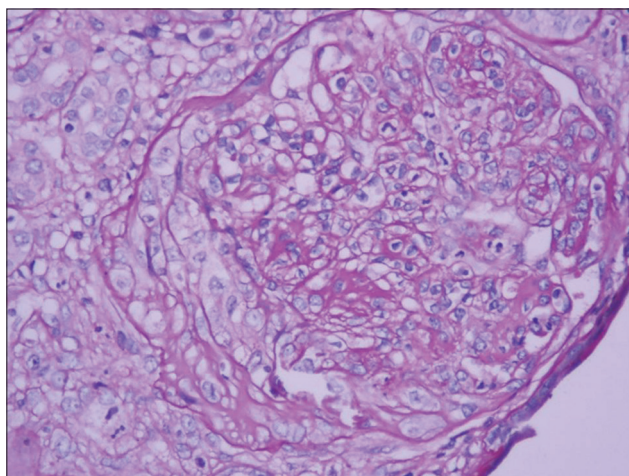


Figure 1: Enlarged glomerulus with marked proliferation occluding capillary lumina, a neutrophilic exudate and a segmental cellular crescent (Periodic acid-Schiff, ×400)

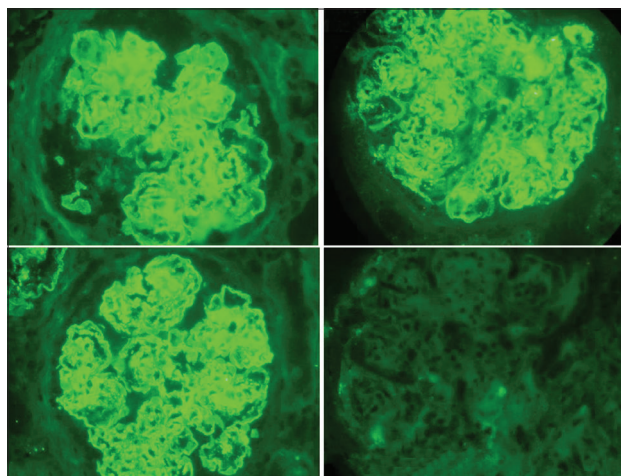


Figure 2: Composite picture of direct immunofluorescence with strong peripheral and mesangial deposits of IgG, C3c and kappa light chains. Lambda light chain is negative (×400)

for heavy chain IgG, with negativity for IgA and IgM heavy-chains, indicating restriction to a single Ig class (b) positive staining for a single IgG subclass (IgG1, IgG2, IgG3, or IgG4); (c) positive staining for a single light chain isotype indicating monoclonality (d) predominantly granular EDD in mesangial, subendothelial and/or subepithelial locations by electron microscopy, resembling immune complex GN; and (e) no clinical or laboratory evidence of cryoglobuline. Our case shows features of a classic PGNMID with deposits of a single immunoglobulin class that is, IgG and a single light chain, that is, kappa type and absent other immunoglobulins thus fulfilling three of the abovementioned five criteria, which have been put forward for a definitive diagnosis.

Proliferative glomerulonephritis with monoclonal IgG deposits usually presents with light microscopic features of membranoproliferative glomerulonephritis or endocapillary proliferative GN, in which granular, nonorganized deposits are typically seen in the subendothelial and mesangial regions.^[2,3] A pattern of membranous nephropathy with subepithelial deposits without significant endocapillary proliferative changes has also been reported.^[6] The immune deposits in glomeruli are composed of monoclonal single light or heavy chain immunoglobulin, mostly of IgG3 kappa type, while IgG1 is the second most common subclass. The occurrence of IgG2 is relatively rare in such immune deposits.^[7]

The etiology of PGNMID is not fully understood. The majority of PGNMID patients have no background diseases though a small number of PGNMID cases may be associated with underlying diseases, such as hematologic neoplasms or viral infection.^[7-10]

As it has been observed that most of the patients have no detectable M protein even after long follow-up PGNMID seems not a precursor of myeloma in most patients. Hence, such GN may arise in the course of normal immune responses. It is possible that during an immune response to putative antigens (extrinsic or intrinsic), one or more clones of B-cells proliferate and produce monoclonal IgG molecules (particularly IgG3) with ability to self-aggregate and rapidly deposit in glomeruli through entrapment and/or interaction with negatively charged glomerular constituents. The small quantity of this monoclonal IgG may escape detection by serum protein electrophoresis/urine protein electrophoresis/immunofixation electrophoresis because of its high avidity for the glomeruli and rapid aggregability favored by its intrinsic physical properties and glomerular sieving itself.^[2]

The clinical presentation of PGNMID is nonspecific and may present as nephrotic syndrome, nephritic-nephrotic syndrome, rapidly progressive renal failure or chronic GN. PGNMID appears mostly as a renal limited disorder with glomerular symptoms, frequent CKD and rarely any extra renal manifestations. The prognosis is variable with some reports showing complete remission.^[2] In the early series by Nasr *et al.*,^[2] of PGNMID of 37 patients, most of patients were older than 50 year (65%). At presentation, 49% had nephrotic syndrome, 68% had renal insufficiency, and 77% had hematuria. During an average of 30.3 months of follow-up for 32 patients, 38% had complete or partial recovery, 38% had persistent renal dysfunction, and 22% progressed to ESRD. Our patient was above 50 years, had nephrotic range proteinuria and renal insufficiency.

The term MGRS has been proposed by the International Kidney and Monoclonal Gammopathy Research Group to describe patients that meet the criteria for MGUS and demonstrate renal insufficiency with monoclonal immunoglobulin deposits in the kidney by IF.^[1,11] This distinction between MGUS and MGRS is important because the monoclonal protein appears to be the direct cause of kidney disease in such cases and treatment targeted at responsible clone is associated with restoration and preservation of kidney function.

The cornerstone of managing MGUS/smoldering multiple myeloma (SMM) involves a prudent “watch and wait” strategy.^[12] Outside the real world of clinical trials, there are no current standardized treatment options for MGUS or SMM. MGRS which could be considered to be MGUS/SMM plus syndrome with demonstrable kidney involvement runs the risk of not being treated as it rarely transform to myeloma. MGRS related kidney diseases are the results of toxic monoclonal protein produced by small B-cell clones. These disorders do not require treatment from the point of view of a “tumor” (that is, their bulk and proliferative rate), but treatment is needed to prevent renal deterioration.^[1] Therapies with novel agents have lessened the risk of treatment. Recovery of renal function is possible with adequate hematologic response. The treatment strategy should be guided by clinical presentation than by immunological diagnosis. Though, immunosuppression would be the rational approach for treatment the protocols still needs to evolve.^[2,3] The therapeutic approach should be based on the stage of CKD.^[13] In patients with stages 1 and 2 CKD, proteinuria of <1 g/day and no evidence of progressive disease, symptomatic measures will be appropriate with careful surveillance. In patients with stages 1 and 2 CKD and high-grade proteinuria (1 g/day) or progressive disease, and in patients with stages 3 and 4 CKD, chemotherapy is worthwhile. Cyclophosphamide and

bortezomib are the drugs of choice. In some patients aged 65 years, high dose melphalan with autologous stem cell transplantation (HDM/ASCT) may be performed. Beneficial effect of rituximab has been documented in patients even without a detectable B-cell clone. Even in patients with stage 5 CKD (ESRD), treatment may be appropriate if kidney transplantation is being considered with HDM/ASCT. In contrast, in patients ineligible for renal transplantation, the benefit of chemotherapy is highly questionable and conservative treatment should be considered. PGNMID may recur in the transplant despite the absence of a detectable serum M spike.^[14] The recurrent GN may respond to early aggressive immunosuppressive therapy, including a regimen of high-dose prednisone and rituximab. For those who never had a detectable monoclonal gammopathy or plasma cell clone, there is no consensus regarding their treatment prior to kidney transplant.

Conclusion

A case of proliferative GN in any patient above 50 years needs an evaluation for monoclonal gammopathy related renal disease. The first clue to the diagnosis of monoclonal gammopathy usually arise from the IF study suggesting a possibility of PGNMID. The treatment is mostly dictated by histology as patients have no features of multiple myeloma. It is worth noting that our patient remained stable at 1 year follow up without resorting to aggressive chemotherapy for myeloma. Increased awareness of PGNMID is required to recognize the entity for optimal therapeutic approach and better outcome. This could be the first such case report from India.

Acknowledgments

We thank our colleagues and staff of Nephrology.

References

1. Leung N, Bridoux F, Hutchison CA, Nasr SH, Cockwell P, Femand JP, *et al.* Monoclonal gammopathy of renal significance: When MGUS is no longer undetermined or insignificant. *Blood* 2012;120:4292-5.

2. Nasr SH, Satoskar A, Markowitz GS, Valeri AM, Appel GB, Stokes MB, *et al.* Proliferative glomerulonephritis with monoclonal IgG deposits. *J Am Soc Nephrol* 2009;20:2055-64.
3. Ohashi R, Sakai Y, Otsuka T, Ohno D, Masuda Y, Murasawa T, *et al.* Proliferative glomerulonephritis with monoclonal IgG2κ deposit successfully treated with steroids: A case report and review of the literature. *CEN Case Rep* 2013;2:197-203.
4. Hebert LA, Parikh S, Prosek J, Nadasdy T, Rovin BH. Differential diagnosis of glomerular disease: A systematic and inclusive approach. *Am J Nephrol* 2013;38:253-66.
5. Davison AM, Johnston PA. Glomerulonephritis in the elderly. *Nephrol Dial Transplant* 1996;11 Suppl 9:34-7.
6. Komatsuda A, Masai R, Ohtani H, Togashi M, Maki N, Sawada K, *et al.* Monoclonal immunoglobulin deposition disease associated with membranous features. *Nephrol Dial Transplant* 2008;23:3888-94.
7. Guiard E, Karras A, Plaisier E, Duong Van Huyen JP, Fakhouri F, Rougier JP, *et al.* Patterns of noncryoglobulinemic glomerulonephritis with monoclonal Ig deposits: Correlation with IgG subclass and response to rituximab. *Clin J Am Soc Nephrol* 2011;6:1609-16.
8. Barbour SJ, Beaulieu MC, Zalunardo NY, Magill AB. Proliferative glomerulonephritis with monoclonal IgG deposits secondary to chronic lymphocytic leukemia. Report of two cases. *Nephrol Dial Transplant* 2011;26:2712-4.
9. Fujita E, Shimizu A, Kaneko T, Masuda Y, Ishihara C, Mii A, *et al.* Proliferative glomerulonephritis with monoclonal immunoglobulin G3κ deposits in association with parvovirus B19 infection. *Hum Pathol* 2012;43:2326-33.
10. Yamada T, Arakawa Y, Mii A, Kashiwagi T, Kaneko T, Utsumi K, *et al.* A case of monoclonal immunoglobulin G1-lambda deposition associated with membranous feature in a patient with hepatitis C viral infection. *Clin Exp Nephrol* 2012;16:468-72.
11. Rajkumar SV, Kyle RA, Buadi FK. Advances in the diagnosis, classification, risk stratification, and management of monoclonal gammopathy of undetermined significance: Implications for recategorizing disease entities in the presence of evolving scientific evidence. *Mayo Clin Proc* 2010;85:945-8.
12. Landgren O. Monoclonal gammopathy of undetermined significance and smoldering multiple myeloma: Biological insights and early treatment strategies. *Hematology Am Soc Hematol Educ Program* 2013;2013:478-87.
13. Femand JP, Bridoux F, Kyle RA, Kastitis E, Weiss BM, Cook MA, *et al.* How I treat monoclonal gammopathy of renal significance (MGRS). *Blood* 2013;122:3583-90.
14. Nasr SH, Sethi S, Cornell LD, Fidler ME, Boelkins M, Fervenza FC, *et al.* Proliferative glomerulonephritis with monoclonal IgG deposits recurs in the allograft. *Clin J Am Soc Nephrol* 2011;6:122-32.

How to cite this article: Fatima R, Jha R, Gowrishankar S, Narayan G, Rao BS. Proliferative glomerulonephritis associated with monoclonal immune deposits: A case report and review of literature. *Indian J Nephrol* 2014;24:376-9.

Source of Support: Nil, **Conflict of Interest:** None declared.