



An Observational Study on the Clinicopathologic Features of Renal Monoclonal Immunoglobulin Deposition Disease

Dear Editor,

Monoclonal immunoglobulin deposition disease (MIDD) is characterized by the deposition of monoclonal immunoglobulins in the glomerular and tubular basement membranes. Monoclonal immunoglobulins are paraproteins secreted by the clonal proliferation of an abnormal plasma or B cell lineage. Identification of the nature of the monoclonal immunoglobulin deposits using fluorescence microscopy helps classify MIDD into three types.¹ Light chain deposition disease (LCDD) features a single light chain isotype (κ or λ). Heavy chain deposition disease (HCDD) shows a single heavy chain (γ , α , or μ). Light and heavy chain deposition disease (LHCDD) includes monoclonal light and heavy chains. MIDD can present with light chain cast nephropathy (LCCN).² Our study presents an analysis of the clinicopathologic characteristics of monoclonal immunoglobulin deposition disease.

We reviewed the native kidney biopsies diagnosed with MIDD and MIDD+LCCN from August 2018 to May 2024. The glomeruli in the biopsies showed one of the following morphologies - nodular glomerulosclerosis, mild increase in mesangial matrix or normocellular. The clinicopathologic

parameters were analyzed between MIDD and MIDD+LCCN groups as well as on the basis of glomerular morphology.

Out of 23,182 native kidney biopsies, 133 cases of MIDD (n=60, 0.25%) and MIDD+LCCN (n=70, 0.31%) were identified. Ninety-four patients were males, and 87 presented with acute kidney injury (AKI). All patients had proteinuria, while 45.1% were in the nephrotic range. 52.6% of patients were hypertensive. The mean serum creatinine at presentation was 5.2 ± 3.5 mg/dL. Seventy-one (53.3%) required dialysis at presentation. Serum electrophoresis showed a monoclonal M band in 22.5%. The pathologic spectrum included 41 patients with LCDD, 7 with HCDD, 12 with LHCDD, 69 with LCDD+LCCN, and 4 with LHCDD+LCCN [Figure 1].

Glomerular morphology showed that 54.1% were normocellular, 12.7% had a mild mesangial matrix increase, and 33% had nodular glomerulosclerosis. Interstitial fibrosis and tubular atrophy (IFTA) < 25% were observed in 83.4% of the cases. The tubules showed PAS-negative casts in the lumen, surrounded by inflammation and multinucleated giant cell reaction [Supplementary Figures 1 and 2] in those with MIDD + LCCN. Congo red staining was negative in all the cases.

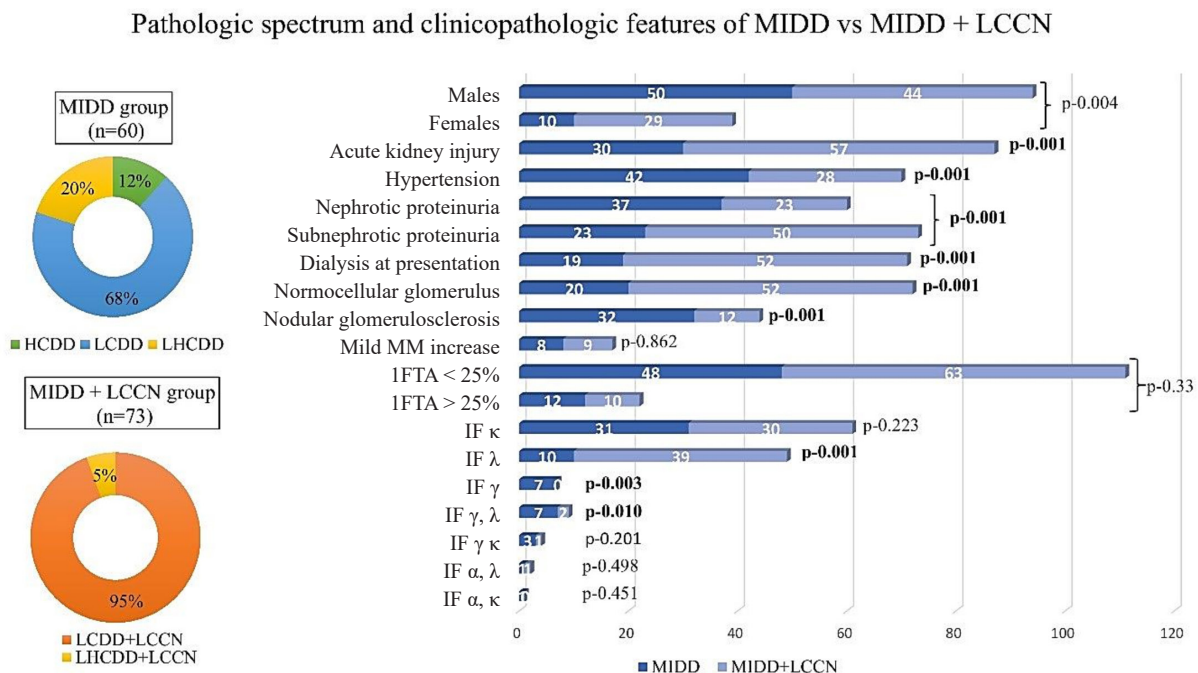


Figure 1: Spectrum of pathologic diagnoses and clinicopathologic features in MIDD and MIDD+LCCN groups. MIDD: Monoclonal immunoglobulin deposition diseases, LCCN: Light chain cast nephropathy, HCDD: Heavy chain deposition disease, LCDD: Light chain deposition disease, LHCDD: Light and heavy chain deposition disease, MM: Mesangial matrix, IFTA: Interstitial fibrosis and tubular atrophy, IF: Immunofluorescence, Significant p values are highlighted as bold values.

Analysis of clinicopathologic features based on the glomerular morphology [Table 1] showed no difference in age or serum creatinine at presentation between the three groups. Patients with nodular mesangium presented with nephrotic proteinuria. Sub-nephrotic proteinuria and lower IFTA were observed significantly in cases with normocellular glomeruli [Table 1]. Immunofluorescence showed that isolated gamma positivity (HCDD cases) was associated with nodular mesangial expansion.

There was no difference between MIDD and MIDD+LCCN groups with respect to age, gender, or IFTA [Figure 1]. Patients with MIDD+LCCN presented more frequently with AKI, subnephrotic proteinuria, higher serum creatinine ($p<0.001$), and increased dialysis requirement than the MIDD group. Their biopsies showed predominant λ deposits and normocellular glomeruli.

Prior to the biopsy, 47 patients were diagnosed with multiple myelomas, and one was diagnosed with Hodgkin's lymphoma. Most of the patients received a bortezomib-based-chemotherapy regimen. Twenty-three patients succumbed during the treatment. On follow-up ($n=33$), 15 attained hematologic remission. Eighteen were on

chemotherapy, of which four received autologous stem cell transplantation. Kidney parameters returned to normal in 23 patients. Eighteen patients were on maintenance hemodialysis. None underwent kidney transplantation.

Kidney biopsy was the first clue to diagnosing multiple myelomas in 14.6%-47.54% of the cases in Indian studies and 63.9% in our study.^{3,4} Immunofluorescence study using the panel of heavy and light chains (IgG, IgM, IgA, κ and λ light chains) in the biopsy tissue is essential to identify and classify MIDD.^{1,5}

LCDD is a common subtype of MIDD. Substantial deposits of κ light and γ heavy chains are observed in LCDD and HCDD, respectively.⁶ Patients with LHCDD (7/12) in our study had predominantly γ and λ deposits. λ light chain restriction was common in the MIDD+LCCN group.

Nodular glomerulosclerosis is a characteristic pathologic feature of MIDD. MIDD can also present without mesangial sclerosis in the biopsy.⁷ Nephrotic proteinuria was noted in cases with nodular mesangium. λ deposition, sub nephrotic proteinuria, and lower IFTA ($<25\%$) were associated with normocellular glomeruli. Nasr *et al.* documented the

Table 1: Analysis of clinicopathologic features in the study population ($n=133$) vs glomerular morphologic patterns

Clinicopathologic features	Glomerular morphology			p value [#]
	Normocellular	Nodular	Mild mm* increase	
	n (%)	n (%)	n (%)	
Age (years)	56.6 \pm 11.9	52.4 \pm 13	60.1 \pm 10.1	0.052
Gender				
Males	51 (70.8%)	36 (81.8%)	7 (41.2%)	0.041
Females	21 (29.2%)	8 (18.2%)	10 (58.8%)	
Acute kidney injury				
Yes	50 (69.4%)	24 (54.5%)	13 (76.5%)	0.155
No	22 (30.6%)	20 (45.5%)	4 (23.5%)	
Hypertension				
Yes	27 (37.5%)	37 (84.1%)	6 (35.3%)	0.001
No	45 (62.5%)	7 (15.9%)	11 (64.7%)	
Proteinuria				
Nephrotic	24 (33.3%)	30 (68.2%)	6 (35.3%)	0.001
Sub nephrotic	48 (66.7%)	14 (31.8%)	11 (64.7%)	
Serum creatinine (mg/dL)	5.5 \pm 3.5	4.9 \pm 3.5	4.7 \pm 3.6	0.588
Immunofluorescence				
κ	32 (44.4%)	22 (50%)	7 (41.2%)	0.774
λ	33 (45.8%)	9 (20.5%)	7 (41.2%)	0.032
γ, λ	4 (5.6%)	3 (6.8%)	2 (11.8%)	0.323
γ, κ	2 (2.8%)	1 (2.3%)	1 (5.9%)	0.749
γ	0 (0%)	7 (15.9%)	0 (0%)	0.001
α, λ	0 (0%)	2 (4.5%)	0 (0%)	0.128
α, κ	1 (1.4%)	0 (0%)	0 (0%)	0.652
Interstitial fibrosis, tubular atrophy				
> 25%	8 (11.1%)	8 (18.2%)	6 (35.3%)	0.01
\leq 25%	64 (88.9%)	36 (81.8%)	11 (64.7%)	
Dialysis at presentation				
Yes	40 (55.6%)	23 (52.3%)	8 (47.1%)	0.806
No	32 (44.4%)	21 (47.7%)	9 (52.9%)	

*mm, mesangial matrix. [#]statistically significant p values are highlighted as bold

characteristics of 64 patients with renal MIDD.⁷ Light microscopy confirmed nodular sclerosis in 61% of their patients. Our study showed nodular glomerulopathy in 53.3% patients in the MIDD group.

The monoclonal light chains in MIDD can get filtered in the glomeruli, forming light chain casts. A few studies have compared the dual lesion of LCDD and LCCN and LCDD.^{2,6} Our study witnessed concurrence of LHCDD+LCCN, while LHCDD itself was less commonly reported in the literature.⁸

Lin *et al.* described that from clinical and pathologic perspectives, LCDD with cast nephropathy was distinct from MIDD cases.⁶ Similar to our study, they evidenced that concomitant cast nephropathy had higher serum creatinine and sub-nephrotic proteinuria.

Zand *et al.* included 87 patients comprising 45 with LCDD, 29 with myeloma cast nephropathy, and 13 with LCDD + cast nephropathy.² Patients with LCDD had a higher degree of albuminuria than those with LCDD + cast nephropathy. Similar to our study, AKI and higher serum creatinine were observed in cases with LCDD + cast nephropathy than in those with just LCDD.

Our study had limited information on the laboratory parameters like free light chain assay, electrophoresis, and the follow-up of some patients.

Conflicts of interest: There are no conflicts of interest.

**CV Malathi¹ , KS Jansi Prema¹,
Anila Abraham Kurien¹**

¹Department of Pathology, Renopath Center for Renal and Urological Pathology, Chennai, Tamil Nadu, India

Corresponding author: Anila Abraham Kurien, Department of Pathology, Renopath Center for Renal and Urological Pathology, Chennai, Tamil Nadu, India. E-mail: anila_abraham08@yahoo.com

References

- Nasr SH, Fidler ME, Said SM, Koepplin JW, Altamirano-Alonso JM, Leung N. Immunofluorescence staining for immunoglobulin heavy chain/light chain on kidney biopsies is a valuable ancillary technique for the diagnosis of monoclonal gammopathy-associated kidney diseases. *Kidney Int* 2021;100:155-70.
- Zand L, Nasr SH, Gertz MA, Dispenzieri A, Lacy MQ, Buadi FK, *et al.* Clinical and prognostic differences among patients with light chain deposition disease, myeloma cast nephropathy and both. *Leuk Lymphoma* 2015;56:3357-64.
- Shankar M, Anandh U, Guditi S. Multiple facets of multiple myeloma in kidney biopsy: A multicenter retrospective study. *Indian J Nephrol* 2024;34:31-6.
- Sakhuja V, Jha V, Varma S, Joshi K, Gupta KL, Sud K, *et al.* Renal involvement in multiple myeloma: A 10-year study. *Ren Fail* 2000;22:465-77.
- Sethi S, Nast CC, D', Agati VD, Fervenza FC, Glasscock RJ, *et al.* Standardized reporting of monoclonal immunoglobulin-associated renal diseases: Recommendations from a mayo clinic/renal pathology society working group. *Kidney Int* 2020;98:310-313.
- Lin J, Markowitz GS, Valeri AM, Kambham N, Sherman WH, Appel GB, *et al.* Renal monoclonal immunoglobulin deposition disease: The disease spectrum. *J Am Soc Nephrol* 2001;12:1482-92.
- Nasr SH, Valeri AM, Cornell LD, Fidler ME, Sethi S, D', *et al.* Renal monoclonal immunoglobulin deposition disease: A report of 64 patients from a single institution. *Clin J Am Soc Nephrol* 2012;7:231-9.
- Wang Y, Chen D, Hu R, Zhang Y, Liang D, Xu F, *et al.* Clinicopathological characteristics of light and heavy chain deposition disease: A case series. *Am J Kidney Dis* 2024;84:447-456.e1.

This is an open access journal, and articles are distributed under the terms of the Creative Commons Attribution-NonCommercial-ShareAlike 4.0 License, which allows others to remix, transform, and build upon the work non-commercially, as long as appropriate credit is given and the new creations are licensed under the identical terms.

How to cite this article: Malathi CV, Jansi Prema KS, Kurien AA. An Observational Study on the Clinicopathologic Features of Renal Monoclonal Immunoglobulin Deposition Disease. *Indian J Nephrol*. 2025;35:417-9. doi: 10.25259/IJN_708_2024

Received: 18-11-2024; **Accepted:** 24-12-2024;
Online First: 20-02-2025; **Published:** 10-04-2025

DOI: 10.25259/IJN_708_2024

Supplementary available on: https://dx.doi.org/10.25259/IJN_708_2024



Nasal Methicillin Resistant *Staphylococcus Aureus* Colonisation and the Incidence of Invasive Staphylococcal Infection in Patients Undergoing Hemodialysis

Dear Editor,

Methicillin resistant *Staphylococcus aureus* (MRSA) is a nosocomial pathogen associated with significant morbidity and mortality. People with diabetes, intravenous drug abusers, and patients with recurrent hospital admissions are more likely to develop infection, usually following colonization. This makes targeted screening an attractive option for infection prevention and control.^{1,2} Data on MRSA surveillance and invasive infections in rural to semi-urban settings of low- and middle-income countries are essential for formulating infection surveillance strategies

and antibiotic policies. The current study aims to determine the MRSA colonization prevalence in a cohort of patients with end-stage renal disease (ESRD) undergoing dialysis.

This prospective observational cohort study was done in the hemodialysis (HD) unit in Kerala. The hospital predominantly caters to middle income patients. Demographic data, and previous hospitalization details, including infection with *Staphylococcus* were collected from hospital records. Comorbid illnesses were defined according to standard criteria.