

Blunt Trauma Abdomen Leading to Bilateral Renal Segmental Infarction: Resolving the Enigma

A 38-year-old man was admitted following blunt trauma to chest and abdomen. He underwent computed tomography (CT), which revealed the presence of aberrant renal arteries arising from either side of the abdominal aorta and supplying the lower poles of bilateral kidneys. Posttraumatic thrombosis of the proximal segments of bilateral aberrant renal arteries (for a length of ~4 cm on the right side and ~3 mm on the left side) was seen with resultant segmental infarctions of the lower poles of bilateral kidneys [Figure 1]. Bilateral main renal arteries were normal. Since the patient was hemodynamically stable with adequate urine output and normal renal function tests, the patient was managed conservatively.

Renal arterial injury is seen in ~0.08% of the cases after blunt trauma abdomen. The mechanism of injury can be stretching of the vessel wall by sudden acceleration–deceleration forces, or it can be due to compression of the vessel wall against the vertebral column after a direct

impact. Injury is most common in the proximal part of the artery (within 2–4 cm from its origin). Renal artery injury can be in the form of intimal tears, dissection, thrombosis, pseudoaneurysms, and complete or incomplete transection of the renal artery.^[1,2] Segmental or global infarction/necrosis of the kidney, hypertension, and renal failure are a few of the complications of traumatic main or aberrant renal artery thrombosis. Management varies from nonoperative conservative management to endovascular or open surgical repair depending on the hemodynamic stability of the patient, degree of renal infarction, unilateral or bilateral involvement, renal function, presence or absence of active bleeding, and other complications.^[3,4]

Declaration of patient consent

The authors certify that they have obtained all appropriate patient consent forms.

Financial support and sponsorship

Nil.

Conflicts of interest

There are no conflicts of interest.

Pooja A. Basavanagowda*, Nidhi Prabhakar*, Anuj Prabhakar, Jasmine Sethi¹

Department of Radiodiagnosis and Imaging, Post Graduate Institute of Medical Education and Research (PGIMER), Chandigarh, ¹Department of Nephrology, Post Graduate Institute of Medical Education and Research (PGIMER), Chandigarh, India

*Dr. Pooja Aralihalli Basavanagowda and Dr. Nidhi Prabhakar are co-first authors for their equal contributions.

Address for correspondence:

Dr. Nidhi Prabhakar,
Department of Radiodiagnosis and Imaging, Post Graduate Institute of Medical Education and Research (PGIMER), Chandigarh - 160 012, India.
E-mail: nidhirajpalprabhakar@gmail.com

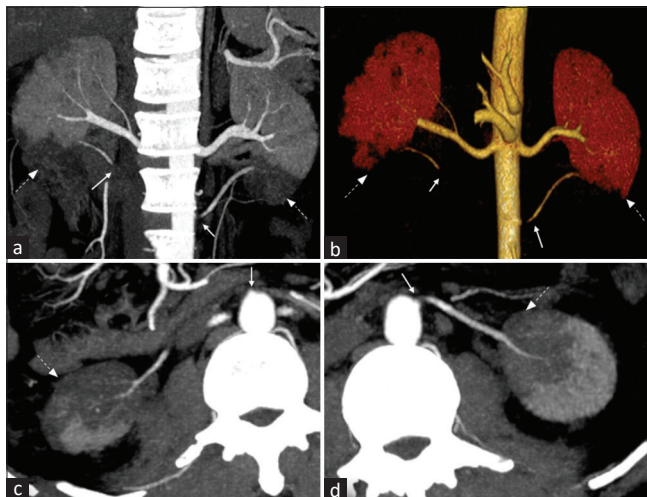


Figure 1: Images of CECT (Contrast-enhanced Computed Tomography) abdomen in the arterial phase of a 38-year-old-male patient with a history of blunt trauma abdomen showing bilateral aberrant renal artery thrombosis ((white solid arrows) just beyond the aberrant renal arteries's' origins from the aorta and segmental infarcts (white dashed arrows) in the lower poles of bilateral kidneys with normal main renal arteries. (a) MIP (Maximum Intensity Projection) coronal curved reformatted image. (b) Volume-rendered image. (c) MIP axial curved reformatted image along the axis of the right aberrant renal artery. (d) MIP axial curved reformatted image along the axis of the left aberrant renal artery

References

1. Kawashima A, Sandler CM, Corl FM, West OC, Tamm EP, Fishman EK, *et al.* Imaging of renal trauma: A comprehensive review. *Radiographics* 2001;21:557-74.
2. Lim KH, Ryeom HK, Park J. Endovascular treatment of renal

arterial perforation after blunt trauma: Case report. *Int J Surg Case Rep* 2018;42:208-11.

3. Bittenbinder EN, Reed AB. Advances in renal intervention for trauma. *Semin Vasc Surg* 2013;26:165-9.
4. Rozzanigo U, Luppi G, Gatti F, Donner D, Centonze M, Luciani L. Traumatic renal artery dissection: From imaging to management. *Clin Radiol* 2021;76:153.e17-24.

This is an open access journal, and articles are distributed under the terms of the Creative Commons Attribution-NonCommercial-ShareAlike 4.0 License, which allows others to remix, tweak, and build upon the work non-commercially, as long as appropriate credit is given and the new creations are licensed under the identical terms.

Access this article online	
Quick Response Code: 	Website: https://journals.lww.com/ijon
	DOI: 10.4103/ijon.ijn_274_23

How to cite this article: Basavanagowda PA, Prabhakar N, Prabhakar A, Sethi J. Blunt trauma abdomen leading to bilateral renal segmental infarction: Resolving the enigma. *Indian J Nephrol* 2023;33:476-7.

Received: 27-06-2023; **Accepted:** 14-07-2023; **Published:** 18-08-2023