

Bilateral nephrocalcinosis in primary hyperoxaluria type 1

C. A. Mansoor, A. Jemshad, D. S. Milliner¹, N. K. N. Bhushan²

Departments of General Medicine and ²Radio Diagnosis, MES Medical College, Perinthalmanna, Kerala, India, ¹Rare Kidney Stone Consortium, Mayo Clinic, Rochester, MN, USA

A 31-year-old male presented with recurrent renal stones from the age of 12 years and renal failure secondary to nephrolithiasis on hemodialysis for the past 6 years. He had been born of a consanguineous union and one out of his five siblings also had a history of renal failure secondary to nephrolithiasis. He had moderate anemia. Abdominal X-ray showed bilateral nephrocalcinosis with multiple stones [Figure 1a, upper panel]. Axial computed tomography scan image showed bilateral cortical nephrocalcinosis, and nephrolithiasis [Figure 1b upper panel]. DNA was extracted from the peripheral blood of the patient using a standard extraction method after obtaining written informed consent. All of the 11 exons and exon-intron boundaries of *AGXT* gene were amplified by polymerase chain reaction (PCR) as previously described.^[1] The PCR products were directly sequenced and compared to the *AGXT* sequence. Analysis revealed c. 33dupC mutation [Figure 1, lower panel]. Overproduction of oxalate in primary hyperoxaluria type 1 which forms insoluble calcium salts accumulates in organs including kidneys manifest as recurrent nephrolithiasis, nephrocalcinosis, or end-stage renal disease.^[2] Nephrocalcinosis is characterized by the presence of calcium deposits in the renal parenchyma and may be associated with conditions such as hyperparathyroidism, medullary sponge kidney, renal papillary necrosis, renal tuberculosis, hyperoxaluria, milk-alkali syndrome, sarcoidosis, immobilization, and other conditions associated with hypercalcemia and hypercalciuria, may cause medullary nephrocalcinosis.^[3] Among the 178 mutations

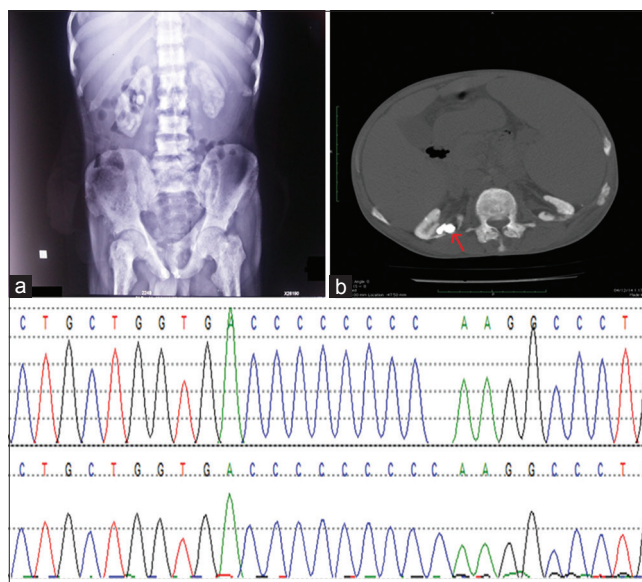


Figure 1: Upper panel - X-ray kidneys-ureters-bladder showed bilateral nephrocalcinosis with varying size stones within (a). Axial computed tomography scan image in bone window showed bilateral cortical nephrocalcinosis, oval-shaped calculi are seen within (b). Lower panel - DNA sequence chromatograms of the patient showing c. 33dupC mutation in the *AGXT* gene

described in the *AGXT* gene, Gly170Arg and c. 33dupC occur across populations at a frequency of 30% and 11%, respectively, while the Ile244Thr mutation is prevalent in North Africa and Spain.^[4]

Acknowledgement

AGXT mutation testing was provided courtesy of Ms. Andrea Cogal and Dr. Peter Harris of the Rare Kidney Stone Consortium.”Mayo Clinic.

Address for correspondence:

Dr. A. Jemshad,
Department of General Medicine, MES Medical College,
Perinthalmanna - 679 338, Kerala, India.
E-mail: jemshadalungal@gmail.com

Access this article online	
Quick Response Code:	Website: www.indianjnephrol.org
	DOI: 10.4103/0971-4065.189317

This is an open access article distributed under the terms of the Creative Commons Attribution-NonCommercial-ShareAlike 3.0 License, which allows others to remix, tweak, and build upon the work non-commercially, as long as the author is credited and the new creations are licensed under the identical terms.

For reprints contact: reprints@medknow.com

How to cite this article: Mansoor CA, Jemshad A, Milliner DS, Bhushan N. Bilateral nephrocalcinosis in primary hyperoxaluria type 1. Indian J Nephrol 2016;26:383-4.

Financial support and sponsorship

Nil.

Conflicts of interest

There are no conflicts of interest.

References

1. Monico CG, Rossetti S, Schwanz HA, Olson JB, Lundquist PA, Dawson DB, *et al.* Comprehensive mutation screening in 55 probands with type 1 primary hyperoxaluria shows feasibility of a gene-based diagnosis. *J Am Soc Nephrol* 2007;18:1905-14.
2. Cochat P, Rumsby G. Primary hyperoxaluria. *N Engl J Med* 2013;369:649-58.
3. Schepens D, Verswijvel G, Kuypers D, Vanrenterghem Y. Images in nephrology. Renal cortical nephrocalcinosis. *Nephrol Dial Transplant* 2000;15:1080-2.
4. Benhaj Mbarek I, Abroug S, Omezzine A, Zellama D, Achour A, Harbi A, *et al.* Selected *AGXT* gene mutations analysis provides a genetic diagnosis in 28% of Tunisian patients with primary hyperoxaluria. *BMC Nephrol* 2011;12:25.