

# Revised guidelines on management of antenatal hydronephrosis

A. Sinha, A. Bagga, A. Krishna<sup>1</sup>, M. Bajpai<sup>2</sup>, M. Srinivas<sup>2</sup>, R. Uppal<sup>3</sup>, I. Agarwal<sup>4</sup>

Department of Pediatrics, Division of Nephrology and <sup>2</sup>Pediatric Surgery, All India Institute of Medical Sciences, Ansari Nagar, <sup>1</sup>Max Institute of Pediatrics and Pediatric Surgery, <sup>3</sup>Uppal Radiology Center, <sup>4</sup>Pediatrics, Christian Medical College, Vellore, Tamil Nadu, India

## ABSTRACT

Widespread antenatal screening has resulted in increased detection of anomalies of the kidneys and urinary tract. The present guidelines update the recommendations published in 2000. Antenatal hydronephrosis (ANH) is transient and resolves by the third trimester in almost one-half cases. The presence of oligohydramnios and additional renal or extrarenal anomalies suggests significant pathology. All patients with ANH should undergo postnatal ultrasonography; the intensity of subsequent evaluation depends on anteroposterior diameter (APD) of the renal pelvis and/or Society for Fetal Urology (SFU) grading. Patients with postnatal APD exceeding 10 mm and/or SFU grade 3-4 should be screened for upper or lower urinary tract obstruction and vesicoureteric reflux (VUR). Infants with VUR should receive antibiotic prophylaxis through the first year of life, and their parents counseled regarding the risk of urinary tract infections. The management of patients with pelviureteric junction or vesicoureteric junction obstruction depends on clinical features and results of sequential ultrasonography and radionuclide renography. Surgery is considered in patients with increasing renal pelvic APD and/or an obstructed renogram with differential renal function < 35-40% or its subsequent decline. Further studies are necessary to clarify the role of prenatal intervention, frequency of follow-up investigations and indications for surgery in these patients.

**Key words:** Pelviureteric junction obstruction, posterior urethral valves, renography, vesicoureteric reflux

## Introduction

Ultrasound screening during pregnancy has resulted in increasing recognition of fetal hydronephrosis. Depending on diagnostic criteria and gestation, the prevalence of antenatally detected hydronephrosis (ANH) ranges from 0.6 to 5.4%.<sup>[1-6]</sup> The condition is bilateral in 17-54% and additional abnormalities are occasionally associated.<sup>[7-9]</sup> The outcome of ANH depends on the underlying etiology [Table 1].<sup>[10]</sup> Although ANH resolves by birth or during infancy in 41-88% patients<sup>[7,9-11]</sup> urological

abnormalities requiring intervention are identified in 4.1-15.4%<sup>[6,8,12]</sup> and rates of vesicoureteric reflux (VUR) and urinary tract infections (UTI) are several-fold higher.<sup>[7,13]</sup> It is important to distinguish infants with significant illness that require long-term follow-up or surgery, from those with transient hydronephrosis and minimum need for invasive investigations.

Guidelines from the Indian Society of Pediatric Nephrology (ISPN) on management of ANH were published in 2000.<sup>[14]</sup> During the last decade, there is better understanding regarding its often benign natural history and risk

### Address for correspondence:

Dr. Aditi Sinha, Division of Nephrology, Department of Pediatrics, All India Institute of Medical Sciences, Ansari Nagar, New Delhi - 110 029, India.  
E-mail: aditisinhaaiims@gmail.com

### Access this article online

#### Quick Response Code:



#### Website:

www.indianjnephrol.org

#### DOI:

10.4103/0971-4065.109403

**Table 1: Differential diagnosis of antenatally detected hydronephrosis**

Etiology	All cases (%)
Transient hydronephrosis	41-88
Pelviureteric junction obstruction	10-30
Vesicoureteric reflux	10-20
Vesicoureteric junction obstruction, megaureter	5-10
Multicystic dysplastic kidney	4-6
Duplex kidneys (±ureterocele)	2-7
Posterior urethral valves	1-2
Others: Urethral atresia, urogenital sinus, prune belly syndrome, tumors	Uncommon

With permission, Nguyen HT, *et al.* The Society for fetal urology consensus statement on the evaluation and management of antenatal hydronephrosis. *J Pediatr Urol* 2010;6:212-31<sup>[10]</sup>

factors for postnatal pathology. Recommendations from other expert groups, including the Society for Fetal Urology (SFU) have been published.<sup>[10,15]</sup> This document revises the ISPN guidelines and has been simultaneously published in the February 2013 issue of the Indian Pediatrics.

## Materials and Methods

A literature search of PubMed, EMBASE and the Cochrane Library databases from 1990-2011 was performed for research articles on children with ANH. The findings were presented to an invited group of pediatric nephrologists, surgeons and radiologists, and an expert each from fetal medicine and nuclear medicine on 6 January 2012 in New Delhi. Based on the strength and consistency of evidence, the studies were rated from A to D as follows:

- Systematic review, well designed randomized controlled trials (RCT) or diagnostic studies without significant limitations
- RCT or diagnostic studies with methodological limitations; consistent evidence from observational studies
- Small cohorts or case control studies; case series
- Expert opinion; case reports

Subsequently, each guideline was assigned one of two levels of recommendation, based on assessment of relative benefit versus harm.

*Level 1.* Recommendation applicable to most subjects, based on consistent information confirming benefit over harm or *vice versa*.

*Level 2.* Suggestion or option based on equivocal or insufficient evidence and with unclear balance of benefit over harm, which may require modification when managing a patient.

The manuscript was circulated to participants of the meeting and to additional experts of the ISPN for approval. Important terms used in this document are described in Textbox 1.<sup>[16,17]</sup> Table 2 lists salient differences between the present and previous recommendations.<sup>[14]</sup>

## Antenatal Evaluation and Monitoring

### Guideline 1: Diagnosis and grading of antenatal hydronephrosis

- We recommend that ANH be diagnosed and its severity graded based on anteroposterior diameter (APD) of the fetal renal pelvis (1B).
- ANH is present if the APD is  $\geq 4$  mm in second trimester and  $\geq 7$  mm in the third trimester.

While the renal pelvic APD [Figure 1] varies with

gestation, maternal hydration and bladder distension, it is an objective parameter with small intraobserver and interobserver variation.<sup>[18]</sup> ANH is present if fetal renal APD is  $\geq 4$  mm in the second trimester and  $\geq 7$  mm in third

### Textbox 1: Important definitions

*Isolated hydronephrosis:* Hydronephrosis without ureteric and/or bladder abnormalities

*Bilateral hydronephrosis:* Hydronephrosis involving both kidneys; or hydronephrosis in solitary kidney

*APD:* Anteroposterior diameter of the fetal or neonatal renal pelvis, assessed as shown in Figure 1

*Soft signs:* Subtle abnormalities on ultrasound [Table 3] that affect 10-20% normal fetuses; little significance in isolation; resolve with advancing gestation or after birth

*Oligohydramnios:* Amniotic fluid volume less than 500 ml, as indicated by the absence of pockets of fluid greater than 2 cm on ultrasound or amniotic fluid index below 5-6

*Suspected lower urinary tract obstruction:* Bilateral hydroureteronephrosis associated with dilated thick walled bladder that fails to empty, dilated posterior urethra, and/or oligohydramnios

### Table 2: Important revisions in the document

Guidelines rated, as recommendations or suggestions, based on quality and strength of evidence

Hydronephrosis defined and graded using renal pelvic anteroposterior diameter (APD) in antenatal period; and APD or Society of Fetal Urology grade during postnatal evaluation

Need for serial antenatal ultrasonography, including one ultrasound in the third trimester ultrasound emphasized

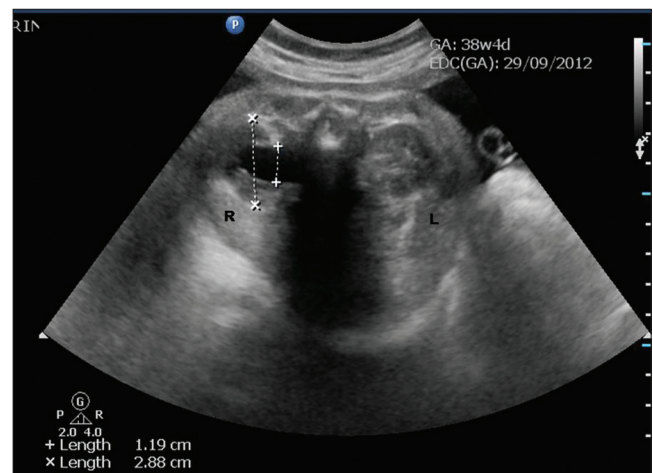
Limitations of fetal intervention discussed

Micturating cystourethrography and diuretic renography limited to infants with higher grades of hydronephrosis and/or dilated ureter (s)

Threshold for pyeloplasty revised to include patients with obstructed drainage on diuretic renography and differential function below 40% or decline in relative function

Antibiotic prophylaxis limited to infants with suspected or proven vesicoureteric reflux

Limitations in recommendations for practice highlighted



**Figure 1:** Line diagram to measure fetal renal pelvic anteroposterior diameter. The APD is measured in the transverse axial image of the renal pelvis at level of the renal hilum. Antenatal ultrasound at 38-weeks showing right-sided hydronephrosis in transverse view (+---+): 11.9 mm. Anteroposterior diameter of the kidney (x---x): 2.88 mm

trimester.<sup>[10]</sup> Hydronephrosis is further graded as mild, moderate, or severe [Table 3]. A cross-sectional study shows that the upper limit for normal renal APD during late gestation is 7 mm.<sup>[19]</sup> An APD cutoff  $\geq 7$  mm at 18-weeks or later distinguishes fetuses with postnatal reflux or obstruction from those without significant pathology.<sup>[20,21]</sup> Renal APD thresholds of 5 mm and 8-10 mm in the second and third trimester, respectively were 100% sensitive in predicting the need for postnatal surgery,<sup>[22]</sup> compared with a study where third trimester threshold of 10 mm missed 25% cases of pelviureteric junction obstruction and 50% cases of VUR.<sup>[1]</sup> Others also propose that fetal renal APD greater than 4-5 mm in the second trimester and 7 mm in third trimester is abnormal.<sup>[6,23-25]</sup> While lower cut-offs for defining hydronephrosis increase the sensitivity for detecting anomalies, it reduces specificity.

In a systematic analysis on 25 studies, Sidhu *et al.*, showed that isolated ANH resolved or stabilized in 98% patients with APD < 12 mm as compared with 51% with larger APD.<sup>[26]</sup> In another meta-analysis on 1308 neonates from 17 studies, Lee *et al.*, found that the risk of postnatal pathology increased with the degree of antenatal pelvic dilatation, from 11.9% for mild, 45.1% for moderate, and 88.3% for severe hydronephrosis.<sup>[7]</sup> The relationship was maintained for patients with pelviureteric junction obstruction or posterior urethral valves, but not for VUR and vesicoureteric junction obstruction. Other studies confirm that the severity of hydronephrosis correlates positively with postnatal hydronephrosis, need for surgery and risk of UTI, and negatively with spontaneous resolution.<sup>[5,7,23,25,27,28]</sup> While fetuses with minimal pelvic dilatation (5-9 mm) have low risk of postnatal pathology,<sup>[29,30]</sup> APD > 15 mm at any gestation represents severe hydronephrosis and requires close follow-up.<sup>[7,8,22,23,25,31-33]</sup>

### Guideline 2: Additional prenatal evaluation

- If ANH is detected, we recommend that the ultrasound at 16-20 weeks gestation also include evaluation for lower urinary tract obstruction, renal dysplasia, and extrarenal structural malformations (1C).
- We recommend that fetuses with ANH, and a major structural anomaly or additional soft sign(s) be referred to an obstetric unit with facilities for genetic counseling and prenatal testing (1C).

All fetuses with ANH should undergo detailed ultrasonography. The two signs that are useful in the diagnosis of lower urinary tract obstruction are oligohydramnios<sup>[34]</sup> and thick-walled or dilated bladder<sup>[35-41]</sup> [Table 3]. Other signs that predict postnatal pathology or need for surgery include bilateral hydroureteronephrosis, dilated posterior urethra, perinephric urinoma<sup>[42,43]</sup> and progressive calyceal,<sup>[9,23,41,44]</sup> or ureteric dilatation.<sup>[9,40,41]</sup> Features suggesting renal dysplasia and impaired renal

function include abnormally large or small kidneys, oligohydramnios,<sup>[36,45-47]</sup> parenchymal thinning,<sup>[48]</sup> cysts,<sup>[49,50]</sup> and increased echogenicity.<sup>[34,38,51,52]</sup>

Antenatal ultrasonography, in conjunction with maternal age and first or second trimester blood screen, helps determine the risk of chromosomal disorders and need for karyotyping.<sup>[53,54]</sup> The likelihood of aneuploidy in fetuses with isolated ANH is low<sup>[55-57]</sup> and karyotyping is not necessary. The risk of aneuploidy is increased in fetuses with ANH and a major structural anomaly<sup>[58,59]</sup> or with one or more additional soft signs<sup>[16,53]</sup> [Table 4]. Patients with these features require referral to a center with facilities for prenatal diagnosis and counseling. The decision regarding invasive testing is individualized, based on potential benefits and risks, and should occur at an appropriate time.

### Guideline 3: Antenatal monitoring

- In fetuses with unilateral hydronephrosis, we recommend that at least one follow-up ultrasound be performed in the third trimester (1B).
- We suggest that fetuses with bilateral hydronephrosis be monitored frequently (2C). The frequency of monitoring varies from 4 to 6 weeks, depending on gestation at which ANH was detected, its severity and presence of oligohydramnios.

**Table 3: Classification of antenatal hydronephrosis, based on renal pelvic anteroposterior diameter<sup>[10]</sup>**

Classification	Renal pelvic anteroposterior diameter, APD	
	Second trimester	Third trimester
Mild	4-6 mm	7-9 mm
Moderate	7-10 mm	10-15 mm
Severe	>10 mm	>15 mm

APD: Anteroposterior diameter

**Table 4: Additional parameters evaluated on antenatal ultrasonography**

Renal abnormalities	
Oligohydramnios	Dilated or thick-walled bladder
Calyceal dilatation	Ureteral dilatation
Perinephric urinoma	Keyhole sign
Loss of renal parenchyma, as suggested by: (i) cortical thinning, (ii) poor corticomedullary differentiation, (iii) increased renal echogenicity and/or (iv) renal cysts	
Systemic abnormalities	
Major systemic structural anomaly, e.g., cardiovascular, neurological, gastrointestinal, skeletal system	
Soft signs	
Increased nuchal translucency	Echogenic focus in the heart*
Absent nasal bone	Shortened long bones (humerus, femur)
Echogenic bowel	Choroid plexus cyst
Hydronephrosis	Ventriculomegaly

\*Limited significance of echogenic cardiac focus in Indian patients

The gestation at which hydronephrosis is detected and its course on sequential ultrasound scans has prognostic value.<sup>[21,32,60-62]</sup> Almost 80% of fetuses diagnosed in the second trimester show resolution or improvement of findings<sup>[6,21,32]</sup> with low likelihood of postnatal sequelae.<sup>[4,32]</sup> Patients with persistence or worsening hydronephrosis in the third trimester show higher rates of postnatal pathology and require close follow-up.<sup>[4-6,21,23,32,62]</sup> Sairam *et al.*, found that 88% cases with mild ANH resolved *in utero* or neonatal period, while one in three neonates with moderate to severe hydronephrosis persisting in the third trimester required postnatal surgery.<sup>[6]</sup> Hence, an ultrasound in the third trimester is valuable for identifying fetuses that require postnatal evaluation and follow-up.

The risk of *in utero* worsening is higher for bilateral than for unilateral disease.<sup>[60]</sup> While a recent report suggests that patients with mild to moderate isolated bilateral hydronephrosis have a favorable outcome,<sup>[63]</sup> close follow-up is necessary since a proportion may show progression or require surgery.<sup>[40]</sup> Although there are limited studies that address frequency of monitoring,<sup>[7]</sup> we suggest that fetal imaging be repeated every 4-6 weeks depending on severity of hydronephrosis, gestation and presence of oligohydramnios. Fetuses with findings suggestive of lower urinary tract obstruction (bilateral hydroureteronephrosis, dilated bladder and oligohydramnios) might require even more frequent monitoring.

#### Guideline 4: Fetal intervention

- a. We suggest that diagnostic and therapeutic interventions be considered for fetuses with suspected lower urinary tract obstruction and oligohydramnios only at specialized centers, following one-to-one counseling (2A).
- b. Termination of pregnancy is not recommended in fetuses with unilateral or bilateral ANH, except in presence of extrarenal life threatening abnormality (1D).

If antenatal ultrasonography shows evidence of lower urinary tract obstruction (e.g., bilateral hydroureteronephrosis, dilated bladder, oligohydramnios), parents should be referred to specialized centers for counseling regarding prenatal diagnostic and therapeutic interventions. The predominant cause for lower urinary tract obstruction is posterior urethral valves in male fetuses. Fetal vesicocentesis, done on two or more occasions, allows estimation of urinary electrolytes,  $\beta_2$  microglobulin, and osmolality that predict renal maturity and function.<sup>[64-66]</sup> Decreasing levels of sodium

(<100 mEq/l), calcium (<8 mg/dl), osmolality (<200 mOsm/l),  $\beta_2$  microglobulin (<4 mg/l), and protein (<20 mg/dl) identify fetuses that are likely to benefit from therapeutic interventions.<sup>[67]</sup> In fetuses with suspected lower urinary obstruction and favorable indices, parents should be counseled regarding the role of vesicoamniotic shunting or *in utero* endoscopic ablation of valves.<sup>[10,68,69]</sup>

The benefits of such intervention, usually performed during mid-second trimester, are equivocal. Meta-analyses show that prenatal bladder drainage, by vesicoamniotic shunt, improves perinatal survival in fetuses with severe obstruction, with benefits chiefly in those with poor predicted prognosis.<sup>[70,71]</sup> There is no evidence that this intervention improves long term renal outcome or reduces mortality in fetuses with less severe disease.<sup>[68,72,73]</sup> Moreover, vesicocentesis and other interventions carry considerable risk of fetal loss, chorioamnionitis, and preterm labor. While current evidence is insufficient, ongoing trials shall provide clarity on the efficacy and safety of these procedures.<sup>[74]</sup>

Pregnancy in fetuses with unilateral or bilateral ANH should proceed to term, except if complicated by severe oligohydramnios or major structural anomalies. Early delivery is not indicated, and carries risks of prematurity and low birth weight.

## Postnatal Evaluation and Management

### Guideline 5: Timing of initial ultrasound

- a. We recommend that all newborns with history of ANH should have postnatal ultrasound examination within the first week of life (1B).
- b. In neonates with suspected posterior urethral valves, oligohydramnios or severe bilateral hydronephrosis, ultrasonography should be performed within 24-48 h of birth (1C).
- c. In all other cases, the ultrasound should be performed preferably within 3-7 days, or before hospital discharge (1C).

All newborns with a history of ANH, including those in whom it had resolved prenatally, should undergo postnatal evaluation.<sup>[10,25]</sup> Reports suggest that hydronephrosis that has resolved postnatally does not merit prolonged follow-up and has satisfactory outcome.<sup>[75,76]</sup> In a cohort of 130 infants with ANH and normal postnatal ultrasound, followed for 2 years without prophylaxis, the outcome was satisfactory without progression of hydronephrosis or occurrence of UTI.<sup>[76]</sup> Patients with persistent postnatal hydronephrosis require additional evaluation, the intensity of which is determined by the severity of findings.<sup>[1,5,7,10]</sup> A systematic



review of 31 studies concluded that the risk of postnatal pathology was 10.8% in infants with a normal postnatal ultrasound, compared to 54.7% in those with persisting hydronephrosis.<sup>[11]</sup> In another study, the negative predictive value of a normal postnatal ultrasound for UTI was 98.9%.<sup>[77]</sup> Nepple *et al.*, showed that VUR was twice as likely to resolve in patients with normal postnatal ultrasound compared with those with abnormal findings.<sup>[78]</sup>

It is emphasized that an ultrasound in the first few days of life underestimates the degree of pelvic dilatation due to dehydration and a relatively low urine output.<sup>[79,80]</sup> Despite this limitation, an early ultrasound, within 24-48 h of birth, is necessary in neonates with suspected lower urinary tract obstruction, oligohydramnios and bilateral severe hydronephrosis or severe hydronephrosis in a solitary kidney.<sup>[10]</sup> In others, the first ultrasound examination should ideally be delayed until the end of first week. Since there is a risk that a proportion of patients might be lost to follow-up,<sup>[81]</sup> we propose that neonates with unilateral or mild to moderate bilateral hydronephrosis be screened by ultrasonography prior to hospital discharge.

#### Guideline 6: Diagnosis and grading of postnatal hydronephrosis

- We recommend that assessment of severity of postnatal hydronephrosis be based on the classification proposed by SFU or anteroposterior diameter of the renal pelvis (1B).
- We suggest that ultrasonography should include evaluation for calyceal or ureteric dilation, cortical cysts and enhanced renal echogenicity, and bladder wall abnormalities (2D).

Common classifications for diagnosis and grading of postnatal hydronephrosis are those based on measurement of renal pelvic APD<sup>[7,82,83]</sup> and that proposed by the SFU.<sup>[84]</sup> The latter assesses renal pelvic fullness, dilatation of major and minor calyces and cortical thickness [Figure 2]. Neonatal hydronephrosis is defined as SFU grade  $\geq 1$  or renal APD  $\geq 7$  mm. There are limited studies that have compared SFU and APD based classification systems. A systematic review concluded that 98% patients with SFU grade 1-2 or APD  $<12$  mm resolved, compared with 51% with APD  $>12$  mm or SFU 3-4.<sup>[26]</sup> A retrospective review showed correlation between APD  $<10$  mm in late third trimester and SFU grade  $<2$  on postnatal ultrasonography.<sup>[62]</sup>

Grading the severity of hydronephrosis enables identification of infants that require close follow-up. Multiple studies suggest that mild isolated unilateral or bilateral hydronephrosis with APD  $<9-11$  mm is a

frequent finding, which is unlikely to be associated with obstruction and has favorable prognosis.<sup>[7,31,63,85-89]</sup> In a systematic review, Paserotti *et al.*, showed that the risk of postnatal pathology increased progressively from 29.6% with mild postnatal hydronephrosis to 96.3% in severe hydronephrosis.<sup>[11]</sup> Results of a meta-analysis showed that isolated ANH was five times more likely to stabilize if associated with SFU grade 1-2 or APD  $<12$  mm than with SFU grade 3-4 or APD  $>12$  mm.<sup>[26]</sup> In a retrospective review, Chertin found that SFU grade 3-4 were associated with high odds for surgery.<sup>[90]</sup>

Ultrasonography should include evaluation for calyceal or ureteric dilation, cortical cysts and echogenicity, bladder wall abnormalities, ureterocele and bladder emptying.<sup>[91,92]</sup> The presence of calyceal and/or ureteric dilatation has high (87-96%) specificity but low sensitivity (37-54%) for detecting grade III-V VUR.<sup>[93]</sup> Increased parenchymal echogenicity, loss of corticomedullary differentiation and presence of cortical cysts on postnatal ultrasound predict impaired renal function or dysplasia in patients with pelviureteric obstruction and posterior urethral valves.<sup>[94-97]</sup>

#### Guideline 7: Postnatal monitoring

- We recommend that neonates with normal ultrasound examination in the first week of life should undergo a repeat study at 4-6 weeks (1C).
- We recommend that infants with isolated mild unilateral or bilateral hydronephrosis (APD  $<10$  mm or SFU grade 1-2) should be followed by sequential ultrasound alone, for resolution or progression of findings (1C).

A single ultrasound in the first week of life might not detect all abnormalities of the kidneys or urinary tract, due to low urine flow secondary to dehydration and low glomerular filtration rate (GFR). An ultrasound at 6 weeks is more sensitive and specific for obstruction, than that in the first week of life.<sup>[88]</sup> All newborns with a normal ultrasound at first week, therefore, require a repeat study at 4-6 weeks.<sup>[10]</sup> The presence of two normal postnatal renal ultrasounds excludes presence of significant renal disease including dilating VUR.<sup>[21,98]</sup>

The frequency of subsequent monitoring in patients with persistent postnatal hydronephrosis depends on its severity, and includes evaluation for increasing pelvicalyceal or ureteric dilatation and cortical thinning. A repeat ultrasound may show late worsening or recurrence of hydronephrosis in 1-5% patients.<sup>[99,100]</sup> Since progression might occur in the first 2-years of life, and occasionally until 5-6 years,<sup>[101]</sup> follow-up studies are scheduled at 3-6 months, and then 6-12 monthly until resolution.<sup>[102]</sup>

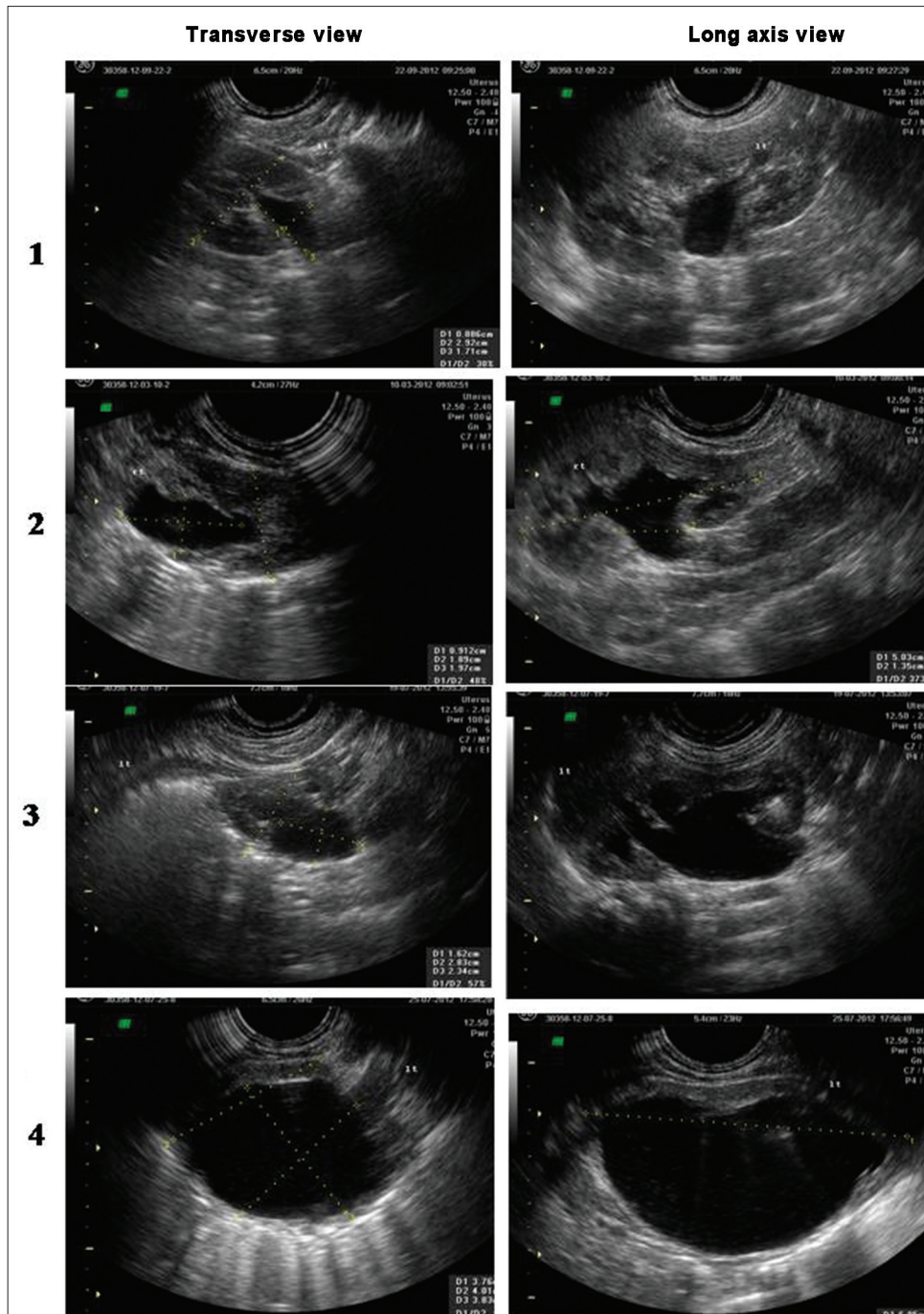


Figure 2: Postnatal ultrasounds depicting the different grades of hydronephrosis according to the Society of Fetal Urology classification. Grade 1: Slight separation of the central renal echo complex. Grade 2: Renal pelvis is further dilated and a single or a few calyces may be visualized. Grade 3: Renal pelvis is dilated and there are fluid filled calyces throughout the kidney, but renal parenchyma is of normal thickness. Grade 4: As grade 3, but renal parenchyma over the calyces is thinned

Most patients with mild hydronephrosis (SFU grade 1-2; renal APD < 10 mm) do not have significant obstruction and maintain kidney function on the long-term. The intensity of evaluation for milder grades of hydronephrosis has therefore declined.<sup>[103-105]</sup> Recent cohorts with unilateral or bilateral hydronephrosis with APD up to 10 mm<sup>[106]</sup> or 15 mm<sup>[63,107]</sup> have been followed successfully, relying on clinical features, ultrasonography and counseling parents

for surveillance for UTI. Hydronephrosis resolves in most such patients during the first 2-years of life, and radiologic investigations or antibiotic prophylaxis is usually not necessary. The policy to follow these neonates with sequential ultrasonography to monitor for resolution of hydronephrosis therefore seems satisfactory.

Various experts propose that infants with renal APD

exceeding 10 mm or SFU grade 3-4 at onset require close follow-up.<sup>[1,10,16,108,109]</sup> Evaluation of the upper and/or lower urinary tract is limited to these patients and those showing increasing dilatation of renal pelvis, calyces or ureter, or thinning of cortical parenchyma.<sup>[91,93-96]</sup>

#### Guideline 8: Micturating cystourethrogram

- We recommend that a micturating cystourethrogram (MCU) be performed in patients with unilateral or bilateral hydronephrosis with renal pelvic APD > 10 mm, SFU grade 3-4 or ureteric dilatation (1B).
- We recommend that MCU be performed early, within 24-72 h of life, in patients with suspected lower urinary tract obstruction (1D). In other cases, the procedure should be done at 4-6 weeks of age.
- We recommend MCU for infants with antenatally detected hydronephrosis who develop a urinary tract infection (1C).

Lower urinary tract obstruction (most commonly posterior urethral valves in boys; occasionally bilateral ureteroceles) is an important cause of ANH and requires prompt management. Ultrasonographic findings of posterior urethral valves are: (i) bilateral hydroureteronephrosis, (ii) dilated, thick-walled bladder that fails to empty, and (iii) dilated posterior urethra. Since these patients are at risk for progressive kidney disease and recurrent UTI, an early MCU (within 1-3 days of life) enables prompts intervention.

VUR is present in 8-38% patients with unilateral or bilateral ANH, as compared with < 1% in the general population.<sup>[7,110,111]</sup> While there is increased risk of UTI, there is lack of evidence that antibiotic prophylaxis in patients with mild VUR confers clinical benefit.<sup>[112]</sup> Multiple studies and a systematic review suggest that the severity of ANH does not correlate with the grade of reflux,<sup>[7,25,113]</sup> and that patients with VUR may have normal postnatal ultrasound.<sup>[11,23,93,114]</sup> However, renal pelvic APD exceeding 10-11 mm is useful in identifying patients with severe VUR.<sup>[98,115-116]</sup>

We recommend that MCU be restricted to infants with moderate to severe hydronephrosis (SFU grade 3-4, or renal APD >10 mm), dilated ureter(s), or bladder or urethral abnormalities. Although evidence for timing is lacking, the procedure is performed at 4-6 weeks of age, unless lower urinary tract obstruction is suspected (see above). MCU is also required in patients with history of milder grades of ANH who show worsening hydronephrosis, progressive parenchymal thinning or occurrence of UTI.<sup>[117]</sup> Physicians should be aware that this investigation is associated with risks of UTI<sup>[118]</sup> and exposure to radiation.<sup>[119]</sup>

#### Guideline 9: Diuretic renography

- We recommend that infants with moderate to severe unilateral or bilateral hydronephrosis (SFU grade 3-4, APD >10 mm) who do not show VUR should undergo diuretic renography (1C).
- We suggest that infants with hydronephrosis and dilated ureter(s) and no evidence of VUR undergo diuretic renography (2C).
- The preferred radiopharmaceuticals are <sup>99m</sup>Tc-mercaptoacetyltriglycine (<sup>99m</sup>Tc-MAG3), <sup>99m</sup>Tc-ethylenedicysteine (<sup>99m</sup>Tc-EC) or <sup>99m</sup>Tc-diethylenetriaminepentaacetic acid (DTPA) (2D). The differential function is estimated and renogram curve inspected for pattern of drainage.
- We suggest that diuretic renography be performed after 6-8 weeks of age (2D). The procedure may be repeated after 3-6 months in infants where ultrasound shows worsening of pelvicalyceal dilatation (2D).

Pelviureteric junction obstruction should be considered in infants with hydronephrosis, where dilating VUR is excluded. The likelihood of detecting obstruction is considerably higher in patients with SFU grade 4 or renal APD exceeding 20-30 mm.<sup>[7,25,26]</sup> The possibility of vesicoureteric junction obstruction or megaureter is considered in patients with hydronephrosis and dilated ureter where MCU is normal. Patients with VUR and worsening hydronephrosis also require evaluation for pelviureteric junction obstruction, since the two may coexist in 7-18% patients.<sup>[120]</sup>

Diuretic renography allows differentiation between obstructive and non-obstructive hydronephrosis and estimating relative renal function.<sup>[121]</sup> Radiopharmaceuticals such as <sup>99m</sup>technetium mercaptoacetyltriglycine (<sup>99m</sup>Tc-MAG3) or ethylenedicysteine (<sup>99m</sup>Tc-EC) are preferred, since they show greater renal extraction and higher kidney to background ratio compared to diethylenetriaminepentaacetic acid (<sup>99m</sup>Tc-DTPA).<sup>[122-124]</sup> However, DTPA is inexpensive and widely available.

Since immaturity of renal function results in reduced radiotracer uptake, renography is done at 6-8 weeks of life but may be performed earlier in patients with severe hydronephrosis and cortical thinning. Textbox 2 lists guidelines for renography.<sup>[121,125]</sup> Intravenous hydration and bladder catheterization are not necessary,<sup>[121,126,127]</sup> the latter indicated in patients with poor bladder emptying on late films (neurogenic bladder), severe bilateral reflux or megaureters. A normal renogram curve is characterized by an early peak (2-5 min), rapidly descending phase and almost complete renal emptying by 20 min. Drainage is influenced by state



## Textbox 2: Renal diuretic scan for patients with antenatal hydronephrosis

### Pre-requisites

Ensure hydration. Oral hydration suffices; administer an additional feed prior to study

### Bladder catheterization

Catheterization is not necessary, except in patients with suspected bladder abnormality or post micturition films showing persistent contrast in bladder

### Radiopharmaceutical

<sup>99m</sup>Tc-Technetium mercaptoacetyltriglycine (<sup>99m</sup>Tc-MAG3) or ethylenedicysteine (<sup>99m</sup>Tc-EC) preferred to diethylenetriaminepentaacetic acid (<sup>99m</sup>Tc-DTPA)

### Dose

<sup>99m</sup>Tc-MAG3: 1.9 MBq per kg body weight (minimum 15 MBq)

<sup>99m</sup>Tc-DTPA: 3.7 MBq per kg body weight (minimum 20 MBq)

<sup>99m</sup>Tc-EC: 50–100 MBq

Lower dose in impaired renal function

### Diuretic

Furosemide 1 mg/kg IV

Timing: Simultaneously with radiopharmaceutical (*F0*); alternatively given 20 min following (*F+20*) or 15 min prior (*F-15*)

### Position

Supine first 20 min; erect position if clearance delayed

### Acquisition

Differential renal function assessed at 1-2 min after administration of radiopharmaceutical

Renogram curve inspected at 20 min

Post micturition films taken 50-60 min after tracer injection

### Interpretation

A curve that shows an early peak (2-5 min) followed by complete emptying, either spontaneously, after furosemide, or on late post micturition film, excludes obstruction

An obstructive pattern is a curve that rises continuously over 20 min or appears as a plateau, despite furosemide and post micturition

of hydration, and composite and differential kidney function.<sup>[121,127]</sup> The presence of satisfactory drainage spontaneously, or following IV furosemide and micturition excludes significant obstruction. An obstructive pattern is defined by an ascending or plateau phase over 20 min, that fails to empty following diuretic administration and on post-micturition views.<sup>[121,127]</sup> Differential renal function is estimated; values between 45% and 55% are considered normal.<sup>[128,129]</sup> An initial differential function below 35-40% in the kidney with obstructed drainage signifies impaired function.<sup>[130]</sup> Other features that suggest obstruction include ipsilateral supranormal differential renal function ( $\geq 55\%$ )<sup>[131,132]</sup> and prolonged time to clear 50% of the radionuclide ( $t_{1/2} > 20$  min).<sup>[133]</sup>

Many patients require repeat renography, when change in differential function and drainage pattern is compared.<sup>[130]</sup> The timing of the repeat procedure is not defined, and varies with patient age, initial renal function and persistence or worsening of ultrasonographic findings. The tracer used for the first renogram and timing of diuretic administration should be similar during serial evaluations.

## Guideline 10: Indications for surgery

- We recommend that infants with lower urinary tract obstruction be immediately referred to a surgeon for appropriate intervention (1C).
- We suggest that surgery be considered in patients with obstructed hydronephrosis, and either reduced differential renal function or its worsening on repeat evaluation (2C).
- We suggest that surgery be considered in patients with bilateral hydronephrosis or hydronephrosis in solitary kidney showing worsening dilatation and deterioration of function (2D).

Infants with posterior urethral valves require early urethral catheterization, correction of electrolyte abnormalities, treatment for possible complications and referral for surgical intervention.<sup>[134]</sup> Cystoscopic ablation of the urethral valves is recommended.<sup>[135,136]</sup>

While most experts suggest that pyeloplasty be considered in patients showing obstructed drainage and differential function below 40%,<sup>[137-139]</sup> others propose surgery at differential function below 35%,<sup>[140]</sup> or an obstructed renogram with prolonged  $t_{1/2} > 20$  min.<sup>[141]</sup>

Conservative management is appropriate for infants with an obstructive pattern on diuretic renography and differential function exceeding 40%.<sup>[90]</sup> Serial ultrasonography is recommended<sup>[10,142]</sup> and repeat renography done if there is persistent or progressive hydronephrosis or parenchymal thinning.<sup>[143,144]</sup> A reduction of differential renal function by more than 5-10% correlates with declining renal function, and the need for pyeloplasty.<sup>[130,145]</sup> Other indications for surgery include presence of pain, palpable renal lump or recurrent febrile UTI.<sup>[117]</sup> The presence of large APD exceeding 20-30 mm predicts the need for surgery in 50-55% patients.<sup>[139,146-148]</sup> Surgery allows preservation of renal function in the majority; predictors of unsatisfactory outcome include baseline differential function  $< 30\%$ <sup>[149]</sup> and renal APD  $> 50$  mm with dilated calyces.<sup>[148]</sup>

Few reports describe the management of neonates with bilateral severe hydronephrosis secondary to pelviureteric junction obstruction. While in unilateral hydronephrosis, the affected kidney is compared with normal, in bilateral hydronephrosis the function of both kidneys is potentially at risk. Careful follow-up with serial ultrasonography and radionuclide studies for worsening hydronephrosis and declining differential function and estimated GFR is recommended. While case series underscore the need for early intervention,<sup>[150]</sup> patients with mild to moderate hydronephrosis have successfully been managed



conservatively.<sup>[151]</sup> Most surgeons prefer to operate first on the kidney that is more severely affected.<sup>[152,153]</sup>

### Guideline 11: Antibiotic prophylaxis

- a. We recommend that parents of all infants with antenatal or postnatal hydronephrosis be counseled regarding the risk of urinary tract infections and need for prompt management (1B).
- b. We recommend that infants with postnatally confirmed moderate or severe hydronephrosis (SFU 3-4; renal APD > 10 mm) or dilated ureter receive antibiotic prophylaxis while awaiting evaluation (1C).
- c. We recommend that all patients detected to have VUR receive antibiotic prophylaxis through the first year of life (1B).

Infants with ANH, including where hydronephrosis has resolved postnatally, have an increased risk of UTI.<sup>[7,154]</sup> Walsh *et al.*, retrospectively estimated that the relative risk of developing pyelonephritis in these infants was 11.8 (95% confidence interval 6.8-20.5).<sup>[13]</sup> The rates of UTI have varied, based on severity of hydronephrosis, duration of follow-up and antibiotic use. Infections were reported in 1.6-7.2% infants with ANH administered antibiotic prophylaxis<sup>[8,89,154]</sup> and 3.9-10% of those not receiving prophylaxis.<sup>[37,63,98,154]</sup> In patients with isolated hydronephrosis (postnatal renal pelvic APD 5-15 mm) followed without prophylaxis, the frequency of UTI was similar in patients with bilateral (9%) or unilateral (10%) disease.<sup>[63]</sup> Parents should be counseled regarding the increased risk of UTI, and the need for prompt diagnosis and treatment.

Coelho *et al.*, reported that infants with postnatal renal pelvic APD of 10 mm or more have significantly increased risk of infections (relative risk 2.6, 95% confidence interval 1.2-5.8) compared with those with mild hydronephrosis.<sup>[106]</sup> Other studies have confirmed this finding<sup>[8,51,155]</sup> and suggest that most UTI occur within the first 6 months of life.<sup>[156]</sup> While a significant proportion of infections occur in the context of underlying VUR, other risk factors include ureteric dilatation<sup>[155,156]</sup> and underlying obstruction.<sup>[155,157]</sup> In a recent meta-analysis including 3876 infants, it was demonstrated that neonates with high grade hydronephrosis receiving antibiotic prophylaxis have a significantly lower rate of UTI when compared to untreated neonates (14.6% versus 28.9%;  $P < 0.01$ ), while the rates of UTI were low for neonates with low grade hydronephrosis, regardless of status of antibiotic prophylaxis (2.2% on prophylaxis versus 2.8% without).<sup>[158]</sup> Thus, only 7 patients with high-grade hydronephrosis are required to be treated with antibiotic prophylaxis in order to prevent one UTI.

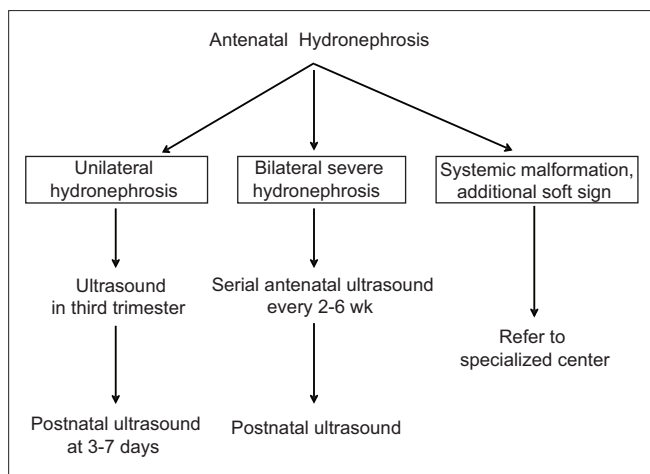
Patients with moderate or severe hydronephrosis and/or dilated ureter should receive antibiotic prophylaxis while awaiting investigations. Since the risk of UTI is low with mild hydronephrosis, antibiotic prophylaxis is not necessary in these infants.<sup>[8,63]</sup>

The efficacy of antibiotic prophylaxis in preventing UTI in patients with VUR has been questioned.<sup>[159-161]</sup> While awaiting results of further studies, the ISPN currently recommends that infants with VUR should receive antibiotic prophylaxis, the duration determined by the grade of reflux and occurrence of breakthrough infections.<sup>[162]</sup> The American Urological Association also recommends that antibiotic prophylaxis be given to infants with VUR grade III-V that is identified through screening.<sup>[104]</sup> They further suggest that, although evidence is limited, infants with lower grades of VUR (grade I-II) may also receive prophylaxis. In view of difficulties of detecting UTI in infancy and risks of renal scarring,<sup>[163]</sup> we recommend antibiotic prophylaxis for all infants with VUR detected through screening. Antibiotics that are preferred include cephalexin (10 mg/kg/d) during the first 3 months of life, and cotrimoxazole (1-2 mg/kg/d) or nitrofurantoin (1 mg/kg/d) later.

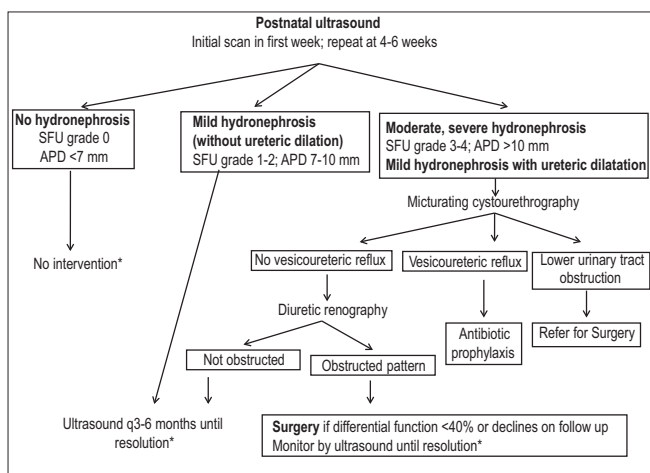
In absence of prospective controlled studies, there is variability in practice regarding use of antibiotics in children with moderate to severe obstructive hydronephrosis.<sup>[164]</sup> The rates of UTI were 0-4.3% in studies on patients with severe hydronephrosis due to pelviureteric junction obstruction or megaureter, managed without prophylaxis.<sup>[165,166]</sup> Madden *et al.*, showed that the rates of UTI were similar at 14% and 16% in infants followed with or without prophylaxis, respectively.<sup>[138]</sup> Other studies show that 19-36.2% of patients with moderate or severe obstructive hydronephrosis have UTI.<sup>[157,158]</sup> Further studies are necessary to determine the benefit of antibiotic prophylaxis in patients with obstructive hydronephrosis.

### Risk of radiation exposure

Radiocontrast and radionuclide studies are associated with considerable risk of radiation exposure. The exposure following these studies is several-fold higher than a chest radiograph.<sup>[167-169]</sup> Recent findings from a large cohort of patients undergoing repeated CT scans show that cumulative doses of 50-60 mGy (equivalent to 50-60 mSv of X-ray radiation) were associated with 3-fold increased risk of leukemia and brain cancer.<sup>[170]</sup> Physicians should be aware of the risks associated with these investigations [Table 5].<sup>[121,169,171,172]</sup> Repeat radionuclide and radiocontrast studies should be done only if these are likely to provide clinically relevant information that cannot be obtained by ultrasonography. Intravenous



**Figure 3: Prenatal monitoring in patients with antenatally detected hydronephrosis.** All fetuses with ANH should undergo at least one ultrasound in third trimester, and its severity is graded according to renal pelvic anteroposterior diameter [Table 3]. Fetuses with bilateral hydronephrosis need monitoring through pregnancy, the frequency of which depends on severity of findings and presence of oligohydramnios. Those with oligohydramnios or other systemic abnormalities should be referred to specialized centers. While all newborns with antenatally detected hydronephrosis should undergo ultrasonography in the first week of life, those with suspected bladder obstruction should undergo postnatal ultrasonography within 48 hr of birth



**Figure 4: Postnatal evaluation in patients with antenatal hydronephrosis.** A postnatal ultrasound is recommended at 3-7 days except in suspected lower urinary tract obstruction, where it is done earlier. Postnatal hydronephrosis is classified using Society of Fetal Urology grade or renal pelvic anteroposterior diameter (APD). Infants with normal findings should undergo a repeat study at 4-6 weeks. Patients with isolated mild hydronephrosis (unilateral or bilateral) should be followed with sequential ultrasounds, at 3- and 6-months, followed by 6-12 monthly until resolution; those with worsening hydronephrosis require closer evaluation. Patients with higher grades of hydronephrosis or dilated ureter (s) are screened for underlying obstruction or VUR. Diuretic renography is useful in detecting pelviureteric junction or vesicoureteric junction obstruction and determining the need for surgery. \*Parents of infants with hydronephrosis should be counseled regarding the risk of urinary tract infections

urography should not be used as an alternative to radionuclide scans. Magnetic resonance urography provides useful information, but is not freely available, requires sedation, and is associated with risks in patients with impaired renal function.

**Table 5: Dose exposure associated with radiographic procedures**

Investigation	Mean dose equivalent, mSv (range)	Equivalent number of chest X rays
Chest X-ray (PA film)	0.02 (0.007-0.05)	1
X-ray abdomen	0.7 (0.04-1.1)	35
X-ray lumbar spine	1.5 (0.5-1.8)	75
Intravenous urography	3.0 (0.7-3.7)	150
Head CT (adult)	2 (0.9-4)	100
Abdominal CT (adult)	8 (3.5-25)	400
MCU (conventional)	0.5-3.2	25-160
MCU (pulsed fluoroscopic)	0.24 (0.1-1.21)	3-15

Radiopharmaceuticals	Effective dose (mSv/mBq)	Dose equivalent*, mSv	Equivalent number of chest X rays
<sup>99m</sup> Tc DTPA (newborn)	0.037	0.36-0.89	18-45
<sup>99m</sup> Tc DTPA (5-year-old)	0.0092	0.50-0.82	25-40
<sup>99m</sup> Tc MAG3 (newborn)	0.049	0.17-0.41	8-20
<sup>99m</sup> Tc MAG3 (5-year-old)	0.012	0.23-0.38	11-20
<sup>99m</sup> Tc DMSA (newborn)	0.082	0.40-0.98	20-50
<sup>99m</sup> Tc DMSA (5-year-old)	0.020	0.54-0.90	27-45

mSv: Millisieverts, PA: Posteroanterior, CT: Computed tomography, MCU: Micturating cystourethrogram, DTPA: Diethylenetriaminepentaacetic acid, DMSA Dimercaptosuccinic acid, MAG3 mercaptoacetyltyrosine, <sup>99m</sup>Tc technetium 99m, \*Vary according to the activity schedule (surface area or body weight) used. Radiation dose is measured as ionizing energy absorbed per unit of mass, where 1 Gray (Gy)=1 joule per kilogram. The biological effect of irradiation is expressed as an equivalent dose in sieverts (Sv) or millisieverts (mSv), such that, for X-ray radiation, 1 mSv=1 mGy

## Conclusions

Figures 3 and 4 summarize the guidelines for management of patients with ANH. While a significant proportion have transient hydronephrosis that resolves *in utero* or postnatally, neonates with persistent hydronephrosis require follow-up. All neonates with hydronephrosis should undergo urinalysis, measurement of blood pressure, and estimation of serum creatinine. Infants with moderate to severe hydronephrosis are screened for urinary tract obstruction or VUR. The initial evaluation aims to detect patients with bladder obstruction, which requires prompt intervention. Decisions regarding surgical intervention, in other patients with obstructive hydronephrosis, depend on a combination of clinical and laboratory features, and results of sequential ultrasonography and diuretic renography.

## Writing Committee

Aditi Sinha, Department of Pediatrics, All India Institute of Medical Sciences (AIIMS), New Delhi; Arvind Bagga, Department of Pediatrics, AIIMS, New Delhi; Anurag Krishna, Max Institute of Pediatrics and Pediatric Surgery, New Delhi; Minu Bajpai, Department of Pediatric Surgery, AIIMS, New Delhi; M Srinivas, Department of Pediatric Surgery, AIIMS, New Delhi; Rajesh Uppal, Uppal

Radiology Center, New Delhi; Indira Agarwal, Department of Pediatrics, Christian Medical College, Vellore

### Expert Group

Kamran Afzal, Aligarh  
 Indira Agarwal, Vellore  
 Vinay Agarwal, New Delhi  
 Uma S. Ali, Mumbai  
 Kanav Anand, New Delhi  
 Sanjeev Bagai, New Delhi  
 Arvind Bagga, New Delhi, *Convener*  
 Meenu Bajpai, New Delhi  
 Sushmita Banerjee, Kolkata  
 Tathagata Bose, Ahmedabad  
 Deepika Deka, New Delhi  
 Arpana Iyengar, Bangalore  
 Ashima Gulati, New Delhi  
 Sanjeev Gulati, New Delhi  
 Arun Kumar Gupta, New Delhi  
 Pankaj Hari, New Delhi  
 Anurag Krishna, New Delhi  
 Manish Kumar, New Delhi  
 Rakesh Kumar, New Delhi  
 Madhuri Kanitkar, New Delhi  
 Mukta Mantan, New Delhi  
 Amarjeet Mehta, Jaipur  
 BR Nammalwar, Chennai  
 Saroj K Patnaik, Bangalore  
 PK Pruthi, New Delhi  
 Kishore Phadke, Bangalore  
 B Rath, New Delhi  
 Abhijeet Saha, New Delhi  
 Ashu Bhalla Seith, New Delhi  
 Sidharth Sethi, New Delhi  
 Jyoti Sharma, Pune  
 Aditi Sinha, New Delhi  
 Rajiv Sinha, Kolkata  
 Shalini Sinha, New Delhi  
 M. Srinivas, New Delhi  
 Rajendra Nath Srivastava, New Delhi  
 Rajesh Uppal, New Delhi  
 Susan Uthup, Thiruvananthapuram  
 Anand S. Vasudev, New Delhi  
 Anil Vasudevan, Bangalore  
 M Vijayakumar, Chennai

### Acknowledgment

We thank Dr. Paul Winyard, Head of Nephro-Urology Unit, UCL Institute of Child Health, London (UK) for reviewing the manuscript.

### References

- Mallik M, Watson AR. Antenatally detected urinary tract abnormalities: More detection but less action. *Pediatr Nephrol* 2008;23:897-904.
- Dudley JA, Haworth JM, McGraw ME, Frank JD, Tizard EJ. Clinical relevance and implications of antenatal hydronephrosis. *Arch Dis Child Fetal Neonatal Ed* 1997;76:F31-4.
- Kim EK, Song TB. A study on fetal urinary tract anomaly: Antenatal ultrasonographic diagnosis and postnatal follow-up. *J Obstet Gynaecol Res* 1996;22:569-73
- Ek S, Lidfeldt KJ, Varricio L. Fetal hydronephrosis; prevalence, natural history and postnatal consequences in an unselected population. *Acta Obstet Gynecol Scand* 2007;86:1463-6.
- Livera LN, Brookfield DS, Egginton JA, Hawnaur JM. Antenatal ultrasonography to detect fetal renal abnormalities: A prospective screening programme. *BMJ* 1989;298:1421-3.
- Sairam S, Al-Habib A, Sasson S, Thilaganathan B. Natural history of fetal hydronephrosis diagnosed on mid-trimester ultrasound. *Ultrasound Obstet Gynecol* 2001;17:191-6.
- Lee RS, Cendron M, Kinnamon DD, Nguyen HT. Antenatal hydronephrosis as a predictor of postnatal outcome: A meta-analysis. *Pediatrics* 2006;118:586-93.
- de Kort EH, Bambang Oetomo S, Zegers SH. The long-term outcome of antenatal hydronephrosis up to 15 millimetres justifies a noninvasive postnatal follow-up. *Acta Paediatr* 2008;97:708-13.
- Broadley P, McHugo J, Morgan I, Whittle MJ, Kilby MD. The 4 year outcome following the demonstration of bilateral renal pelvic dilatation on pre-natal renal ultrasound. *Br J Radiol* 1999;72:265-70.
- Nguyen HT, Herndon CD, Cooper C, Gatti J, Kirsch A, Kokorowski P, *et al.* The Society for Fetal Urology consensus statement on the evaluation and management of antenatal hydronephrosis. *J Pediatr Urol* 2010;6:212-31.
- Passerotti CC, Kalish LA, Chow J, Passerotti AM, Recabal P, Cendron M, *et al.* The predictive value of the first postnatal ultrasound in children with antenatal hydronephrosis. *J Pediatr Urol* 2011;7:128-36.
- Ouzounian JG, Castro MA, Fresquez M, al-Sulyman OM, Kovacs BW. Prognostic significance of antenatally detected fetal pyelectasis. *Ultrasound Obstet Gynecol* 1996;7:424-8.
- Walsh TJ, Hsieh S, Grady R, Mueller BA. Antenatal hydronephrosis and the risk of pyelonephritis hospitalization during the first year of life. *Urology* 2007;69:970-4.
- Indian Pediatric Nephrology Group, Indian Academy of Pediatrics. Consensus statement on management of antenatally detected hydronephrosis. *Indian Pediatr* 2001;38:1244-51.
- Psooy K, Pike J. Investigation and management of antenatally detected hydronephrosis. *Can Urol Assoc J* 2009;3:69-72.
- Van den Hof MC, Wilson RD, Diagnostic Imaging Committee, Society of Obstetricians and Gynaecologists of Canada, Genetics Committee, Society of Obstetricians and Gynaecologists of Canada. Fetal soft markers in obstetric ultrasound. *J Obstet Gynaecol Can* 2005;27:592-636.
- Breathnach FM, Fleming A, Malone FD. The second trimester genetic sonogram. *Am J Med Genet C Semin Med Genet* 2007;145C: 62-72.
- Pereira AK, Reis ZS, Bouzada MC, de Oliveira EA, Osanan G, Cabral AC. Antenatal ultrasonographic anteroposterior renal pelvis diameter measurement: Is it a reliable way of defining fetal hydronephrosis? *Obstet Gynecol Int* 2011;2011:861-5.
- Chitty LS, Altman DG. Charts of fetal size: Kidney and renal pelvis measurements. *Prenat Diagn* 2003;23:891-7.
- Scott JE, Renwick M. Antenatal renal pelvic measurements: What do they mean? *BJU Int* 2001;87:376-80.
- Ismaili K, Hall M, Donner C, Thomas D, Vermeylen D, Avni FE, *et al.* Results of systematic screening for minor degrees of fetal renal pelvis dilatation in an unselected population. *Am J Obstet Gynecol* 2003;188:242-6.



22. Kim HJ, Jung HJ, Lee HY, Lee YS, Im YJ, Hong CH, *et al.* Diagnostic value of anteroposterior diameter of fetal renal pelvis during second and third trimesters in predicting postnatal surgery among Korean population: Useful information for antenatal counseling. *Urology* 2012;79:1132-7.
23. Corteville JE, Gray DL, Crane JP. Congenital hydronephrosis: Correlation of fetal ultrasonographic findings with infant outcome. *Am J Obstet Gynecol* 1991;165:384-8.
24. Scott JE, Wright B, Wilson G, Pearson IA, Matthews JN, Rose PG. Measuring the fetal kidney with ultrasonography. *Br J Urol* 1995;76:769-74.
25. Aksu N, Yavaşcan O, Kangin M, Kara OD, Aydin Y, Erdoğan H, *et al.* Postnatal management of infants with antenatally detected hydronephrosis. *Pediatr Nephrol* 2005;20:1253-9.
26. Sidhu G, Beyene J, Rosenblum ND. Outcome of isolated antenatal hydronephrosis: A systematic review and meta-analysis. *Pediatr Nephrol* 2006;21:218-24.
27. Maayan-Metzger A, Lotan D, Jacobson JM, Raviv-Zilka L, Ben-Shlush A, Kuint J, *et al.* The yield of early postnatal ultrasound scan in neonates with documented antenatal hydronephrosis. *Am J Perinatol* 2011;28:613-8.
28. Wollenberg A, Neuhaus TJ, Willi UV, Wisser J. Outcome of fetal renal pelvic dilatation diagnosed during the third trimester. *Ultrasound Obstet Gynecol* 2005;25:483-8.
29. Morin L, Cendron M, Crombleholme TM, Garmel SH, Klauber GT, D'Alton ME. Minimal hydronephrosis in the fetus: Clinical significance and implications for management. *J Urol* 1996;155:2047-9.
30. Thomas DF, Madden NP, Irving HC, Arthur RJ, Smith SE. Mild dilatation of the fetal kidney: A follow-up study. *Br J Urol* 1994;74:236-9.
31. Coplen DE, Austin PF, Yan Y, Blanco VM, Dicke JM. The magnitude of fetal renal pelvic dilatation can identify obstructive postnatal hydronephrosis, and direct postnatal evaluation and management. *J Urol* 2006;176:724-7.
32. Feldman DM, DeCambre M, Kong E, Borgida A, Jamil M, McKenna P, *et al.* Evaluation and follow-up of fetal hydronephrosis. *J Ultrasound Med* 2001;20:1065-9.
33. Longpre M, Nguan A, Macneily AE, Afshar K. Prediction of the outcome of antenatally diagnosed hydronephrosis: A multivariable analysis. *J Pediatr Urol* 2012;8:135-9.
34. Kaefer M, Peters CA, Retik AB, Benacerraf BB. Increased renal echogenicity: A sonographic sign for differentiating between obstructive and nonobstructive etiologies of in utero bladder distension. *J Urol* 1997;158:1026-9.
35. Lee J, Kimber C, Shekleton P, Cheng W. Prognostic factors of severe foetal megacystitis. *ANZ J Surg* 2011;81:552-5.
36. Eckoldt F, Helling KS, Woderich R, Wolke S. Posterior urethral valves: Prenatal diagnostic signs and outcome. *Urol Int* 2004;73:296-301.
37. Oliveira EA, Diniz JS, Cabral AC, Pereira AK, Leite HV, Colosimo EA, *et al.* Predictive factors of fetal urethral obstruction: A multivariate analysis. *Fetal Diagn Ther* 2000;15:180-6.
38. Robyr R, Benachi A, Daikha-Dahmane F, Martinovich J, Dumez Y, Ville Y. Correlation between ultrasound and anatomical findings in fetuses with lower urinary tract obstruction in the first half of pregnancy. *Ultrasound Obstet Gynecol* 2005;25:478-82.
39. Bernardes LS, Aksnes G, Saada J, Masse V, Elie C, Dumez Y, *et al.* Keyhole sign: How specific is it for the diagnosis of posterior urethral valves? *Ultrasound Obstet Gynecol* 2009;34:419-23.
40. Babu R, Sai V. Postnatal outcome of fetal hydronephrosis: Implications for prenatal counselling. *Indian J Urol* 2010;26:60-2.
41. Maizels M, Wang E, Sabbagha RE, Dinsmoor M, Seshadri R, Ginsberg N, *et al.* Late second trimester assessment of pyelectasis (SERP) to predict pediatric urological outcome is improved by checking additional features. *J Matern Fetal Neonatal Med* 2006;19:295-303.
42. Ghidini A, Strobelt N, Lynch L, Berkowitz RL. Fetal urinoma: A case report and review of its clinical significance. *J Ultrasound Med* 1994;13:989-91.
43. Miller M, Korzets Z, Blumenfeld Y, Pomeranz M, Aviram R, Rathaus V, *et al.* Fetal urinoma as a sign of a dysplastic kidney. *Pediatr Nephrol* 2003;18:65-7.
44. Oktar T, Acar O, Atar A, Salabas E, Ander H, Ziylan O, *et al.* How does the presence of antenatally detected caliectasis predict the risk of postnatal surgical intervention? *Urology* 2012;80:203-6.
45. Oliveira EA, Diniz JS, Cabral AC, Leite HV, Colosimo EA, Oliveira RB, *et al.* Prognostic factors in fetal hydronephrosis: A multivariate analysis. *Pediatr Nephrol* 1999;13:859-64.
46. Oliveira EA, Rabelo EA, Pereira AK, Diniz JS, Cabral AC, Leite HV, *et al.* Prognostic factors in prenatally-detected posterior urethral valves: A multivariate analysis. *Pediatr Surg Int* 2002;18:662-7.
47. Zaccara A, Giorlandino C, Mobili L, Brizzi C, Bilancioni E, Capolupo I, *et al.* Amniotic fluid index and fetal bladder outlet obstruction. Do we really need more? *J Urol* 2005;174:1657-60.
48. Sibai H, Salle JL, Houle AM, Lambert R. Hydronephrosis with diffuse or segmental cortical thinning: Impact on renal function. *J Urol* 2001;165:2293-5.
49. Daikha-Dahmane F, Dommergues M, Muller F, Narcy F, Lacoste M, Beziau A, *et al.* Development of human fetal kidney in obstructive uropathy: Correlations with ultrasonography and urine biochemistry. *Kidney Int* 1997;52:21-32.
50. Mahony BS, Filly RA, Callen PW, Hricak H, Golbus MS, Harrison MR. Fetal renal dysplasia: Sonographic evaluation. *Radiology* 1984;152:143-6.
51. Mashiah R, Davidovits M, Eisenstein B, Kidron D, Kovo M, Shalev J, *et al.* Fetal hyperechogenic kidney with normal amniotic fluid volume: A diagnostic dilemma. *Prenat Diagn* 2005;25:553-8.
52. Estroff JA, Mandell J, Benacerraf BR. Increased renal parenchymal echogenicity in the fetus: Importance and clinical outcome. *Radiology* 1991;181:135-9.
53. Bromley B, Lieberman E, Shipp TD, Benacerraf BR. The genetic sonogram: A method of risk assessment for Down syndrome in the second trimester. *J Ultrasound Med* 2002;21:1087-96.
54. American College of Obstetricians and Gynecologists. ACOG Practice Bulletin No. 88, December 2007. Invasive prenatal testing for aneuploidy. *Obstet Gynecol* 2007;110:1459-67.
55. Havutcu AE, Nikolopoulos G, Adinkra P, Lamont RF. The association between fetal pyelectasis on second trimester ultrasound scan and aneuploidy among 25,586 low risk unselected women. *Prenat Diagn* 2002;22:1201-6.
56. Coco C, Jeanty P. Isolated fetal pyelectasis and chromosomal abnormalities. *Am J Obstet Gynecol* 2005;193:732-8.
57. Smith-Bindman R, Hosmer W, Feldstein VA, Deeks JJ, Goldberg JD. Second-trimester ultrasound to detect fetuses with Down syndrome: A meta-analysis. *JAMA* 2001;285:1044-55.
58. Wladimiroff JW, Sachs ES, Reuss A, Stewart PA, Pijpers L, Niermeijer MF. Prenatal diagnosis of chromosome abnormalities in the presence of fetal structural defects. *Am J Med Genet* 1988;29:289-91.
59. Staebler M, Donner C, Van Regemorter N, Duprez L, De Maertelaer V, Devreker F, *et al.* Should determination of the karyotype be systematic for all malformations detected by obstetrical ultrasound? *Prenat Diagn* 2005;25:567-73.
60. Bobrowski RA, Levin RB, Lauria MR, Treadwell MC, Gonik B, Bottoms SF. *In utero* progression of isolated renal pelvis dilation. *Am J Perinatol* 1997;14:423-6.
61. Signorelli M, Cerri V, Taddei F, Groli C, Bianchi UA. Prenatal diagnosis and management of mild fetal pyelectasis: Implications for neonatal outcome and follow-up. *Eur J Obstet Gynecol Reprod Biol* 2005;118:154-9.
62. Siemens DR, Prouse KA, MacNeily AE, Sauerbrei EE. Antenatal hydronephrosis: Thresholds of renal pelvic diameter to predict

- insignificant postnatal pelviectasis. *Tech Urol* 1998;4:198-201.
63. Alconcher LF, Tombesi MM. Natural history of bilateral mild isolated antenatal hydronephrosis conservatively managed. *Pediatr Nephrol* 2012;27:1119-23.
  64. Wilkins IA, Chitkara U, Lynch L, Goldberg JD, Mehalek KE, Berkowitz RL. The nonpredictive value of fetal urinary electrolytes: Preliminary report of outcomes and correlations with pathologic diagnosis. *Am J Obstet Gynecol* 1987;157:694-8.
  65. Crombleholme TM, Harrison MR, Golbus MS, Longaker MT, Langer JC, Callen PW, *et al.* Fetal intervention in obstructive uropathy: Prognostic indicators and efficacy of intervention. *Am J Obstet Gynecol* 1990;162:1239-44.
  66. Morris RK, Ruano R, Kilby MD. Effectiveness of fetal cystoscopy as a diagnostic and therapeutic intervention for lower urinary tract obstruction: A systematic review. *Ultrasound Obstet Gynecol* 2011;37:629-37.
  67. Spitzer A. The current approach to the assessment of fetal renal function: Fact or fiction? *Pediatr Nephrol* 1996;10:230-5.
  68. Holmes N, Harrison MR, Baskin LS. Fetal surgery for posterior urethral valves: Long-term postnatal outcomes. *Pediatrics* 2001;108:E7.
  69. Ruano R, Duarte S, Bunduki V, Giron AM, Srougi M, Zugaib M. Fetal cystoscopy for severe lower urinary tract obstruction-Initial experience of a single center. *Prenat Diagn* 2010;30:30-9.
  70. Clark TJ, Martin WL, Divakaran TG, Whittle MJ, Kilby MD, Khan KS. Prenatal bladder drainage in the management of fetal lower urinary tract obstruction: A systematic review and meta-analysis. *Obstet Gynecol* 2003;102:367-82.
  71. Morris RK, Malin GL, Khan KS, Kilby MD. Systematic review of the effectiveness of antenatal intervention for the treatment of congenital lower urinary tract obstruction. *BJOG* 2010;117:382-90.
  72. McLorie G, Farhat W, Khoury A, Geary D, Ryan G. Outcome analysis of vesicoamniotic shunting in a comprehensive population. *J Urol* 2001;166:1036-40.
  73. Biard JM, Johnson MP, Carr MC, Wilson RD, Hedrick HL, Pavlock C, *et al.* Long-term outcomes in children treated by prenatal vesicoamniotic shunting for lower urinary tract obstruction. *Obstet Gynecol* 2005;106:503-8.
  74. Pluto Collaborative Study Group, Kilby M, Khan K, Morris K, Daniels J, Gray R, *et al.* PLUTO trial protocol: Percutaneous shunting for lower urinary tract obstruction randomised controlled trial. *BJOG* 2007;114:904-5.
  75. Masson P, De Luca G, Tapia N, Le Pommelet C, Es Sathi A, Touati K, *et al.* Postnatal investigation and outcome of isolated fetal renal pelvis dilatation. *Arch Pediatr* 2009;16:1103-10.
  76. Ismaili K, Avni FE, Wissing KM, Hall M, Brussels Free University Perinatal Nephrology Study Group. Long-term clinical outcome of infants with mild and moderate fetal pyelectasis: Validation of neonatal ultrasound as a screening tool to detect significant nephrouropathies. *J Pediatr* 2004;144:759-65.
  77. Moorthy I, Joshi N, Cook JV, Warren M. Antenatal hydronephrosis: Negative predictive value of normal postnatal ultrasound-A 5-year study. *Clin Radiol* 2003;58:964-70.
  78. Nepple KG, Arlen AM, Austin JC, Cooper CS. The prognostic impact of an abnormal initial renal ultrasound on early reflux resolution. *J Pediatr Urol* 2011;7:462-6.
  79. Dejtter SW Jr, Gibbons MD. The fate of infant kidneys with fetal hydronephrosis but initially normal postnatal sonography. *J Urol* 1989;142:661-2.
  80. Wiener JS, O'Hara SM. Optimal timing of initial postnatal ultrasonography in newborns with prenatal hydronephrosis. *J Urol* 2002;168:1826-9.
  81. Cordero L, Nankervis CA, Oshaughnessy RW, Koff SA, Giannone PJ. Postnatal follow-up of antenatal hydronephrosis: A health-care challenge. *J Perinatol* 2009;29:382-7.
  82. Homsy YL, Saad F, Laberge I, Williot P, Pison C. Transitional hydronephrosis of the newborn and infant. *J Urol* 1990;144:579-83.
  83. Grignon A, Filion R, Filiatrault D, Robitaille P, Homsy Y, Boutin H, *et al.* Urinary tract dilatation in utero: Classification and clinical applications. *Radiology* 1986;160:645-7.
  84. Fernbach SK, Maizels M, Conway JJ. Ultrasound grading of hydronephrosis: Introduction to the system used by the Society for Fetal Urology. *Pediatr Radiol* 1993;23:478-80.
  85. Anderson NG, Fischer J, Leighton D, Hector-Taylor J, McEwing RL. Vesicoureteral reflux in children of mild postnatal renal dilatation but without vesicoureteral reflux. *Pediatr Nephrol* 2010;25:477-83.
  86. Toiviainen-Salo S, Garel L, Grignon A, Dubois J, Rypens F, Boisvert J, *et al.* Fetal hydronephrosis: Is there hope for consensus? *Pediatr Radiol* 2004;34:519-29.
  87. Dremsek PA, Gindl K, Voitl P, Strobl R, Hafner E, Geissler W, *et al.* Renal pyelectasis in fetuses and neonates: Diagnostic value of renal pelvis diameter in pre- and postnatal sonographic screening. *AJR Am J Roentgenol* 1997;168:1017-9.
  88. Clautice-Engle T, Anderson NG, Allan RB, Abbott GD. Diagnosis of obstructive hydronephrosis in infants: Comparison sonograms performed 6 days and 6 weeks after birth. *AJR Am J Roentgenol* 1995;164:963-7.
  89. Alconcher L, Tombesi M. Mild antenatal hydronephrosis: Management controversies. *Pediatr Nephrol* 2004;19:819-20.
  90. Chertin B, Pollack A, Koulikov D, Rabinowitz R, Hain D, Hadas-Halpren I, *et al.* Conservative treatment of ureteropelvic junction obstruction in children with antenatal diagnosis of hydronephrosis: Lessons learned after 16 years of follow-up. *Eur Urol* 2006;49:734-8.
  91. Mercado-Deane MG, Beeson JE, John SD. US of renal insufficiency in neonates. *Radiographics* 2002;22:1429-38.
  92. Kaefer M, Barnewolt C, Retik AB, Peters CA. The sonographic diagnosis of infravesical obstruction in children: Evaluation of bladder wall thickness indexed to bladder filling. *J Urol* 1997;157:989-91.
  93. Tibballs JM, De Bruyn R. Primary vesicoureteric reflux - How useful is postnatal ultrasound? *Arch Dis Child* 1996;75:444-7.
  94. Sarhan OM, El-Ghoneimi AA, Helmy TE, Dawaba MS, Ghali AM, Ibrahim el-HI. Posterior urethral valves: Multivariate analysis of factors affecting the final renal outcome. *J Urol* 2011;185:2491-5.
  95. Chavhan G, Daneman A, Moineddin R, Lim R, Langlois V, Traubici J. Renal pyramid echogenicity in ureteropelvic junction obstruction: Correlation between altered echogenicity and differential renal function. *Pediatr Radiol* 2008;38:1068-73.
  96. Chi T, Feldstein VA, Nguyen HT. Increased echogenicity as a predictor of poor renal function in children with grade 3-4 hydronephrosis. *J Urol* 2006;175:1898-901.
  97. Sanders RC, Nussbaum AR, Solez K. Renal dysplasia: Sonographic findings. *Radiology* 1988;167:623-6.
  98. Lidfelt KJ, Herthelius M. Antenatal hydronephrosis: Infants with minor postnatal dilatation do not need prophylaxis. *Pediatr Nephrol* 2008;23:2021-4.
  99. Shukla AR, Cooper J, Patel RP, Carr MC, Canning DA, Zderic SA, *et al.* Prenatally detected primary megaureter: A role for extended follow-up. *J Urol* 2005;173:1353-6.
  100. Matsui F, Shimada K, Matsumoto F, Takano S. Late recurrence of symptomatic hydronephrosis in patients with prenatally detected hydronephrosis and spontaneous improvement. *J Urol* 2008;180:322-5.
  101. Gatti JM, Broecker BH, Scherz HC, Perez-Brayfield MR, Kirsch AJ. Antenatal hydronephrosis with postnatal resolution: How long are postnatal studies warranted? *Urology* 2001;57:1178.
  102. Hafez AT, McLorie G, Bagli D, Khoury A. Analysis of trends on serial ultrasound for high grade neonatal hydronephrosis. *J Urol* 2002;168:1518-21.
  103. Szymanski KM, Al-Said AN, Pippi Salle JL, Capolicchio JP. Do infants with mild prenatal hydronephrosis benefit from screening for vesicoureteral reflux? *J Urol* 2012;188:576-81.

104. Peters CA, Skoog SJ, Arant BS Jr, Copp HL, Elder JS, Hudson RG, *et al.* Summary of the AUA Guideline on Management of Primary Vesicoureteral Reflux in Children. *J Urol* 2010;184:1134-44.
105. Lee RS, Diamond DA, Chow JS. Applying the ALARA concept to the evaluation of vesicoureteric reflux. *Pediatr Radiol* 2006;36:185-91.
106. Coelho GM, Bouzada MC, Pereira AK, Figueiredo BF, Leite MR, Oliveira DS, *et al.* Outcome of isolated antenatal hydronephrosis: A prospective cohort study. *Pediatr Nephrol* 2007;22:1727-34.
107. Tombesi MM, Alconcher LF. Short-term outcome of mild isolated antenatal hydronephrosis conservatively managed. *J Pediatr Urol* 2012;8:129-33.
108. Hothi DK, Wade AS, Gilbert R, Winyard PJ. Mild fetal renal pelvis dilatation: Much ado about nothing? *Clin J Am Soc Nephrol* 2009;4:168-77.
109. Riccabona M, Avni FE, Blickman JG, Dacher JN, Darge K, Lobo ML, *et al.* Imaging recommendations in paediatric urology: Minutes of the ESPR workgroup session on urinary tract infection, fetal hydronephrosis, urinary tract ultrasonography and voiding cystourethrography, Barcelona, Spain, June 2007. *Pediatr Radiol* 2008;38:138-45.
110. Zerlin JM, Ritchey ML, Chang AC. Incidental vesicoureteral reflux in neonates with antenatally detected hydronephrosis and other renal abnormalities. *Radiology* 1993;187:157-60.
111. Hodson EM, Wheeler DM, Vimalchandra D, Smith GH, Craig JC. Interventions for primary vesicoureteric reflux. *Cochrane Database Syst Rev* 2007;18:CD001532.
112. Garin EH, Olavarria F, Garcia Nieto V, Valenciano B, Campos A, Young L. Clinical significance of primary vesicoureteral reflux and urinary antibiotic prophylaxis after acute pyelonephritis: A multicenter, randomized, controlled study. *Pediatrics* 2006;117:626-32.
113. Phan V, Traubici J, Hershenfield B, Stephens D, Rosenblum ND, Geary DF. Vesicoureteral reflux in infants with isolated antenatal hydronephrosis. *Pediatr Nephrol* 2003;18:1224-8.
114. Blane CE, DiPietro MA, Zerlin JM, Sedman AB, Bloom DA. Renal sonography is not a reliable screening examination for vesicoureteral reflux. *J Urol* 1993;150:752-5.
115. Grazioli S, Parvex P, Merlini L, Combescure C, Girardin E. Antenatal and postnatal ultrasound in the evaluation of the risk of vesicoureteral reflux. *Pediatr Nephrol* 2010;25:1687-92.
116. Abdunour HA, Williams JL, Kairalla JA, Garin EH. Does hydronephrosis predict the presence of severe vesicoureteral reflux? *Eur J Pediatr* 2012;171:1605-10.
117. Finnell SM, Carroll AE, Downs SM, Subcommittee on Urinary Tract Infection. Technical report-Diagnosis and management of an initial UTI in febrile infants and young children. *Pediatrics* 2011;128:e749-70.
118. Ismaili K, Avni FE, Hall M, Brussels Free University Perinatal Nephrology (BFUPN) Study Group. Results of systematic voiding cystourethrography in infants with antenatally diagnosed renal pelvis dilation. *J Pediatr* 2002;141:21-4.
119. Ward VL. Patient dose reduction during voiding cystourethrography. *Pediatr Radiol* 2006;36 Suppl 2:168-72.
120. Hubertus J, Plieninger S, Martinovic V, Heinrich M, Schuster T, Bürst M, *et al.* Children and adolescents with ureteropelvic junction obstruction: Is an additional voiding cystourethrogram necessary? Results of a multicenter study. *World J Urol* 2012 [Epub ahead of print].
121. Gordon I, Piepsz A, Sixt R, Auspices of Paediatric Committee of European Association of Nuclear Medicine. Guidelines for standard and diuretic renogram in children. *Eur J Nucl Med Mol Imaging* 2011;38:1175-88.
122. Itoh K. <sup>99m</sup>Tc-MAG3: Review of pharmacokinetics, clinical application to renal diseases and quantification of renal function. *Ann Nucl Med* 2001;15:179-90.
123. Atasever T, Ozkaya O, Abamor E, Söylemezoğlu O, Buyan N, Unlü M. <sup>99m</sup>Tc ethylene dicysteine scintigraphy for diagnosing cortical defects in acute pyelonephritis: A comparative study with <sup>99m</sup>Tc dimercaptosuccinic acid. *Nucl Med Commun* 2004;25:967-70.
124. Lassmann M, L. Biassoni, M. Monsieurs, C. Franzius, F. Jacobs, EANM Dosimetry and Paediatrics Committees. The new EANM paediatric dosage card. *Eur J Nucl Med Mol Imaging* 2008;35:1748.
125. Donoso G, Kuyvenhoven JD, Ham H, Piepsz A. <sup>99m</sup>Tc-MAG3 diuretic renography in children: A comparison between F0 and F+20. *Nucl Med Commun* 2003;24:1189-93.
126. Conway JJ, Maizels M. The well tempered diuretic renogram: A standard method to examine the asymptomatic neonate with hydronephrosis or hydroureteronephrosis. A report from combined meetings of The Society for Fetal Urology and members of The Pediatric Nuclear Medicine Council-The Society of Nuclear Medicine. *J Nucl Med* 1992;33:2047-51.
127. Piepsz A. Antenatal detection of pelviureteric junction stenosis: Main controversies. *Semin Nucl Med* 2011;41:11-9.
128. Prigent A, Cosgriff P, Gates GF, Granerus G, Fine EJ, Itoh K, *et al.* Consensus report on quality control of quantitative measurements of renal function obtained from the renogram: International Consensus Committee from the Scientific Committee of Radionuclides in Nephrourology. *Semin Nucl Med* 1999;29:146-59.
129. Eskild-Jensen A, Gordon I, Piepsz A, Frøkaier J. Interpretation of the renogram: Problems and pitfalls in hydronephrosis in children. *BJU Int* 2004;94:887-92.
130. Josephson S. Antenatally detected, unilateral dilatation of the renal pelvis: A critical review. 1. Postnatal non-operative treatment 20 years on- Is it safe? *Scand J Urol Nephrol* 2002;36:243-50.
131. Moon DH, Park YS, Jun NL, Lee SY, Kim KS, Kim JH, *et al.* Value of supranormal function and renogram patterns on <sup>99m</sup>Tc-mercaptoacetyltryglycine scintigraphy in relation to the extent of hydronephrosis for predicting ureteropelvic junction obstruction in the newborn. *J Nucl Med* 2003;44:725-31.
132. Oh SJ, Moon DH, Kang W, Park YS, Park T, Kim KS. Supranormal differential renal function is real but may be pathological: Assessment by 99 m technetium mercaptoacetyltryglycine renal scan of congenital unilateral hydronephrosis. *J Urol* 2001;165:2300-4.
133. Amarante J, Anderson PJ, Gordon I. Impaired drainage on diuretic renography using half-time or pelvic excretion efficiency is not a sign of obstruction in children with a prenatal diagnosis of unilateral renal pelvic dilatation. *J Urol* 2003;169:1828-31.
134. Yohannes P, Hanna M. Current trends in the management of posterior urethral valves in the pediatric population. *Urology* 2002;60:947-53.
135. Sarhan O, Zaccaria I, Macher MA, Muller F, Vuillard E, Delezoide AL, *et al.* Long-term outcome of prenatally detected posterior urethral valves: Single center study of 65 cases managed by primary valve ablation. *J Urol* 2008;179:307-12.
136. Bajpai M, Dave S, Gupta DK. Factors affecting outcome in the management of posterior urethral valves. *Pediatr Surg Int* 2001;17:11-5.
137. Salem YH, Majd M, Rushton HG, Belman AB. Outcome analysis of pediatric pyeloplasty as a function of patient age, presentation and differential renal function. *J Urol* 1995;154:1889-93.
138. Madden NP, Thomas DF, Gordon AC, Arthur RJ, Irving HC, Smith SE. Antenatally detected pelviureteric junction obstruction. Is non-operation safe? *Br J Urol* 1991;68:305-10.
139. Thomas DF. Prenatal diagnosis: What do we know of long-term outcomes? *J Pediatr Urol* 2010;6:204-11.
140. Bajpai M, Bal CS, Kalaivani M, Gupta AK. Plasma renin activity for monitoring vesicoureteric reflux therapy: Mid-term observations.



- J Pediatr Urol 2008;4:60-4.
141. Heinlen JE, Manatt CS, Bright BC, Kropp BP, Campbell JB, Frimberger D. Operative versus nonoperative management of ureteropelvic junction obstruction in children. *Urology* 2009;73:521-5.
  142. Ransley PG, Dhillon HK, Gordon I, Duffy PG, Dillon MJ, Barratt TM. The postnatal management of hydronephrosis diagnosed by prenatal ultrasound. *J Urol* 1990;144:584-7.
  143. Heinlen JE, Kropp BP, Frimberger DC. Progression of hydronephrosis correlates with worsening renal function in children. Conference: 2009 American Urological Association (AUA) Annual Meeting Chicago, IL United States. Conference Publication. *J Urol* 2009;181:443.
  144. Zampieri N, Zamboni C, Ottolenghi A, Camoglio FS. Unilateral hydronephrosis due to ureteropelvic junction obstruction in children: Long term follow-up. *Minerva Urol Nefrol* 2009;61:325-9.
  145. Chertin B, Rolle U, Farkas A, Puri P. Does delaying pyeloplasty affect renal function in children with a prenatal diagnosis of pelvi-ureteric junction obstruction? *BJU Int* 2002;90:72-5.
  146. Uluocak N, Ander H, Acar O, Amasyali AS, Erkorkmaz U, Ziylan O. Clinical and radiological characteristics of patients operated in the first year of life due to ureteropelvic junction obstruction: Significance of renal pelvis diameter. *Urology* 2009;74:898-902.
  147. Kumar S, Walia S, Ipkeme O, Zhang E, Paramasivam G, Agarwal S, *et al.* Postnatal outcome of prenatally diagnosed severe fetal renal pelvic dilatation. *Prenat Diagn* 2012;32:519-22.
  148. Dhillon HK. Prenatally diagnosed hydronephrosis: The Great Ormond Street experience. *Br J Urol* 1998;81:39-44.
  149. Koff SA, Campbell KD. The nonoperative management of unilateral neonatal hydronephrosis: Natural history of poorly functioning kidneys. *J Urol* 1994;152:593-5.
  150. Kim YS, Cho CK, Han SW. Comparison between unilateral pyeloplasty and conservative treatment in bilateral ureteropelvic junction obstruction of children. *Korean J Urol*. 1998;39:1248-53.
  151. Onen A, Jayanthi VR, Koff SA. Long-term followup of prenatally detected severe bilateral newborn hydronephrosis initially managed nonoperatively. *J Urol* 2002;168:1118-20.
  152. Kim J, Hong S, Park CH, Park H, Kim KS. Management of severe bilateral ureteropelvic junction obstruction in neonates with prenatally diagnosed bilateral hydronephrosis. *Korean J Urol* 2010;51:653-6.
  153. Bajpai M, Chandrasekharam VV. Nonoperative management of neonatal moderate to severe bilateral hydronephrosis. *J Urol* 2002;167:662-5.
  154. Estrada CR, Peters CA, Retik AB, Nguyen HT. Vesicoureteral reflux and urinary tract infection in children with a history of prenatal hydronephrosis-should voiding cystourethrography be performed in cases of postnatally persistent grade II hydronephrosis? *J Urol* 2009;181:801-6.
  155. Lee JH, Choi HS, Kim JK, Won HS, Kim KS, Moon DH, *et al.* Nonrefluxing neonatal hydronephrosis and the risk of urinary tract infection. *J Urol* 2008;179:1524-8.
  156. Song SH, Lee SB, Park YS, Kim KS. Is antibiotic prophylaxis necessary in infants with obstructive hydronephrosis? *J Urol* 2007;177:1098-101.
  157. Yavascan O, Aksu N, Anil M, Kara OD, Aydin Y, Kangin M, *et al.* Postnatal assessment of growth, nutrition, and urinary tract infections of infants with antenatally detected hydronephrosis. *Int Urol Nephrol* 2010;42:781-8.
  158. Braga LH, Mijovic H, Farrokhhyar F, Pemberton J, DeMaria J, Lorenzo AJ. Antibiotic prophylaxis for urinary tract infections in antenatal hydronephrosis. *Pediatrics* 2013;131:e251-61.
  159. Mori R, Fitzgerald A, Williams C, Tullus K, Verrier-Jones K, Lakhnypaul M. Antibiotic prophylaxis for children at risk of developing urinary tract infection: A systematic review. *Acta Paediatr* 2009;98:1781-6.
  160. Mattoo TK. Evidence for and against urinary prophylaxis in vesicoureteral reflux. *Pediatr Nephrol* 2010;25:2379-82.
  161. Skoog SJ. Prophylaxis versus no prophylaxis for reflux. *J Urol* 2012;187:1161-2.
  162. Indian Society of Pediatric Nephrology, Vijayakumar M, Kanitkar M, Nammalwar BR, Bagga A. Revised statement on management of urinary tract infections. *Indian Pediatr* 2011;48:709-17.
  163. Cascio S, Chertin B, Colhoun E, Puri P. Renal parenchymal damage in male infants with high grade vesicoureteral reflux diagnosed after the first urinary tract infection. *J Urol* 2002;168:1708-10.
  164. Ismaili K, Avni FE, Piepsz A, Wissing KM, Cochat P, Aubert D, *et al.* Current management of infants with fetal renal pelvis dilation: A survey by French-speaking pediatric nephrologists and urologists. *Pediatr Nephrol* 2004;19:966-71.
  165. Islek A, Güven AG, Koyun M, Akman S, Alimoglu E. Probability of urinary tract infection in infants with ureteropelvic junction obstruction: Is antibacterial prophylaxis really needed? *Pediatr Nephrol* 2011;26:1837-41.
  166. Roth CC, Hubanks JM, Bright BC, Heinlen JE, Donovan BO, Kropp BP, *et al.* Occurrence of urinary tract infection in children with significant upper urinary tract obstruction. *Urology* 2009;73:74-8.
  167. Brenner DJ, Hall EJ. Computed tomography: An increasing source of radiation exposure. *N Engl J Med* 2007;357:2277-84.
  168. Mettler FA Jr, Huda W, Yoshizumi TT, Mahesh M. Effective doses in radiology and diagnostic nuclear medicine: A catalog. *Radiology* 2008;248:254-63.
  169. Smith T, Gordon I. An update of radiopharmaceutical schedules in children. *Nucl Med Commun* 1998;19:1023-36.
  170. Pearce MS, Salotti JA, Little MP, McHugh K, Lee C, Kim KP, *et al.* Radiation exposure from CT scans in childhood and subsequent risk of leukaemia and brain tumours: A retrospective cohort study. *Lancet* 2012;380:499-505.
  171. Stabin MG, Gelfand MJ. Dosimetry of pediatric nuclear medicine procedures. *Q J Nucl Med* 1998;42:93-112.
  172. Fahey FH, Treves ST, Adelstein SJ. Minimizing and communicating radiation risk in pediatric nuclear medicine. *J Nucl Med Technol* 2012;40:13-24.

**How to cite this article:** Sinha A, Bagga A, Krishna A, Bajpai M, Srinivas M, Uppal R, *et al.* Revised guidelines on management of antenatal hydronephrosis. *Indian J Nephrol* 2013;23:83-97.

**Source of Support:** Nil, **Conflict of Interest:** None declared.