

1615-9.

2. Shankar M, Sparks MA. The evolution of social media in nephrology education: A mini-review. *Front Nephrol* 2023;3: 1123969.
3. Sharma S, Anandh U, Arce-Amare F, Bek SG, Santos Junior ACS, Lerma E. The three forms of International Society of Nephrology World Congress of Nephrology - Live, virtual, and hybrid: Impact of transition on attendance and social media coverage. *Kidney Int Rep* 2023;8:1125-6.
4. Meena P, Mohanasundaram S, Kurian J, Prasad GS, Bhargava V, Panda S, *et al.* Harnessing social media to enhance nephrology academia. *JNMA J Nepal Med Assoc* 2023;61:741-7.

This is an open access journal, and articles are distributed under the terms of the Creative Commons Attribution-NonCommercial-ShareAlike 4.0 License, which allows others to remix, tweak, and build upon the work non-commercially, as long as appropriate credit is given and the new creations are licensed under the identical terms.

**How to cite this article:** Sethi J. The Ups and Downs of Live Posting in Nephrology Conferences. *Indian J Nephrol.* 2024;34:407-9. doi: 10.25259/ijn\_427\_23

**Received:** 28-09-2023; **Accepted:** 04-11-2023  
**Online First:** 18-05-2024; **Published:** 20-07-2024

**DOI:** 10.25259/ijn\_427\_23



## Urinary Biomarkers for Non-Invasive Diagnosis of Acute Interstitial Nephritis

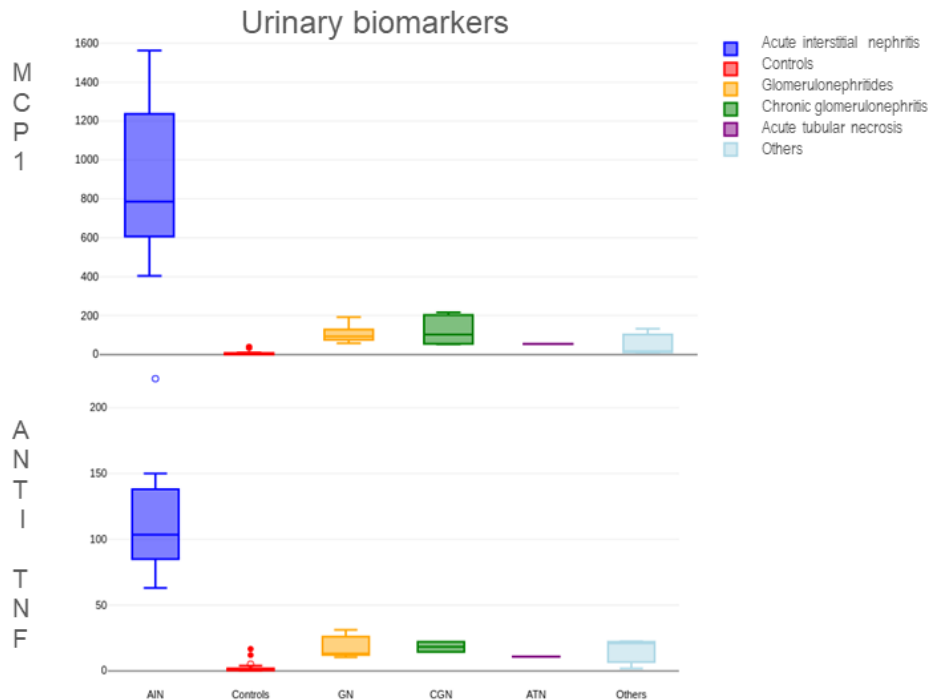
Dear Editor,

Acute interstitial nephritis has been found in 5–15% of hospitalized patients with acute kidney injury (AKI).<sup>1</sup> Kidney biopsy which is the gold standard for diagnosis<sup>2</sup> may not be attempted in all patients, and hence, it may be useful to employ urinary biomarkers. Urinary monocyte chemoattractant protein-1 (MCP-1) and tumor necrosis factor-alpha (TNF- $\alpha$ ) have been investigated in this regard.<sup>1</sup> There is paucity of information from India on urinary biomarkers.

We conducted a study to identify patients with acute interstitial nephritis (AIN) among AKI patients admitted in the Department of Medicine. Here, we are reporting the biomarker results in patients who underwent kidney biopsy.

Twenty-seven patients had undergone kidney biopsy and AIN had been diagnosed in ten patients. Thirteen patients had glomerular disease and four patients had ATN. Twenty-five controls in whom urinary tract infection had been ruled out by urine routine examination and culture were also tested. Urinary MCP-1 levels and TNF- $\alpha$  were measured by enzyme-linked immunosorbent assay (R and D systems and Abbkine, respectively). Urine MCP-1 and TNF- $\alpha$  levels were standardized to urinary creatinine measured in the same spot urine.

The average urinary MCP-1 was 893.6 ng/mmoL Cr and average urinary TNF- $\alpha$  was 116.2 ng/mmoL Cr, both well above the levels seen in other diseases and controls [Figure 1]. This validates the results from previous studies<sup>3,4</sup> that



**Figure 1:** Box and plot diagram comparing urinary tumor necrosis factor alpha and monocyte chemoattractant protein-1 levels among various etiological subgroups and controls. AIN: Acute interstitial nephritis, GN: Glomerulonephritides, CGN: Chronic glomerulonephritis, ATN: Acute tubular necrosis, MCP: monocyte chemoattractant protein, TNF: tumor necrosis factor

urinary TNF- $\alpha$  and urinary MCP-1 levels can discriminate AIN well from the other causes of AKI in our setting.

In conclusion, either urinary MCP-1 or urinary TNF- $\alpha$  can be useful for the non-invasive diagnosis of acute interstitial nephritis.

#### Ethical approval

The research/study approved by the Institutional Review Board at Jawaharlal Institute of Postgraduate education and research, number JIP/IEC/2021/280, dated November 08, 2021.

#### Conflicts of interest

There are no conflicts of interest.

#### Tamilselvan Palanisamy<sup>1</sup>, Sharbari Basu<sup>2</sup>, Bheemanathi Hanuman Srinivas<sup>3</sup>, Suryanarayana Shamanna<sup>1</sup>

Departments of <sup>1</sup>Medicine, <sup>2</sup>Biochemistry, <sup>3</sup>Pathology, Jawaharlal Institute of Postgraduate Medical Education and Research (JIPMER), Puducherry, India.

#### Corresponding author:

Suryanarayana Shamanna, Department of Medicine, Jawaharlal Institute of Postgraduate Medical Education and Research (JIPMER), Puducherry - 605006, India. E-mail: sujukumi@gmail.com

#### References

1. Sathick IJ, Zand L, Kamal AN, Norby SM, Garovic VD. Acute interstitial nephritis: Etiology, pathogenesis, diagnosis, Treatment and Prognosis. *Nephrol Res Rev* 2013;5:13-20.
2. Nussbaum EZ, Perazella MA. Diagnosing acute interstitial nephritis: Considerations for clinicians. *Clin Kidney J* 2019;12:808-13.
3. Moledina DG, Wilson FP, Pober JS, Perazella MA, Singh N, Luciano RL, *et al.* Urine TNF- $\alpha$  and IL-9 for clinical diagnosis of acute interstitial nephritis. *JCI Insight* 2019;4:e127456.
4. Wu Y, Yang L, Su T, Wang C, Liu G, Li XM. Pathological significance of a panel of urinary biomarkers in patients with drug-induced tubulointerstitial nephritis. *Clin J Am Soc Nephrol* 2010;5:1954.

This is an open access journal, and articles are distributed under the terms of the Creative Commons Attribution-NonCommercial-ShareAlike 4.0 License, which allows others to remix, tweak, and build upon the work non-commercially, as long as appropriate credit is given and the new creations are licensed under the identical terms.

**How to cite this article:** Palanisamy T, Basu S, Srinivas BH, Shamanna S. Urinary Biomarkers for Non-Invasive Diagnosis of Acute Interstitial Nephritis. *Indian J Nephrol.* 2024;34:409-10. doi: 10.25259/IJN\_38\_2024

Received: 23-01-2024; Accepted: 23-01-2024  
Online First: 06-05-2024; Published: 20-07-2024

DOI: 10.25259/IJN\_38\_2024

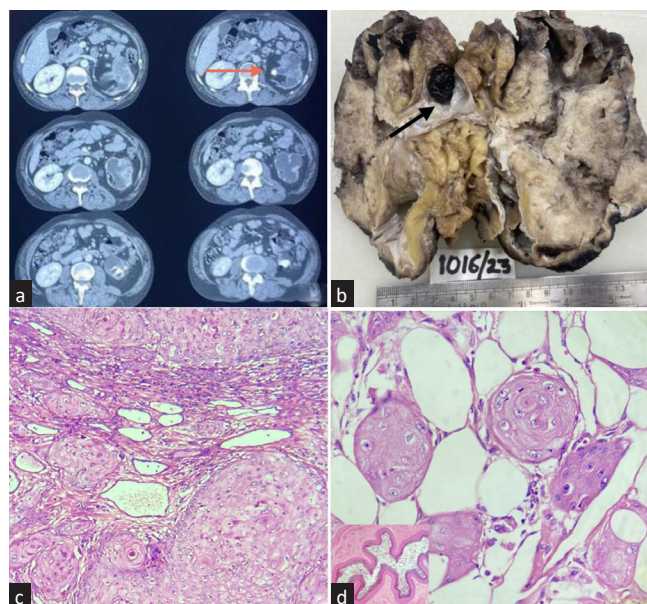


## Incidentally Detected Primary Squamous Cell Carcinoma of Kidney Arising from Renal Pelvis Impersonating Xanthogranulomatous Pyelonephritis

Dear Editor,

A 55-year-old male presented with a palpable non-tender mass in the left loin region. Urine examination showed pus cells with culture being positive for *Escherichia coli*. Ultrasound, contrast-enhanced computed tomography (CECT), and Diethylenetriaminepentaacetate (DTPA) renogram suggested a non-functioning kidney possibly due to xanthogranulomatous pyelonephritis (XGP). Simple nephrectomy was performed. [Figure 1a and b]. Microscopy showed moderately differentiated infiltrating squamous cell carcinoma arising from pelvis (PT4Nx) extending into renal capsule, peripelvic fat, and Gerota's fascia. Ureteric lining showed complete squamous metaplasia [Figure 1c and d]. At present, six months postoperatively patient is undergoing cisplatin-based chemotherapy and is asymptomatic.

Squamous cell carcinoma (SCC) of the renal pelvis is associated with chronic irritation to the epithelial lining of urothelium secondary to stones, infection, and inflammation leading to squamous metaplasia, dysplasia, and eventually SCC.<sup>1,2</sup> Akin to clinical features, radiological findings in SCC are non-specific.<sup>3</sup> As it is impractical to perform CT for every patient with renal stone, intravenous urography (IVU) should be carried out periodically, especially in patients with long-standing stones. Filling defects, delay in appearance of pyelogram or renal



**Figure 1:** (a) Serial slice of computed tomography showing left kidney (orange arrow) showing a hydronephrotic kidney with cortical thinning and stone at pelvi-ureteric junction. (b) Cut section of nephrectomy specimen showing loss of corticomedullary differentiation with dilated calyces and an impacted stone (black arrow) at pelviuretric junction. (c) Microphotograph showing moderately differentiated squamous cell carcinoma invading atrophic tubules (H&E x40). (d) Squamous cell carcinoma infiltrating the perinephric fat. (H&E 40x) Inset-Ureter with lumen displaying complete squamous metaplasia of the lining epithelium. (H&E x10).