

Concurrent Gitelman Syndrome-like Tubulopathy and Grave's Disease

Abstract

Gitelman syndrome (GS) is a rare autosomal recessive disorder characterized by the loss of function mutation of the solute carrier family-12 member-3 (*SLC12A3*) gene, encoding for sodium-chloride cotransporter of the distal convolute tubule. GS is characterized by hypokalemia, hypomagnesemia, metabolic alkalosis, and hypocalciuria. GS-like syndrome has been described rarely. Hyperthyroidism due to Grave's disease (GD) is characterized by the presence of autoantibodies to thyrotropin receptors. Concurrent occurrence of GS and GD is rarely reported, that too exclusively from far-east Asian populations. We describe a case of a 45-year-old man who presented with severe muscle weakness; the evaluation showed volume depletion, hypokalemia, hypomagnesemia, renal potassium and magnesium wasting, metabolic alkalosis, and hypocalciuria. He was also detected to have GD at the time of presentation. Genetic evaluation revealed a mutation in transient receptor potential melastatin 4 (*TRPM4*) gene. The clinical significance of this mutation in our patient remains unclear.

Keywords: Gitelman syndrome, Grave's disease, *TRPM4* mutation

Introduction

Gitelman syndrome (GS), also known as familial hypokalemia-hypomagnesemia syndrome, is a rare autosomal recessive genetic disorder that results in a specific defect in renal tubular function. The GS is caused by the loss of function mutation of solute carrier family-12 member-3 (*SLC12A3*) gene, which encodes for thiazide sensitive sodium-chloride (NaCl) cotransporter of the distal convoluted tubule.^[1] The impaired function of thiazide-sensitive NaCl cotransporter causes renal sodium and potassium loss, resulting in volume depletion and hypokalemia. GS is also characterized by metabolic alkalosis, hypomagnesemia, and hypocalciuria.^[2] The clinical manifestations of GS are widely variable, ranging from asymptomatic cases to severe symptoms. Grave's disease (GD) is a common cause of hyperthyroidism, caused by autoantibodies to the thyroid-stimulating hormone (TSH) and thyrotropin receptor (TRAb), which activate the receptor, thereby stimulating thyroid hormone synthesis.

The concurrent occurrence of GS and GD is very rare, and very few such cases

This is an open access journal, and articles are distributed under the terms of the Creative Commons Attribution-NonCommercial-ShareAlike 4.0 License, which allows others to remix, tweak, and build upon the work non-commercially, as long as appropriate credit is given and the new creations are licensed under the identical terms.

For reprints contact: WKHLRPMedknow_reprints@wolterskluwer.com

have been reported in the literature, almost exclusively from east-Asian countries.^[3-7] We describe a case of an adult male with GS-like tubulopathy, which manifested concurrently with GD, and his genetic analysis revealed a mutation in the transient receptor potential melastatin 4 (*TRPM4*) gene.

Case Presentation

A 45-year-old male with no comorbid illnesses presented to us in August 2020 with recurrent episodes of giddiness and fatigability for 2 years. He had intermittent fever, worsening weakness, muscle cramps, and difficulty in climbing stairs for 2 weeks. He had a weight loss of 5 kg over a period of 3 weeks and had recurrent episodes of palpitation and diaphoresis. He had received paracetamol, oral cephalosporin, and intravenous fluids for hypotension prior to admission to our hospital. He did not have a history of laxative abuse, administration of aminoglycoside, or a diuretic. He was born to a non-consanguineous parent and has five siblings. There was no history of similar illnesses in the family.

The physical examination revealed features of Marfanoid habitus, such as tall stature, high arched palate, wrist sign [Figure 1a] and thumb [Figure 1b], arachnodactyly [Figure 1c], wasting

How to cite this article: Kumar RK, Srimathy V, Annigeri RA. Concurrent gitelman syndrome-like tubulopathy and grave's disease. Indian J Nephrol 2022;31:275-8.

**Rajasekaran
Kishore Kumar,
Venkatesh Srimathy,
Rajeev A. Annigeri**

Department of Nephrology
and General Medicine, Apollo
Hospitals, Gream's Lane,
Chennai, Tamil Nadu, India

Received: 05-12-2020

Revised: 08-02-2021

Accepted: 02-01-2022

Published: 20-05-2022

Address for correspondence:

Dr. Rajeev A. Annigeri,
Department of Nephrology,
Apollo Hospitals,
Chennai - 600 006, Tamil Nadu,
India.
E-mail: rajeevnephro@gmail.
com

Access this article online

Website: www.indianj nephrol.org

DOI: 10.4103/ijn.IJN_532_20

Quick Response Code:



of muscles in the upper [Figure 1d] and lower limbs, and a blood pressure of 110/70 mm Hg. The laboratory tests at the time of admission were as follows: urine albumin- nil, plenty of WBC and occasional RBCs per high power field, hemoglobin- 11.7 gm/dL, WBC count- 15,260/mm³ (neutrophils: 81%, lymphocytes: 13%, monocytes: 6%), platelet count- 455,000/mm³, blood urea- 25 mg/dL, serum creatinine- 0.8 mg/dL, serum sodium- 133 mEq/L, serum potassium- 2.5 mEq/L, serum chloride- 83 mEq/L, serum CO₂- 38 mEq/L, serum magnesium- 1.4 mg/dL, random blood glucose- 95 mg/dL, serum protein- 7.5 gm/dL, serum albumin- 3.5 gm/dL, serum bilirubin- 1.8 mg/dL (direct: 0.6 mg/dL), serum ALT- 20 U/L, serum alkaline phosphatase- 96 U/L, serum GTT- 64 U/L, serum-free T4- 6.2 ng/mL (normal: 0.6–1.6), serum-free T3- 11.6 pg/mL (normal: 2.1–4.4), serum thyroid-stimulating hormone (TSH)- <0.01 µIU/mL (normal: 0.42–4.2 µIU/mL), anti-TSH receptor antibodies- 5.5 IU/L (normal: <1.5 IU/L), arterial blood gas analysis at room air: pH- 7.595, PCO₂- 36.5 mm Hg, pO₂- 93 mm Hg, HCO₃- 34.1 mEq/L. Serum cortisol was 21.4 µg/dL (normal: 5–23) at 8 am and 11.0 µg/dL (normal: 3–16) at 4 pm. The ECG showed prolonged QT interval (509 ms). Further evaluation showed evidence of renal potassium wasting and hypocalciuria. Urine potassium to creatinine ratio was markedly increased at 53.2 mEq/gm creatinine, (normal: <13.5 mEq/gm in the presence of hypokalemia). Urine calcium to creatinine ratio was relatively low at 0.087 mg/gm. The fractional excretion of magnesium was 7.91% when serum magnesium was 1.1 mg/dL, indicating renal magnesium wasting.

A tentative diagnosis of GS was made on the findings of hypokalemia, renal potassium wasting, hypomagnesemia, renal magnesium wasting, metabolic alkalosis, relatively low urine calcium excretion in a normotensive adult. A diagnosis of GD was made based on hyperthyroidism with low serum TSH levels and the presence of anti-TSH receptor antibodies.

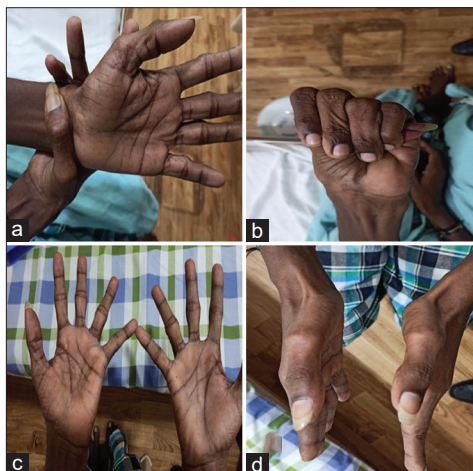

Figure 1: Morphological features; (a) Wrist sign, (b) Thumb sign, (c) Distal muscle wasting, (d) Arachnodactyly

He received intravenous potassium chloride (KCl) in 0.9% saline for the first 3 days and oral KCl for the next 6 days till the serum potassium was normalized [Figure 2]. He also received intravenous magnesium sulphate 2 gm on day 2 and oral magnesium oxide varying from 800 to 1200 mg/day. The serial serum potassium and magnesium concentration during the 7 days of hospitalization are shown in Figure 2. He also received neomercazole 10 mg three times a day for hyperthyroidism. His blood pressure remained low, and he had episodes of diaphoresis and received 0.9% saline intermittently. He was initially treated with Indomethacin 25 mg twice daily for 2 days, and once his blood pressure stabilized, he was initiated on oral eplerenone 12.5 mg twice daily, with which hypokalemia was corrected. He received magnesium oxide 400 mg thrice daily for persistent hypomagnesemia. A month later, serum potassium was 3.7 mEq/L and serum magnesium was 1.5 mg/dL while on eplerenone 25 mg per day and magnesium oxide 1200 mg/day.

Genetic analysis by target gene sequencing showed an autosomal dominant heterozygous mutation in exon 14 of *TRPM4* gene that resulted in the amino acid substitution of asparagine for serine at codon 633 of chromosome 19, and no mutations were detected in *SLC12A3* and *CLCNKB* genes.

Discussion

Thyroid hormone directly influences the expression and activity of several ion channels and transporters in the renal tubules, which affect the transport of sodium, potassium, calcium, hydrogen, bicarbonate, and water.^[8] Hyperthyroidism may cause polyuria due to direct downregulation of aquaporin 1 and 2, whereas electrolyte abnormalities are not usually seen.^[8] The common cause of hypokalemia in hyperthyroid patients is due to thyrotoxic hypokalemic periodic paralysis (THPP), which occurs predominantly in adult Asian males and sporadically in other races.^[7] Patients present with transient, recurrent hypokalemic paralysis, which is due to a shift of potassium into the cells. The intracellular shift is hypothesized to occur

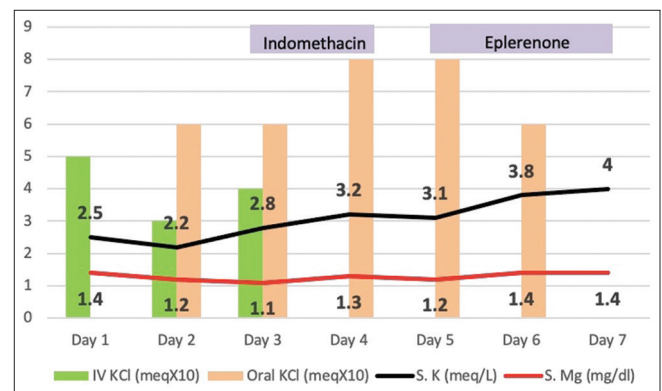


Figure 2: Serial serum potassium and magnesium levels and potassium supplements received by the patient during hospitalization

due to increased activity of Na-K ATPase and increased sensitivity to insulin.^[9] In contrast to GS, THPP is not associated with renal potassium and magnesium wasting and acid-base abnormality. The tubulopathy associated with GS in a hyperthyroid patient is often confused with THPP, which is a more common cause of hypokalemia in them unless a detailed assessment to determine the urinary potassium and magnesium wasting is done.^[6]

A few cases of concurrent occurrence of GS and autoimmune thyroid disease have been reported in the literature.^[3-7] In 2018, Zhou *et al.*^[3] reviewed 18 cases of GS and GD published in the literature till then. They found that 13 patients had GD and GS, and all except one had mutations in the *SLC12A4* gene and all the cases were reported from East Asian populations. A case report from Turkey described a 35-year-old male from Turkey with thyrotoxicosis presenting with GS who was found to have a homozygous mutation in the *SLC12A3* gene.^[4]

Our patient fulfilled the biochemical criteria for the diagnosis of GS.^[2] He presented with volume depletion, hypokalemia with evidence of renal potassium wasting, hypomagnesemia with evidence of renal magnesium wasting, metabolic alkalosis, and hypocalciuria. However, the genetic analysis did not show mutation in the *SCL12A3* and *CLCNKB* genes. Instead, a mutation in exon 14 of the *TRPM4* gene that resulted in the amino acid substitution of asparagine for serine at codon 633 of chromosome 19 was detected in him. Thus, we classified the renal tubular disorder as Gitelman syndrome-like tubulopathy. The classical GS is an inherited disorder due a mutation in the *SCL12A3* gene. However, there are several reports of acquired GS and are reported due to cisplatin, autoimmune disorders and iritis and arthritis, and Sjogren's syndrome, presumably due to autoantibodies to the components of renal tubules.^[2,10] Our patient had concurrent autoimmune disease in the form of GD, and we presume that autoimmune disorder may underlie the manifestation of GS-like syndrome. It is unclear whether an association of GS and GD is by chance or due to a common pathogenic cause. Most of the cases of GS associated with GD described in the literature had mutations in the *SLC12A4* gene seen in classical GS. However, an autoimmune cause common to both syndromes may explain the atypical GS-like syndrome seen in our patient.

Our patient had a few unusual features such as Marfan-like habitus and later-than-usual age for presentation for GS. We do not know the significance of a mutation in the *TRPM4* gene in him in relation to the GS-like syndrome. Whether these features constitute a different form of inherited disorder causing GS-like syndrome needs more exploration. He was initiated on eplerenone as it appears to have a direct effect on the mineralocorticoid receptor and less effect on other steroid hormone receptors compared to spironolactone.^[11] Eplerenone effectively

corrected hypokalemia, but hypomagnesemia persisted and required additional oral magnesium supplements. Treatment to correct hyperthyroidism did not ameliorate the electrolyte abnormalities, indicating that hyperthyroid state was not a major contributor to electrolyte abnormalities in him.

In recent years, the superfamily of transient receptor potential (TRP) ion channels has emerged as central players in human renal physiology and are involved in the filtration, secretion, and absorption of electrolytes in the kidney.^[12] The TRPM family is named after melastatin, the first member identified, and the physiological function of them the least well characterized of all the TRP family.^[13] The TRPM6 is critically involved in the transcellular transport of Mg^{2+} in the kidney, and the loss of function mutation in TRPM6 causes hypomagnesemia and secondary hypocalcemia (HSH).^[12] The TRPM4 is a nonselective cation channel activated by intracellular Ca^{2+} , by itself is impermeable to Ca^{2+} , but transports monovalent cations. The TRPM4 channel exhibits voltage dependency, which is not described for any other TRP channel.^[14] At negative membrane potential TRPM4 allows Na^{+} influx and at positive membrane potential, it permits cellular K^{+} efflux. The loss of function mutation of the *TRPM4* gene is implicated in inherited cardiac diseases, including conduction blocks and Brugada syndrome, cardiac hypertrophy, and myocardial ischemia-reperfusion injury.^[15] Our patient did not exhibit any symptoms, and clinical evaluation did not suggest any cardiac abnormalities generally associated with this mutation. The QT interval was prolonged in our patient, which was attributed to hypokalemia. He or any family member did not have a history of cardiac conduction abnormality, which is associated with mutations in the *TRPM4* gene.

The TRPM4 channel is expressed in the kidney and is shown to be localized to epithelial cell cilia.^[16] However, its physiological role in the kidney is yet unclear, and no renal disease linked to mutations in TRPM4 has been described so far. With progress in the research of TRPM4, we are likely to witness more insights into its physiological role and pathological role in cardiovascular and other organs, including the kidney. The association of the gene mutation incidentally detected in our patient has not been previously shown to be associated with the phenotype seen in our patient, either in humans or in animal models, and hence its role in the cause of tubulopathy is speculative at best.

In conclusion, we described a patient with concurrent GD and GS-like tubulopathy who was found to have a mutation in the *TRPM4* gene, the significance of which with respect to our patient remains unclear. Eplerenone therapy mitigated hypokalemia, whereas hypomagnesemia required oral magnesium supplements to maintain near normal serum magnesium concentration.

Declaration of patient consent

The authors certify that they have obtained all appropriate patient consent forms. In the form, the patient(s) has/have given his/her/their consent for his/her/their images and other clinical information to be reported in the journal. The patients understand that their names and initials will not be published and due efforts will be made to conceal their identity, but anonymity cannot be guaranteed.

Financial support and sponsorship

Nil.

Conflicts of interest

There are no conflicts of interest.

References

1. Simon DB, Nelson-Williams C, Bia MJ, Ellison D, Karet FE, Molina AM, *et al.* Gitelman's variant of Bartter's syndrome, inherited hypokalaemic alkalosis, is caused by mutations in the thiazide-sensitive Na-Cl cotransporter. *Nat Genet* 1996;12:24-30.
2. Blanchard A, Bockenbauer D, Bolignano D, Calò LA, Cosyns E, Devuyt O, *et al.* Gitelman syndrome: Consensus and guidance from a Kidney disease: Improving global outcomes (KDIGO) controversies conference. *Kidney Int* 2017;91:24-33.
3. Zhou H, Liang X, Qing Y, Meng B, Zhou J, Huang S, *et al.* Complicated Gitelman syndrome and autoimmune thyroid disease: A case report with a new homozygous mutation in the SLC12A3 gene and literature review. *BMC Endocr Disord* 2018;18:82.
4. Baldane S, Ipekci SH, Celik S, Gundogdu A, Kebapcilar L. Hypokalemic paralysis due to thyrotoxicosis accompanied by Gitelman's syndrome. *Indian J Nephrol* 2015;25:103-5.
5. Imashuku S, Teramura-Ikeda T, Kudo N, Kaneda S, Tajima T. Concurrence of thyrotoxicosis and Gitelman's syndrome-associated hypokalemia-induced periodic paralysis. *Pediatr Rep* 2012;4:e18.
6. Oba T, Kobayashi S, Nakamura Y, Nagao M, Nozu K, Fukuda I, *et al.* A case of Gitelman syndrome that was difficult to distinguish from hypokalemic periodic paralysis caused by Graves' disease. *J Nippon Med Sch* 2019;86:301-6.
7. Mizokami T, Hishinuma A, Kogai T, Hamada K, Maruta T, Higashi K, *et al.* Graves' disease and Gitelman syndrome. *Clin Endocrinol (Oxf)* 2016;84:149-50.
8. Mariani LH, Berns JS. The renal manifestations of thyroid disease. *J Am Soc Nephrol* 2012;23:22-6.
9. Pompeo A, Nepa A, Maddestra M, Feliziani V, Genovesi N. Thyrotoxic hypokalemic periodic paralysis: An overlooked pathology in western countries. *Eur J Intern Med* 2007;18:380-90.
10. Kim YK, Song HC, Kim YS, Choi EJ. Acquired gitelman syndrome. *Electrolyte Blood Press* 2009;7:5-8.
11. Ito Y, Yoshida M, Nakayama M, Tsutaya S, Ogawa K, Maeda H, *et al.* Eplerenone improved hypokalemia in a patient with Gitelman's syndrome. *Intern Med* 2012;51:83-6.
12. Dietrich A, Chubanov V, Gudermann T. Renal TRPChannels. *J Am Soc Nephrol* 2010;21:736-44.
13. Nilius B, Prenen J, Droogmans G, Voets T, Vennekens R, Freichel M, *et al.* Voltage dependence of the Ca²⁺-activated cation channel TRPM4. *J Biol Chem* 2003;278:30813-20.
14. Launay P, Fleig A, Perraud AL, Scharenberg AM, Penner R, Kinet JP. TRPM4 is a Ca²⁺-activated nonselective cation channel mediating cell membrane depolarization. *Cell* 2002;109:397-407.
15. Guinamard R, Bouvagnet P, Hof T, Liu H, Simard C, Sallé L. TRPM4 in cardiac electrical activity. *Cardiovasc Res* 2015;108:21-30.
16. Flannery RJ, Kleene NK, Kleene SJ. A TRPM4-dependent current in murine renal primary cilia. *Am J Physiol Renal Physiol* 2015;309:F697-707.