



A Case of Acute Renal Infarct Secondary to Protein S Deficiency

Abstract

Renal infarction is an underdiagnosed and underreported condition with multiple etiologies. A 45-year-old man presented with acute pain in the right lumbar region, CT scan showed a wedge shaped, non-enhancing, hypodense lesion in the cortex of the upper pole of the right kidney- suggestive of infarct. A pro-thrombotic workup revealed a protein S deficiency and a heterozygous mutation for MTHFR gene. Protein S is a vitamin-K dependent plasma glycoprotein, the deficiency of which is associated with a hypercoagulable state, which in turn led to renal infarction in this patient.

Keywords: Hypercoagulable state, MTHFR mutation, protein S deficiency, renal infarction, thromboembolism

Introduction

Renal infarction is underreported, with a reported incidence of 0.004% - 0.007%.¹ It presents with flank pain, fever, nausea, vomiting, hematuria, and sudden rise in blood pressure or can mimic pyelonephritis, renal colic, or other diseases. Delayed or missed diagnosis results in irreversible injury to the kidneys. Timely revascularization can restore renal function.

Numerous etiologies lead to the development of renal infarction, but thromboembolism of cardiac origin atheromatous disease are the most frequent. Less common causes identified include hypercoagulable conditions (sickle cell disease, thrombophilia), cocaine misuse, trauma to the kidneys, malignancies, and renal vascular disease (vasculitis, fibromuscular dysplasia, spontaneous renal artery dissection, and dissecting aortic aneurysm). Rare causes include septic emboli in systemic candidiasis or emboli in Takotsubo syndrome. The underlying cause of renal infarction may be unknown despite extensive investigations, and these are labeled idiopathic renal infarcts.¹ Only about 6% of the cases occur due to a hypercoagulable state.²

Case Report

A 45-year-old nonsmoker male presented with acute pain in the right lumbar region and fever, without associated chills, rashes, or joint pain. He had no nausea, vomiting, abdominal distension, bowel or urinary symptoms, abdominal trauma, illicit drug use, or alcohol abuse. He gave no past history of renal stones, cardiac disease, or any chronic diseases or surgeries; there was no family history of blood disorders or malignancies.

On examination, he was conscious and oriented and the vital signs were normal. Mild tenderness was noted in the right lumbar region. Chest examination was within normal limits with no cardiac murmurs. The remaining physical evaluation was unremarkable.

Laboratory results showed normal white blood cell (WBC) count, renal function, and urinalysis, with no growth on urine culture. Abdominal ultrasound showed an enlarged fatty liver and prostate. Contrast-enhanced computed

tomography (CECT) of the abdomen revealed a wedge-shaped, nonenhancing, hypodense lesion in the cortex of the upper pole of the right kidney, suggestive of infarct [Figure 1]. Renal artery Doppler was normal.

A 12-lead electrocardiogram did not reveal atrial fibrillation, and the transthoracic echocardiogram was normal. A prothrombotic workup showed protein S deficiency and a heterozygous mutation in *MTHFR* gene.

The patient was started on dual antiplatelets and anticoagulants. The pain gradually subsided, and he was discharged with dual antiplatelets and oral anticoagulation. Follow-up revealed no further episodes, and renal function remained normal.

Discussion

Renal infarction is an unusual cause of abdominal pain. Based on autopsy data, a previous study estimated the incidence of renal infarction as 1.4%;³ however, only a few cases are reported due to the nonspecific presentation. The patients could even be asymptomatic, wherein the diagnosis is only identified incidentally on computed tomography (CT) scan.

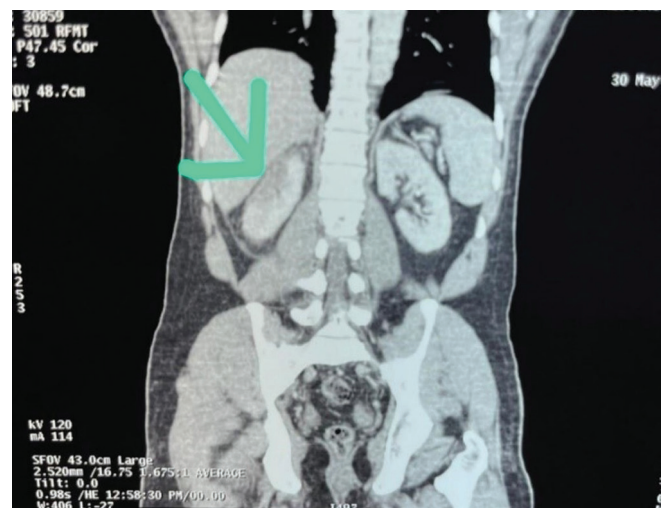


Figure 1: CT abdomen showing infarct in the right kidney. The green arrow marks the wedge-shaped hypodense lesion in the cortex of the upper pole of the right kidney. CT = computed tomography.

WBC counts, C-reactive protein (CRP), alkaline phosphatase, and transaminases are often raised, though not consistently. Raised lactate dehydrogenase (LDH) is sensitive, but not specific.⁴ Raised serum creatinine may also be seen. Doppler has low sensitivity for identifying renal ischemia (10%).⁵ Renal artery angiography is the gold standard for diagnosis. It typically demonstrates wedge-shaped patches of hypoattenuation within the renal parenchyma, indicating perfusion defect. Etiological investigation requires electrocardiogram (ECG), Holter monitoring, echocardiography, CT angiography, hypercoagulability panel, and autoantibody assay.

A small percentage is caused by hypercoagulable diseases – antiphospholipid syndrome (APS), protein C, S, or factor V Leiden deficits, hyperhomocysteinemia, and polycythemia vera. In this patient, the underlying protein S deficiency was considered the likely cause of renal infarction. Protein S is a vitamin K-dependent plasma glycoprotein, acting as a cofactor for the activated protein C (APC) and tissue factor pathway inhibitor (TFPI) pathways. In addition, it inhibits the intrinsic tenase and prothrombinase complexes, thus having direct anticoagulant actions.⁶ Thus, patients deficient in protein S are at risk of developing recurrent thromboembolic events. Here, a heterozygous mutation in *MTHFR* manifested clinically, possibly contributing to the hypercoagulable state.

Treatment aims to restore blood flow to the kidneys early and prevent further embolic episodes. Treatment depends on the underlying etiology and needs to be tailored for each patient. It is mainly based on anticoagulants, and antiplatelets in select patients.

Conclusion

Given the nonspecific presentation, a high index of clinical suspicion should be maintained for early identification of renal infarction and its etiology, to avoid prolonged ischemia and irreversible renal damage.

Declaration of patient consent

The authors certify that they have obtained all appropriate patient consent

Conflicts of interest

There are no conflicts of interest.

**Daniel Sam Mathews¹, Ninoo George²,
Ranjit Jeyasekharan¹**

Departments of ¹General Medicine and ²Nephrology, Dr. Jeyasekharan Hospital, Nagercoil, Tamil Nadu, India

Corresponding author:

Daniel Sam Mathews, Department of General Medicine, Dr. Jeyasekharan Hospital, Nagercoil, Tamil Nadu, India. E-mail: dxdanies@gmail.com

References

1. Bourgault M, Grimbert P, Verret C, Pourrat J, Herody M, Halimi JM, *et al.* Acute renal infarction: A case series. *Clin J Am Soc Nephrol* 2013;8:392–8.
2. Oh YK, Yang CW, Kim YL, Kang SW, Park CW, Kim YS, *et al.* Clinical characteristics and outcomes of renal infarction. *Am J Kidney Dis* 2016;67:243–50.
3. Hoxie HJ, Coggin CB. Renal infarction: Statistical study of two hundred and five cases and detailed report of an unusual case. *Arch Intern Med* 1940;65:587–94.
4. Hritani A, Jo-Hoy F, Siddiqi A, Baldeo C, Poenariu A. Acute renal infarction pathogenesis and atrial fibrillation: Case report and literature review. *World J Nephrol Urol* 2016;5:11–5.
5. Hedhli H, Ouanes Y, Bibi M, Mraddeli K, Benhouma S, Nouira Y. Idiopathic renal infarction: A new case report. *Urol Case Rep* 2021;39:101752.
6. Gierula M, Ahnström J. Anticoagulant protein S—New insights on interactions and functions. *J Thromb Haemost* 2020;18:2801–11.

This is an open access journal, and articles are distributed under the terms of the Creative Commons Attribution-NonCommercial-ShareAlike 4.0 License, which allows others to remix, tweak, and build upon the work non-commercially, as long as appropriate credit is given and the new creations are licensed under the identical terms.

How to cite this article: Mathews DS, George N, Jeyasekharan R. A Case of Acute Renal Infarct Secondary to Protein S Deficiency. *Indian J Nephrol*. doi: 10.25259/ijn_522_23

Received: 24-11-2023; **Accepted:** 04-12-2023;

Online First: 10-06-2024; **Published:** ***

DOI: 10.25259/ijn_522_23

