

## Crystalline Nephropathy due to APRT Deficiency: A Preventable Cause of Renal and Renal Allograft Failure

### Abstract

Adenine phosphoribosyl transferase (APRT) deficiency, a rare inborn error of metabolism is inherited as an autosomal recessive trait. It presents with 2,8-dihydroxyadenine (2,8-DHA) crystal nephropathy and recurrent nephrolithiasis and often progresses to end stage renal disease (ESRD). After transplant, it can recur in the allograft. If APRT deficiency is recognized early, renal failure can be prevented, arrested or reversed in native kidney and in allograft by treatment with allopurinol, which inhibits xanthine oxidase and reduces 2,8-DHA formation. We report two cases of APRT deficiency from our center. DNA sequencing of APRT gene performed in one of the cases revealed a pathogenic variant in Exon1 of APRT gene (c.3G>C; p.Met1). This variant affects the translation initiation codon and results in a start loss. The variant has previously been reported in two cases with APRT deficiency.

**Keywords:** 2,8 DHA crystalluria, Adenine phosphoribosyl transferase deficiency, crystalline nephropathy, recurrence post transplantation

### Introduction

Adenine phosphoribosyltransferase (APRT) deficiency is a rare autosomal recessive inherited disorder of purine metabolism. The APRT gene is located on chromosome 16 (16q24). APRT catalyzes the formation of adenosine monophosphate from adenine accomplishing the elimination of free adenine derived from the diet or released as a waste product of the polyamine pathway. In the absence of APRT activity, adenine is catabolized by xanthine oxidase to 2,8-dihydroxyadenine (DHA), which is excreted in the urine [Figure 1]. DHA is insoluble in the urine at the physiological range of pH, which may lead to crystalluria. Because there are individual differences in the ability to supersaturate the urine with DHA, the clinical manifestations vary among homozygotes from asymptomatic state to reddish-brown diaper stains in infants and to recurrent nephrolithiasis in children and adults.<sup>[1]</sup> Some patients develop chronic kidney disease secondary to stone disease and recurrent urinary tract infection.<sup>[1]</sup> Very rarely, DHA crystals may deposit in tubular lumina and interstitium and lead to irreversible renal damage in the absence of history of nephrolithiasis.<sup>[1-3]</sup>

This is an open access journal, and articles are distributed under the terms of the Creative Commons Attribution-NonCommercial-ShareAlike 4.0 License, which allows others to remix, tweak, and build upon the work non-commercially, as long as appropriate credit is given and the new creations are licensed under the identical terms.

For reprints contact: reprints@medknow.com

DHA stones are radiolucent and hence often misdiagnosed as uric acid stones since the standard chemical tests done on calculi do not distinguish between these two types. On the other hand, DHA crystals in renal biopsies may be confused with oxalate crystals as both are strongly birefringent and both deposit in tubular lumina, tubular cell cytoplasm, and interstitium, resulting in an erroneous diagnosis of oxalosis. Accurate diagnosis of DHA disease is crucial since early treatment with allopurinol effectively prevents further stone formation and may improve renal function in patients with parenchymal crystal deposition.<sup>[1,2,4,5]</sup>

In this report, we describe two patients of end stage renal disease with crystalline nephropathy due to APRT deficiency, who had early recurrence in the allograft. This was diagnosed on allograft biopsies and successfully treated with allopurinol.

### Case Histories

#### Case 1

A 43-year-old male with ESRD of unknown etiology, on maintenance hemodialysis, presented to us in July 2013 for kidney transplant. On August 27, 2013, kidney transplant was done with mother as donor. Immediate post-transplant course was uneventful, and he stabilized at creatinine

**How to cite this article:** Rajput P, Virani ZA, Shah BV. Crystalline nephropathy due to APRT deficiency: A preventable cause of renal and renal allograft failure. Indian J Nephrol 2020;30:290-2.

**Prashant Rajput,  
Zaheer A. Virani,  
Bharat V. Shah**

Department of Nephrology,  
Institute of Renal Sciences,  
Global Hospital Parel-12,  
Mumbai, Maharashtra, India

Received: 27-03-2019

Revised: 09-05-2019

Accepted: 12-09-2019

Published: 01-04-2020

#### Address for correspondence:

Dr. Bharat V. Shah,  
A-1, Navsaryukta Apartment,  
Behind Jai Mata Di Temple,  
Guru Hargovindji Road,  
Chakala, Andheri (East),  
Mumbai, Maharashtra, India.  
E-mail: dr\_bharatvshah@yahoo.  
co.in

#### Access this article online

Website: www.indianj nephrol.org

DOI: 10.4103/ijn.IJN\_106\_19

#### Quick Response Code:



of 1.3 mg/dl. His maintenance immunosuppression included prednisolone, tacrolimus and mycophenolate sodium. Two months after transplant, there was graft dysfunction. Allograft biopsy was performed which showed reddish brown crystals in many tubules [Figure 2]. Oxalosis was suspected but ruled out as 24-hour urinary oxalate was normal and there was no nephrocalcinosis of native kidneys on a plain X ray. 2,8 DHA crystaluria was suspected. A 24-hour urine sample was sent to National University Hospital of Iceland; Department of Laboratory Hematology; APRT Deficiency Research Program; K-Building, Second Floor Hringbraut 101 Reykjavik Iceland.

The urinary 2,8, DHA was 29932 ng/ml and urine 2,8, DHA/creatinine was 6849 ng/mmol of creatinine confirming 2,8, DHA Crystaluria. DNA sequencing of APRT gene was performed which revealed a pathogenic variant in Exon1 of APRT gene (c.3G>C; p.Met1). This variant affects the translation initiation codon and results in a start loss. The variant has previously been reported in two cases with APRT deficiency.

On enquiry, he did give history of passing kidney stones in the past. He was treated with allopurinol with gradual improvement of his allograft function.

### Case 2

A 31-year-old male had a history of Chronic Kidney Disease (Sr Creatinine 3 mg/dl) due to bilateral kidney stones in 2006. He underwent bilateral percutaneous nephrolithotomy (PCNL). His stone analysis was reported as pure uric acid stones (98%). He progressed to ESRD in 2014 and was initiated on maintenance dialysis. He underwent living donor renal transplant at another center in August 2014. His immediate post-transplant course was uneventful, and his creatinine was 1 mg/dl. Two months post-transplant he had an acute allograft dysfunction (Sr Creatinine 1.8 mg/dl) and an allograft biopsy was performed which showed reddish brown crystals in the tubules and interstitium. Primary oxalosis was suspected and he was put on treatment with hydration and pyridoxine. The 24-hour urinary oxalate was normal and genetic workup for primary hyperoxaluria was normal. He presented to us with worsening of allograft function (serum creatinine 3.8 mg/dl). His biopsy was reviewed, which revealed crystal nephropathy. His urine analysis was performed which showed 2,8 DHA crystals (Tree ring pattern) [Figure 3]. He was treated with allopurinol (300 mg/day) with significant improvement in his renal function and last serum creatinine was 1.2 mg/dl.

### Discussion

We describe 2 cases of APRT deficiency where diagnosis was made only after renal transplantation. Few cases of APRT deficiency, with recurrent 2,8-DHA lithiasis have been reported in renal transplant recipients up to now. All of them were diagnosed only after transplantation, as in

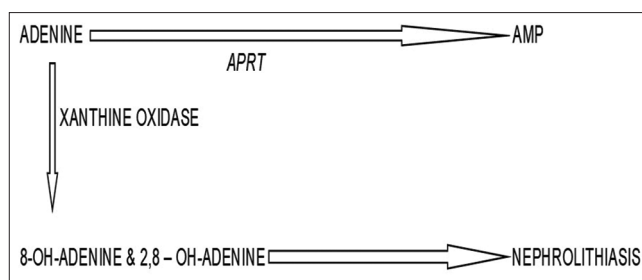


Figure 1: APRT is an enzyme that normally catalyzes the conversion of adenine to adenine monophosphate. In the absence of APRT activity, accumulated adenine is catabolized by xanthine oxidase to 2,8-dihydroxyadenine (DHA), which is excreted in the urine.

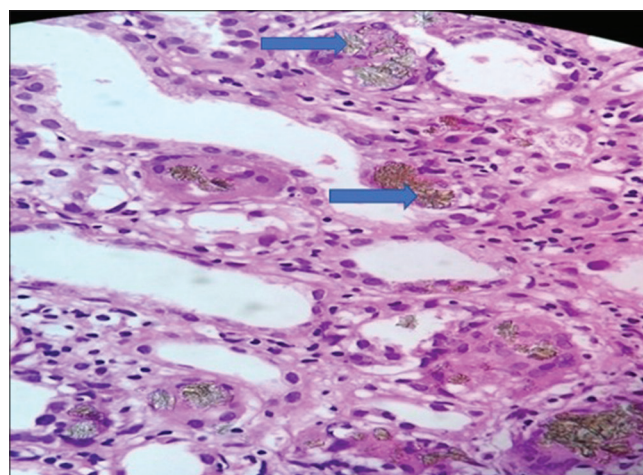


Figure 2: Renal biopsy showing reddish brown crystals (blue arrows) in the tubules.

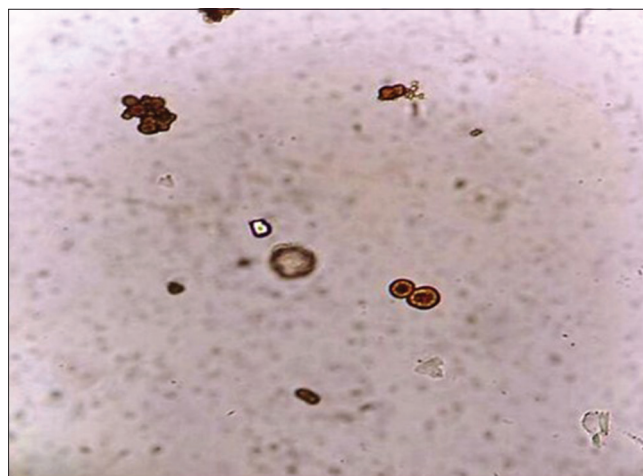


Figure 3: DHA crystals (Tree ring pattern) in the urine.

our patients.<sup>[4,6-9]</sup> The first case from India where all three diagnostic parameters (stone analysis, urine DHA crystals having Maltese cross pattern, and blood genetic analysis) were confirmed to diagnose APRT deficiency was reported in 2017 by Krishnappa P *et al.* in a 2-year-old female.<sup>[10]</sup> This, however, was not in the transplant setting.

2,8-DHA stones are often misdiagnosed as uric acid stones since both types of stones are radiolucent and they cannot

be distinguished by routine chemical tests for stone analysis, including colorimetric reactions, and thermogravimetric reactions.<sup>[9]</sup> Ultraviolet or infrared spectrophotometry is required for this distinction. The incorrect diagnosis of uric acid stones leads to treatment with allopurinol and low-purine diet, which are also effective measures in preventing 2,8-DHA stones. Therefore, patients with DHA stones are being successfully treated but with incorrect diagnosis.

2,8-DHA crystals may be seen in the urine and can provide a valuable clue to the diagnosis when recognized. Due to their rarity, however, laboratory personnel may not note them nor appreciate their significance.<sup>[1]</sup> Similarly, many pathologists are not familiar with DHA crystals, and the accurate diagnosis is typically made, retrospectively, after the disease recurs in the transplant.

The patients with 2,8-DHA crystalline nephropathy present with recurrent nephrolithiasis, which may lead to chronic kidney disease, secondary to obstructive nephropathy and recurrent urinary tract infections. Rarely severe renal failure due to 2,8-DHA crystalline nephropathy in adulthood, without any history of stones has been reported.<sup>[1-3]</sup>

The diagnosis of 2,8-DHA crystalline nephropathy is confirmed by measurement of APRT activity in red blood cells. The management of these patients includes a low-purine diet, high fluid intake and treatment with allopurinol. This regimen prevents recurrence of nephrolithiasis and can provide preservation of renal function or even improvement of renal function if initiated early enough.<sup>[1]</sup>

In summary, 2, 8-DHA crystal nephropathy should be considered in the differential diagnosis of any form of recurrent nephrolithiasis. A high index of suspicion is needed because this condition may be underdiagnosed or misdiagnosed. With early diagnosis, renal failure can be prevented, reversed or arrested by simple treatment with allopurinol.

#### Declaration of patient consent

The authors certify that they have obtained all appropriate patient consent forms. In the form the patient(s) has/have given his/her/their consent for his/her/their images and other clinical information to be reported in the journal. The

patients understand that their names and initials will not be published and due efforts will be made to conceal their identity, but anonymity cannot be guaranteed.

#### Financial support and sponsorship

Nil.

#### Conflicts of interest

There are no conflicts of interest.

#### References

1. Edvardsson V, Palsson R, Olafsson I, Hjaltadottir G, Laxdal T. Clinical features and genotype of adenine phosphoribosyltransferase deficiency in Iceland. *Am J Kidney Dis* 2001;38:473-80.
2. Arnadottir M, Laxdal T, Hardarson S, Asmundsson P. Acute renal failure in a middle-aged woman with 2,8-dihydroxyadeninuria. *Nephrol Dial Transplant* 1997;12:1985-7.
3. Brown HA. Recurrence of 2,8-dihydroxyadenine tubulointerstitial lesions in a kidney transplant recipient with a primary presentation of chronic renal failure. *Nephrol Dial Transplant* 1998;13:998-1000.
4. Benedetto B, Madden R, Kurbanov A, Braden G, Freeman J, Lipkowitz GS. Adenine phosphoribosyltransferase deficiency and renal allograft dysfunction. *Am J Kidney Dis* 2001;37:E37.
5. Greenwood MC, Dillon MJ, Simmonds HA, Barratt TM, Pincott JR, Metreweli C. Renal failure due to 2,8-dihydroxyadenine urolithiasis. *Eur J Pediatr* 1982;138:346-9.
6. Cassidy MJD, McCulloch T, Fairbanks LD, Simmonds HA. Diagnosis of adenine phosphoribosyltransferase deficiency as the underlying cause of renal failure in a renal transplant recipient. *Nephrol Dial Transplant* 2004;19:736-8.
7. Gagne ER, Deland E, Daudon M, Noël LH, Nawar T. Chronic renal failure secondary to 2,8-dihydroxyadenine deposition: The first case of recurrence in a renal transplant. *Am J Kidney Dis* 1994;24:104-7.
8. Eller P, Rosenkranz AR, Mark W, Theurl I, Laufer J, Lhotta K. Four consecutive renal transplantations in a patient with adenine phosphoribosyltransferase deficiency. *Clin Nephrol* 2004;61:217-21.
9. de Jong DJ, Assmann KJ, De Abreu RA, Monnens LA, van Liebergen FJ, Dijkman HB, *et al.* 2,8-Dihydroxyadenine stone formation in a renal transplant recipient due to adenine phosphoribosyltransferase deficiency. *J Urol* 1996;156:1754-5.
10. Krishnappa P, Krishnamoorthy V, Gowda KK. Dihydroxyadenine stone with adenine phosphoribosyltransferase deficiency: A case report. *Indian J Urol* 2017;33:246-8.