



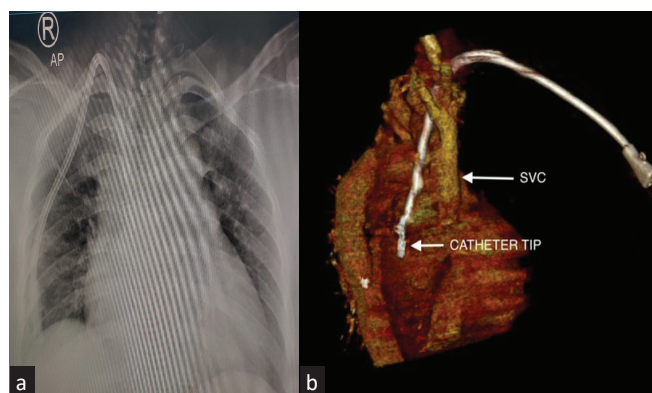
## Accidental Pericardial Placement of Tunneled Cuffed Dialysis Catheter - Lesson to be Learnt

Dear Editor,

Over 80% of patients globally get initiated on hemodialysis with tunneled cuffed catheter (TCC).<sup>1</sup> Right internal jugular vein (IJV) is the preferred site for TCC insertion with catheter tip placement in the mid right atrium.<sup>2</sup> Sometimes, the catheter can be misplaced. We report a case where the catheter tip got accidentally placed in the pericardium.

A 37-year-old lady with crescentic glomerulonephritis underwent TCC placement under fluoroscopy guidance where the post procedure chest X-ray showed the normal position of the catheter [Figure 1]. Misplacement was suspected as there was no flow through the catheter and patient complained of chest discomfort on pushing the fluid. Computed tomography (CT) venography showed that the catheter went through IJV, traversed behind IJV and superior vena cava (SVC), and its tip was lying in the pericardial cavity [Figure 1]. There was no hematoma and the patient was hemodynamically stable. As the catheter was lying outside the vessels, it was pulled back and removed without any complication. Next day, TCC was rightly placed via the right IJV, followed by dialysis.

There are reports of misplacement of TCC into other vessels, pleura or mediastinum.<sup>3</sup> Pericardial migration has been reported when the catheter tip erodes right atrial or lower SVC wall.<sup>4</sup> There is a solitary report of TCC getting placed in the pericardium through atrium in a patient with uremic pericardial effusion.<sup>5</sup> This case report is the only report to the best of our knowledge, where TCC entered the pericardium via mediastinum. This case gives two important messages:



**Figure 1:** (a) Chest X-ray anteroposterior (AP) view showing placement of catheter in the right internal jugular vein, (b) Computed tomography venography showing the catheter traversing behind the superior vena cava (SVC) with the tip lying in pericardium.

(i) If catheter tip has gone through IJV, it can enter the pericardial cavity. In such a scenario, the catheter can be safely removed since it is lying outside the myocardium.

(ii) The dilator should be pushed only up to the vein to be dilated.

It is likely that in our case, the dilator might have been pushed till the hilt, thereby making it an easy access for the catheter to go in the pericardium. Needless to say, post insertion imaging must be done to confirm the catheter position.

**Author contributions:** Concepts, design, definition of intellectual content, literature search, experimental studies, data analysis, statistical analysis, manuscript preparation, manuscript editing and review: MS, PPV; Data acquisition, clinical studies: MS, AJ, PPV. All authors provided final approval to the work.

**Conflicts of interest:** There are no conflicts of interest.

*The authors declare that no generative AI or AI-assisted tools were used in drafting, editing, or preparing this manuscript.*

**Mehak Singla<sup>1</sup>, Ayush Jain<sup>2</sup>, Prem Prakash Varma<sup>1</sup>**

Departments of <sup>1</sup>Nephrology, <sup>2</sup>Radiology, Primus Super Speciality Hospital, Chanakyapuri, New Delhi, India

**Corresponding author:** Mehak Singla, Department of Nephrology, Primus Super Speciality Hospital, Chanakyapuri, New Delhi, India.  
E-mail: paniaahchhabra@gmail.com

### References

1. USRDS Annual Data Report 2021. ESRD in United States. Chapter 4. Vascular Access.
2. KDOQI Clinical Practice Guideline for Vascular Access: 2019 Update.
3. Gibson F, Bodenham A. Misplaced central venous catheters: Applied anatomy and practical management. *Br J Anaesth* 2013;110:333-46.
4. Premuzic V, Katalinic L, Pasalic M, Jurin H. Nonfatal cardiac perforation after central venous catheter insertion. *Saudi J Anaesth* 2018;12:118-20.
5. Jin JZ, Piao SG, Li C. Pericardium catheterization using a tunneled-cuffed catheter for hemodialysis: A lesson. *J Vasc Access* 2024;25:691-2.

This is an open access article under the CC BY-NC-SA license. (<https://creativecommons.org/licenses/by-nc-sa/4.0/deed.en>)

**Received:** 22-07-2024; **Accepted:** 27-08-2024

**Online First:** 04-05-2026; **Published:** \*\*\*

**DOI:** 10.25259/IJN\_406\_2024