



## Purple Urine Bag in a Child

A 13-year-old male presented with rapidly progressive renal failure. He was diagnosed with anti-factor H antibody-positive atypical hemolytic uremic syndrome and managed with plasma exchange. He grew *Klebsiella pneumoniae* in urine, which was sensitive to polymyxin, and the same treatment was initiated. He continued to have fever spikes with pyuria. During the 3<sup>rd</sup> week of hospitalization, purple discoloration was noted in the urine collection bag [Figure 1a], while the urine appeared cola-colored [Figure 1b, arrow]. Regrettably, the patient eventually succumbed to multi-organ dysfunction.

Purple urine bag syndrome (PUBS) is a rare entity seen in the elderly with urinary tract infection. Intestinal bacteria metabolize dietary tryptophan into indole. The liver then converts indole into indoxyl sulfate, which is excreted in urine. Few bacteria, including *Klebsiella*, further digest indoxyl sulfate into indoxyl through the action of sulfatases and phosphatases, leading to indirubin (red) and indigo (blue). These metabolites accumulate in the plastic tubing and catheter, producing a distinct purple color characteristic of purple urine bag syndrome.<sup>1</sup> In a comprehensive literature review by Sabanis *et al.*, involving 246 reported cases, Purple Urine Bag Syndrome was predominantly observed in elderly adults, with a mean

age of 78.9 years, and frequently associated with chronic catheterization, constipation, and CKD.<sup>2</sup> Though reported in adults, it is rare among children. Recognition of PUBS is important to avoid unnecessary investigation and to reassure families, as the visual appearance can be alarming but does not indicate a severe underlying pathology if managed appropriately.<sup>3</sup> PUBS, though rare in children, can be a visual clue to an underlying urinary tract infection.

**Conflicts of interest:** There are no conflicts of interest.

### Use of Artificial Intelligence (AI)-Assisted Technology:

The authors declare that no generative AI or AI-assisted tools were used in drafting, editing, or preparing this manuscript.

**Darshan Rajatadri Rangaswamy<sup>1</sup>, Aliza Mittal<sup>1</sup>,  
Daisy Kherra<sup>1</sup>**

<sup>1</sup>Department of Pediatrics, AIIMS Jodhpur, Jodhpur, India

**Corresponding author:** Aliza Mittal, Department of Pediatrics, AIIMS Jodhpur, Jodhpur, India. E-mail: alizamittal@gmail.com

### References

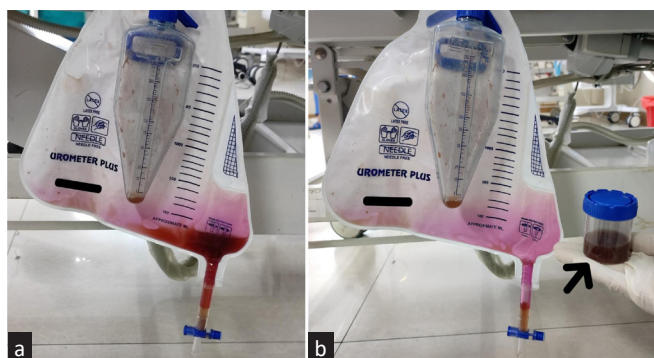
1. Nandwani A, Jha PK, Gadde A, Jain M. Purple urine bag syndrome. *Indian J Nephrol* 2022;32:646-7.
2. Sabanis N, Paschou E, Papanikolaou P, Zagkotsis G. Purple urine bag syndrome: more than eyes can see. *Curr Urol* 2019;13:125-32.
3. Oliveira Rodríguez M, Moreno Rodríguez M, Díaz Martín JJ, Prieto García B. Purple urine in Berdon syndrome: A rare finding in the clinic laboratory. *Ann Clin Biochem* 2023;60:142-5.

This is an open access journal, and articles are distributed under the terms of the Creative Commons Attribution-NonCommercial-ShareAlike 4.0 License, which allows others to remix, transform, and build upon the work non-commercially, as long as appropriate credit is given and the new creations are licensed under the identical terms.

**How to cite this article:** Rangaswamy DR, Mittal A, Kherra D. Purple Urine Bag in a Child. *Indian J Nephrol*. 2026;36:255. doi: 10.25259/IJN\_400\_2025

Received: 10-06-2025; Accepted: 17-06-2025;  
Online First: 18-07-2025; Published: 25-02-2026

DOI: 10.25259/IJN\_400\_2025



**Figure 1:** (a) Purple discoloration of the urine collection bag. (b) Urine is Cola-colored (black arrow), while the bag is stained purple.