

Both these diseases are mediated through the alternative complement pathway. aHUS is hypothesized to occur in persons with a genetic predisposition and subsequent activation of complement by a variety of causes, infection being a known trigger. Complement activation and endothelial injury could be the underlying mechanism for the deposition of fibrin in the renal microvasculature.<sup>1</sup>

The prognosis and outcome of IRGN in adults is guarded. Almost all the patients documented with aHUS with IRGN have recovered. The time taken for normalization of renal parameters ranged from 3 weeks to 1 year.<sup>1,3-5</sup> The limited data available suggest that long-term eculizumab therapy for this form of aHUS is not warranted.<sup>1</sup>



The identification of TMA was incidental in our cases, as there was no clinical suspicion during the initial presentation. The two cases illustrate that TMA may complicate IRGN in adults. Careful histologic evaluation is essential to recognize this rare complication obscured in the setting of IRGN.

#### Declaration of patient consent

The authors certify that they have obtained all appropriate patient consent.

#### Conflicts of interest

There are no conflicts of interest.

**CV Malathi<sup>1</sup> , Jansi Prema K.S<sup>1</sup>, Kishan Aralapuram<sup>2</sup> , Venkataramanan Krishnamoorthy<sup>3</sup>, Anila Abraham Kurien<sup>1</sup>**

<sup>1</sup>Department of Pathology, Renopath, Center for Renal and Urological Pathology, Chennai, Tamil Nadu, <sup>2</sup>Department of Nephrology, Institute of Nephro-Urology, Bangalore, Karnataka, <sup>3</sup>Department of Nephrology, KVR Kidney and Diabetic Center, Vellore, Tamil Nadu, India

#### Corresponding author:

Anila Abraham Kurien, Department of Pathology, Renopath, Center for Renal and Urological Pathology, Chennai, Tamil Nadu, India.  
E-mail: anila\_abraham08@yahoo.com

#### References

1. Kakajiwala A, Bhatti T, Kaplan BS, Ruebner RL, Copelovitch L. Post-streptococcal glomerulonephritis associated with atypical hemolytic uremic syndrome: To treat or not to treat with eculizumab? *Clin Kidney J* 2016;9:90–6.
2. Brocklebank V, Wood KM, Kavanagh D. Thrombotic microangiopathy and the kidney. *Clin J Am Soc Nephrol* 2018;13:300–17.
3. Siebels M, Andrassy K, Waldherr R, Ritz E. Hemolytic uremic syndrome complicating postinfectious glomerulonephritis in the adult. *Am J Kidney Dis* 1995;25:336–9.
4. Tan PH, Yadin O, Kleinman KS, Gura V, Cohen AH. Simultaneous postinfectious glomerulonephritis and thrombotic microangiopathy: A renal biopsy study. *Am J Kidney Dis* 1998;31:513–20.
5. Duvic C, Desramé J, Hérody M, Nédélec G. Acute poststreptococcal glomerulonephritis associated with thrombotic microangiopathy in an adult. *Clin Nephrol* 2000;54:169–73.

This is an open access journal, and articles are distributed under the terms of the Creative Commons Attribution-NonCommercial-ShareAlike 4.0 License, which allows others to remix, transform, and build upon the work non-commercially, as long as appropriate credit is given and the new creations are licensed under the identical terms.

**How to cite this article:** Malathi CV, Prema KS J, Aralapuram K, Krishnamoorthy V, Kurien AA. Rare Histologic Coexistence of Infection-Related Glomerulonephritis and Thrombotic Microangiopathy. *Indian J Nephrol*. 2025;35:109-10. doi: 10.25259/IJN\_304\_2024

Received: 13-06-2024; Accepted: 23-06-2024  
Online First: 29-08-2024; Published: 04-01-2025

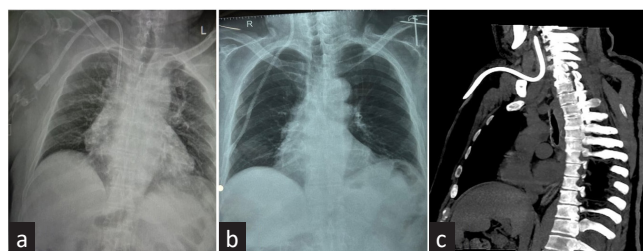
DOI: 10.25259/IJN\_304\_2024



## Spontaneous Intravascular Cephalad Migration of Tunneled Cuffed Catheter – An Unusual Late Complication and Role of Re-Imaging

Tunneled cuffed catheter (TCC) is an important mode of vascular access for hemodialysis (HD) and is notable for high success rate, safety and immediate usability for HD. Beside immediate complications of insertion like mispositioning, failure to function, hemothorax, pneumothorax, prolonged exit site bleeding, surgical site infections, cardiovascular arrhythmia and collapse, the commonly encountered delayed complications of TCC are: blockage, slippage, thrombosis, central venous stenosis, stuck catheter during removal, catheter exit-site and catheter-related blood stream infections.<sup>1,2</sup> It is unusual for catheter to migrate spontaneously late after insertion. A 71-year-old obese male with diagnosis of type 2 diabetes mellitus, hypertension, obstructive sleep apnea was initiated on HD with a TCC due to complications of end stage renal disease. Appropriate patient consent was obtained. TCC was inserted under real-time USG guidance with no procedure related complications, normal catheter position [Figure 1a] and adequate blood flow for dialysis

was achieved with normal inflow and outflow. The patient continued to receive twice-weekly HD until 5 weeks post insertion when outflow from the catheter ceased from both venous and arterial ports, but inflow was normal. A repeat X-ray and later a CT showed the catheter migrated upward



**Figure 1:** (a) Chest X ray showing normal position of TCC after insertion. (b) Chest X ray showing cephalad migrated TCC. (c) CT showing cephalad migration of TCC into IJV with tip lying at C2 vertebral level. TCC: Tunneled cuffed catheter, CT: Computerised tomography, IJV: Internal jugular vein, C2: Second cervical vertebra.

into IJV [Figure 1b-c]. The TCC was subsequently removed. Cephalad migration of catheter immediate post insertion has been reported earlier in the literature.<sup>3</sup> But delayed migration could be a rarity. Our current case highlights this rare occurrence of delayed cephalad migration of TCC and also the importance of the need of re-imaging whenever encountered with non/poorly functioning TCC.

### Conflicts of interest

There are no conflicts of interest.

**Ajay Jaryal<sup>1</sup>, Sanjay Vikrant<sup>2</sup>, Varun Bansal<sup>3</sup>, Akanksha<sup>2</sup>, Sajal Sharma<sup>2</sup>, Riya Aneja<sup>2</sup>**

Departments of <sup>1</sup>Medicine, <sup>2</sup>Nephrology, <sup>3</sup>Radiodiagnosis, AIIMS, Bilaspur, Himachal Pradesh, India

**Corresponding author:** Ajay Jaryal, Department of Medicine, AIIMS, Bilaspur, Himachal Pradesh, India. E-mail: drajayjaryal@gmail.com

### References

1. Jaryal A, Vikrant S, Singh R, Chauhan N, Sharma D, Kumar A. POS-578. Short term outcomes of tunneled cuffed catheters- A single center experience. *Kidney Int Rep* 2021;6:S254–5.
2. Jaryal A, Mahajan K, Vikrant S, Sharma D, Dhaulta P, Singh R. Removal of “stuck tunneled hemodialysis catheter” by hong’s technique: PUB152. *J Am Soc Nephrol* 2022;33:926.
3. Kumar A, Singh R. Cephalad migration of tunneled-cuffed catheter: The importance of post procedure imaging. *Kidney Dial* 2022;2:443–5.

This is an open access journal, and articles are distributed under the terms of the Creative Commons Attribution-NonCommercial-ShareAlike 4.0 License, which allows others to remix, transform, and build upon the work non-commercially, as long as appropriate credit is given and the new creations are licensed under the identical terms.

**How to cite this article:** Jaryal A, Vikrant S, Bansal V, Akanksha, Sharma S, Aneja R. Spontaneous Intravascular Cephalad Migration of Tunneled Cuffed Catheter – An Unusual Late Complication and Role of Re-Imaging. *Indian J Nephrol.* 2025;35:110-1. doi: 10.25259/IJN\_264\_2024

Received: 29-05-2024; Accepted: 01-06-2024

Online First: 22-08-2024; Published: 04-01-2025

DOI: 10.25259/IJN\_264\_2024

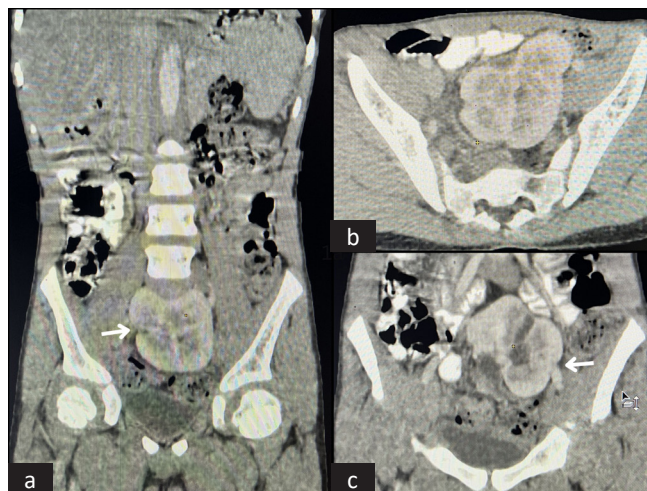


## Pancake Kidney: A Rare Case of Renal Ectopia

An 11-year-old male presented with a 1-month history of lower abdominal pain, accompanied by fever and burning micturition for the past 7 days. Abdominal examination was unremarkable, with no tenderness at the bilateral renal angles. Urine microscopy revealed pyuria, though kidney function tests and X-rays of the kidney, ureter, and bladder (KUB) were normal. Ultrasonography of the KUB region identified an abnormally located kidney in the pelvis. Computed tomography (CT) urography further revealed that both kidneys were fused in the pelvic cavity at the midline, with a single mega ureter on the left side, suggestive of a pancake kidney [Figure 1]. He was prescribed a course of antibiotics based on urine culture and sensitivity test results, which successfully relieved his symptoms.

Pancake kidney is an exceptionally rare form of fused renal ectopia. Looney and Dodd were the first to define and describe this condition.<sup>1</sup> It is characterized by a renal mass in the pelvis resulting from the complete medial fusion of the renal parenchyma without an intervening septum. Typically, each lobe has a separate pelvicalyceal system, but in our case, the kidneys had a single megaureter entering the bladder at the left vesicoureteral junction.

This anomaly can predispose to recurrent urinary tract infections and stone formation due to probable rotation anomalies of the collecting system and short ureters, which are prone to stasis and obstruction. Congenital renal malformations are often incidentally detected and



**Figure 1:** (a-b) Computed Tomography (CT) urography images showing (white arrow in a) the complete medial fusion of the renal parenchyma, located ectopically in the pelvic cavity at the midline. (c) CT urography image (white arrow) showing a single megaureter originating from the left side of the fused renal mass.

asymptomatic; in such cases, a conservative approach with long-term follow-up is recommended.<sup>2</sup>

### Declaration of patient consent

The authors certify that they have obtained all appropriate patient consent.

### Conflicts of interest

There are no conflicts of interest.